Koşuyolu Heart Journal

Koşuyolu Heart J 2026;29(3):188–195
DOI: 10.51645/khj.2026.635

Original Article

Anomalous Origin of the Left Coronary Artery from the Pulmonary Artery Beyond Infancy: Single-Center Experience of Clinical Spectrum and Surgical Outcomes

Betül Çınar,[1] Pelin Ayyıldız,[1] Sertaç Haydin,[2] Alper Güzeltaş[1]

[1]Department of Pediatric Cardiology, University of Health Sciences, Mehmet Akif Ersoy Thoracic and Cardiovascular Surgery Training and Research Hospital, İstanbul, Türkiye
[2]Department of Pediatric Cardiovascular Surgery, University of Health Sciences, Mehmet Akif Ersoy Thoracic and Cardiovascular Surgery Training and Research Hospital, İstanbul, Türkiye

Abstract

Objective: Anomalous origin of the left coronary artery from the pulmonary artery (ALCAPA) is a rare and life-threatening congenital anomaly. While it typically manifests during early infancy, some patients remain asymptomatic or present later in childhood and adolescence due to well-developed intercoronary collaterals. Therefore, the objective of this study was to evaluate the clinical spectrum, diagnostic features, and surgical outcomes of patients diagnosed with ALCAPA beyond infancy at our center.

Methods: A retrospective review was conducted on 35 patients diagnosed with ALCAPA who underwent surgical treatment at our center between January 2012 and January 2025. Out of this cohort, 8 patients diagnosed beyond infancy (older than 12 months) were enrolled in this study to evaluate their clinical spectrum and surgical revascularization outcomes.

Results: The age at diagnosis ranged from 2 to 21 years (median: 6.8 years), and all patients were female. Four patients (50%) were completely asymptomatic at presentation. Symptomatic presentations included exertional chest pain (n=1), recurrent vomiting and irritability (n=2), and sudden cardiac arrest with sustained ventricular arrhythmia (n=1). Electrocardiography (ECG) revealed characteristic ALCAPA patterns in 5 patients. Echocardiography demonstrated left ventricular (LV) and right coronary artery (RCA) dilation in all cases, with a mean RCA/aortic annulus ratio of 0.25. Baseline LV systolic dysfunction (ejection fraction: 30–45%) was observed in 4 patients. Surgical management consisted of direct coronary reimplantation (n=6) and the Takeuchi procedure (n=2). Mitral valve repair was performed in 2 patients with structural mitral anomalies. At a mean follow-up of 48 months, all patients were alive and asymptomatic, with full recovery of LV function and resolution of ECG abnormalities within 6–9 months postoperatively.

Conclusion: ALCAPA must be considered in the differential diagnosis of unexplained LV dilation or mitral regurgitation across all pediatric age groups. Extensive collateral circulation can mask typical features, leading to atypical presentations or misdiagnosis. Prompt establishment of a dual-coronary system provides a satisfactoryprognosis and facilitates complete myocardial recovery.

Keywords: ALCAPA; congenital heart disease; coronary reimplantation; myocardial recovery.

İnfant Dönemi Sonrası Tanı Alan ALCAPA: Klinik Yelpaze ve Cerrahi Sonuçlarda Tek Merkez Deneyimi

Özet

Amaç: Sol koroner arterin pulmoner arterden anormal çıkışı (ALCAPA), nadir görülen ve hayati tehlike oluşturan doğuştan bir anomalidir. Genellikle erken bebeklik döneminde belirti gösterse de, bazı hastalar iyi gelişmiş interkoroner kollateraller sayesinde asemptomatik kalabilmekte veya çocukluk ve ergenlik döneminde daha geç başvurabilmektedir. Bu çalışmanın amacı merkezimizde infant dönemi sonrasında ALCAPA tanısı alan hastaların klinik yelpazesini, tanısal özelliklerini ve cerrahi sonuçlarını değerlendirmekti.

Cite This Article: Çınar B, Ayyıldız P, Haydin S, Güzeltaş A. Anomalous Origin of the Left Coronary Artery from the Pulmonary Artery Beyond Infancy: Single-Center Experience of Clinical Spectrum and Surgical Outcomes. Koşuyolu Heart J 2026;29(3):188–195

Address for Correspondence:
Betül Çınar

Department of Pediatric Cardiology, University of Health Sciences, Mehmet Akif Ersoy Thoracic and Cardiovascular Surgery Training and Research Hospital, İstanbul, Türkiye

E-mail: cinar_betul@hotmail.com

Submitted: July 14, 2026
Revised: August 25, 2026
Accepted: September 10, 2026
Available Online: October 21, 2026

Copyright@Author(s) - Available online at kosuyoluheartjournal.com

OPEN ACCESS This work is licensed under a Creative Commons Attribution-ShareALike 4.0 International License.

Yöntem: Merkezimizde Ocak 2012 ile Ocak 2025 tarihleri arasında ALCAPA tanısı alan ve cerrahi tedavi uygulanan 35 hasta üzerinde geriye dönük inceleme yapılmıştır. Bu gruptan, klinik yelpazelerini ve cerrahi revaskülarizasyon sonuçlarını değerlendirmek amacıyla, infant dönemi sonrasında (12 aydan büyük) tanı konulan sekiz hasta bu çalışmaya dahil edilmiştir.

Bulgular: Tanı anındaki yaş 2 ile 21 yıl arasında değişmekte olup (medyan: 6,8 yıl) hastaların tamamı kadındı. Dört hasta (%50) başvuru sırasında tamamen asemptomatikti. Semptomatik başvurular arasında eforla gelen göğüs ağrısı (n=1), düşük kardiyak debiye sekonder tekrarlayan kusma ve huzursuzluk (n=2) ve ventriküler aritminin eşlik ettiği ani kardiyak arrest (n=1) yer almaktaydı. Elektrokardiyografi (EKG), beş hastada karakteristik ALCAPA paternlerini ortaya koydu. Ekokardiyografi, tüm olgularda sol ventrikül ve sağ koroner arter (RCA) dilatasyonunu gösterdi; ortalama RCA/aort anulus oranı 0,25 idi. Dört hastada başlangıç sol ventrikül sistolik disfonksiyonu (EF: %30–%45) gözlendi. Cerrahi yönetim, direkt koroner reimplantasyon (n=6) ve Takeuchi prosedüründen (n=2) oluşmaktaydı. Yapısal mitral anomalisi olan iki hastaya eş zamanlı mitral kapak tamiri uygulandı. Ortalama 48 aylık takip süresinde tüm hastalar hayattaydı ve asemptomatikti; postoperatif 6-9 ay içinde sol ventrikül fonksiyonlarında tam iyileşme ve EKG anomalilerinde düzelme görüldü.

Sonuç: ALCAPA, tüm çocukluk çağı yaş gruplarında nedeni açıklanamayan sol ventrikül dilatasyonu veya mitral yetersizliğin ayırıcı tanısında mutlaka akla gelmelidir. Yaygın kollateral dolaşım, tipik özellikleri maskeleyerek atipik klinik tablolara veya yanlış tanıya yol açabilir. Çift koronerli sistemin zaman kaybedilmeden kurulması, başarılı bir uzun vadeli prognoz sağlar ve tam miyokardiyal iyileşmeyi kolaylaştırır.

Anahtar sözcükler: ALCAPA; doğuştan kalp hastalığı; koroner reimplantasyon; miyokardiyal iyileşme.

Introduction

As the name implies, anomalous origin of the left coronary artery from the pulmonary artery (ALCAPA) is an uncommon but potentially fatal anomaly characterized by the left coronary artery arising from the pulmonary artery rather than the aortic root. Although rare, affecting approximately 1 in every 300,000 live births, due to ischemic heart disease and endocardial fibroelastosis (EFE), mortality rates may exceed 85% if undiagnosed within the 1st year of life.[1] The classic presentation occurs in the 1st or 2nd month of life when pulmonary artery pressure falls, triggering a "coronary steal phenomenon" from the coronary artery into the lower-pressure pulmonary artery. Nevertheless, some patients do not present with symptoms until later in life depending on pulmonary artery pressure and intercoronary collateral circulation. Consequently, two distinct clinical patterns of ALCAPA have been established: the infantile type, characterized by severe heart failure and early mortality, and the late-presenting type (beyond infancy), which manifests with a highly variable, chronic, and occasionally deceptive clinical spectrum. This study aims to evaluate the clinical spectrum, diagnostic pitfalls, and long-term surgical revascularization outcomes of a distinct cohort of patients diagnosed with ALCAPA beyond infancy.

Materials and Methods

Study Population and Method

A retrospective cohort study was conducted on a total population of 35 patients diagnosed with ALCAPA who underwent surgical correction and subsequent clinical follow-up at our center between January 2012 and January 2025. For the purpose of the present study, inclusion criteria were restricted to patients older than 12 months of age at the time of definitive diagnosis. Based on these criteria, 8 consecutive patients were enrolled.

Data Collection and Ethical Considerations

Medical records, electrocardiograms (ECGs), 24-h Holter ambulatory recordings, transthoracic echocardiography (ECHO) reports, conventional angiographies, and surgical data were systematically reviewed. Approval was obtained from the Mehmet Akif Ersoy Thoracic and Cardiovascular Surgery Training and Research Hospital Local Ethics Committee (Date: 06.07.2026, Decision no: 2026.07-108). The study was carried out in compliance with the principles of the Declaration of Helsinki, and written informed consent was waived due to retrospective nature of the study.

Statistical Analysis

Due to the small cohort size, statistical analysis was restricted to descriptive statistics. Continuous variables are expressed as mean or median values, while categorical variables are presented as frequencies and percentages.

Results

Age at Diagnosis and Symptomatology

The age at diagnosis ranged from 2 to 21 years (median: 6.8 years), and all patients were female. Four patients (50%) were asymptomatic whereas 1 had exertional chest pain, 2 presented with recurrent episodes of vomiting and irritability secondary to low-cardiac-output state, and another 1 had cardiac arrest with sustained ventricular arrhythmia. One patient, 9 years of age, was followed up in another center with the diagnosis of ventricular septal defect and dilated cardiomyopathy for many years. Another patient, 5 years, who had previously undergone mitral valve surgery at our center for significant mitral regurgitation (MR) secondary to a mitral valve anomaly and left-sided chamber dilation, was diagnosed in the post-operative period when clinical condition of the patient and left ventricular dilation failed to improve. Demographic and clinical outcome data are presented in Table 1.

Diagnostic Work Up

On physical examination, 4 patients had an elevated heart rate relative to their age group, 3 presented with a murmur associated with MR, and cardiomegaly was noted in 7 patients. Resting ECGs were normal in 3 patients, whereas changes attributable to ALCAPA (1 left bundle branch block pattern and diffuse ST segment depression in lateral precordial leads, 3 deep q waves in lead I and aVL and ST segment depression with T wave in-

Table 1. Demographic and clinical outcome data

Patient (#)	Age at diagnosis (years-months)	Gender	Presentation	Finding	ECG	ECHO*	Additional cardiac anomaly	Treatment	Mitral surgery	ECMO support needed	Last ECHO (follow-up time)
1	2 y	F	Asymptomatic/murmur	Elevated heart rate, MR murmur	Sinus tachycardia, T wave inversion and ST depression in V1-V6, Q wave in lead I and avL	LV dilation with systolic dysfunction (EF 45%) RCA dilation (z score:+2.6) Collaterals on IVS EFE (grade 2) MR (severe)	Mitral valve anomaly, Right aortic arch	Direct coronary reimplantation	+	-	LV EF >55% MR (moderate) (24 months)
2	2 y 2 m	F	Cardiac arrest	History of ventricular fibrillation, Elevated heart rate	Sinus tachycardia, LBBB, ST depression in V1-V6	LV dilation with systolic dysfunction (EF 30%) RCA dilation (z score:+5.5) Collaterals on IVS EFE (grade 1) MR (mild)	-	Direct coronary reimplantation	-	-	LV EF >55% MR (mild) (72 months)
3	2 y 8 m	F	Asymptomatic/murmur	MR murmur	Q wave in lead I and avL	LV dilation with preserved systolic function RCA dilation (z score:+3.6) Collaterals on IVS EFE (grade 2) MR (moderate)	Mitral valve prolapse	Direct coronary reimplantation	-	-	LV EF >55% MR (moderate) (27 months)
4	4 y 6 m	F	Nausea, vomiting	Elevated heart rate	Sinus tachycardia, T wave inversion and ST depression in V1-V6, Q wave in lead land avL	LV dilation with systolic dysfunction (EF 45%) RCA dilation (z score:+3.6) Collaterals on IVS EFE (grade 2) MR (moderate)	-	Direct coronary reimplantation	-	-	LV EF >55% MR (mild) (27 months)
5	4 y 8 m	F	Restlessness, vomiting	Elevated heart rate	Sinus tachycardia, T wave inversion and ST depression in V1-V6, Q wave in lead I and avL	LV dilation with systolic dysfunction (EF 35%) RCA dilation (z score:+2.6) Collaterals on IVS EFE (grade 3) MR (mild)	Mitral valve anomaly	Direct coronary reimplantation	-	-	LV EF >55% MR (mild) (48 months)
6	5 y	F	Asymptomatic/murmur	MR murmur	Normal	LV dilation with preserved systolic function RCA dilation (z score: +2.3) Collaterals on IVS MR (mild)	-	Direct coronary reimplantation	+	-	LV EF >55% MR (mild) (20 months)
7	9 y	F	Asymptomatic	Normal	Normal	LV dilation with preserved systolic function RCA dilation (z score: +5.2) Collaterals on IVS EFE (grade 1) MR (mild)	-	Takeuchi operation	-	+ (Postoperative 1–5 days)	LV EF >55% MR (mild) PS (bifurcation-moderate) (10 months)
8	21 y	F	Exertional chest pain	Normal	Normal	LV dilation with preserved systolic function RCA dilation (z score:+3.9) Collaterals on IVS MR (none)	Pulmonary stenosis (valvular, mild)	Takeuchi operation	-	-	LV EF >55% MR (none) PS (valvular,mild) (48 months)

ECG: Electrocardiogram; ECHO: Echocardiogram; ECMO: Extracorporeal membrane oxygenation; EF: Ejection fraction; EFE: Endocardial fibroelastosis; IVS: Interventricular septum; LBBB: Left bundle branch block; LMCA: Left main coronary artery; LV: Left ventricle; MR: Mitral regurgitation; PS: Pulmonary stenosis; RCA: Right coronary artery; Y: Year; M: Month; F: Female.ECG: Electrocardiogram, ECHO: Echocardiogram, ECMO: Extracorporeal membrane oxygenation, EF: Ejection fraction, EFE: Endocardial fibroelastosis, IVS: İnterventricular septum, LBBB: Left bundle branch block, LMCA: Left main coronary artery, LV: Left ventricle, MR: Mitral regurgitation, PS: Pulmonary stenosis, RCA: Right coronary artery, Y: Year, M: Month, F: Female. *Dallaire, Frédéric, and Nagib Dahdah. "New equations and a critical appraisal of coronary artery Z scores in healthy children." Journal of the American Society of echocardiography 24.1 (2011): 60-74.

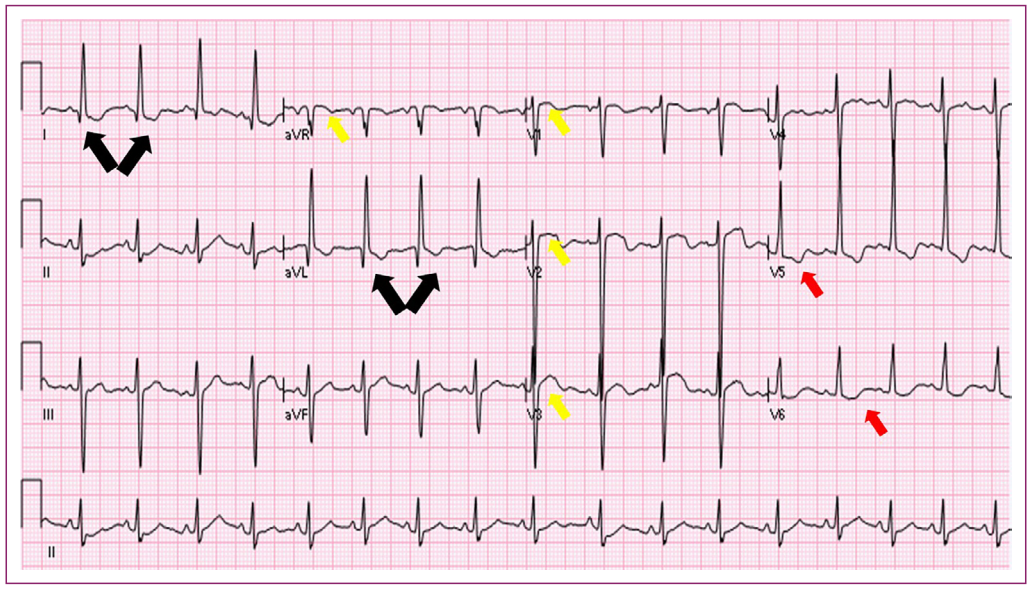

Figure 1. Electrocardiography: Pathological Q waves and ST segment depression (D1 and avL) (black arrows), ST segment depression and T wave inversion in lateral precordials (red arrows) and reciprocal changes in right oriented derivations (yellow arrows).

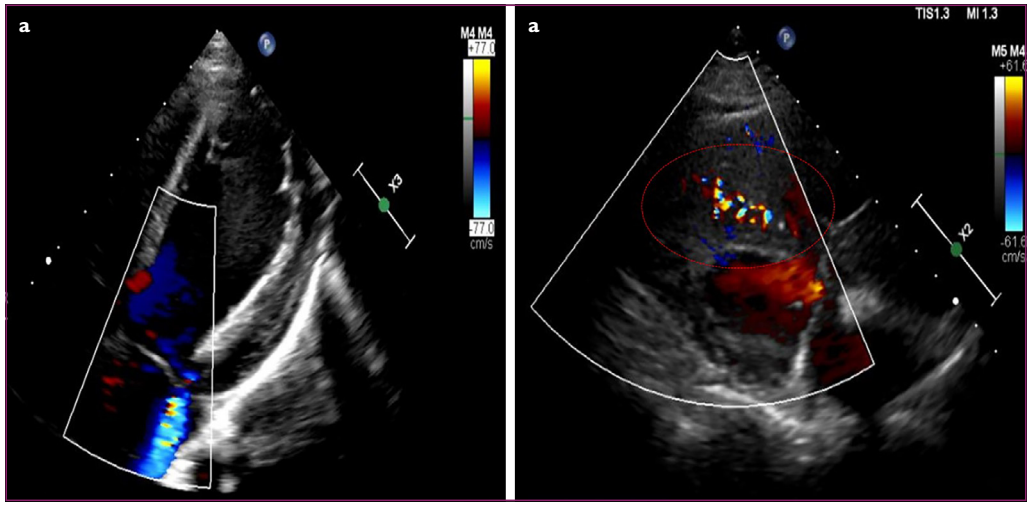

Figure 2. Echocardiography: Dilated left ventricle+ endocardial fibroelastosis overt in papillary muscle+ mitral regurgitation on modified apical 4 chamber view (a), color Doppler image of septal collaterals shown in modified parasternal long axis view (red dotted circle) (b).

version in lateral precordials, and 1 deep q waves in lead I and aVL) were seen in 5 patients (Fig. 1). Twenty-four-hour Holter monitoring, available in 4 patients, were free of arrhythmias.

The most common echocardiographic features were dilation of left ventricle (LV) and right coronary artery (RCA) which were depicted in all cases regardless of the age at diagnosis. The mean RCA/aortic annulus ratio was 0.25 (range: 0.21–0.3). Left ventricular systolic dysfunction was noted in 4 cases (ejection fraction [EF] range: 30–45%) at the initial echocardiography. In patients with impaired ventricular function, global EF reduction was observed rather than regional myocardial wall motion abnormalities corresponding to the left coronary artery territory. Collaterals in interventricular septum (IVS) were visible with color Doppler in all patients, EFE was present in 6 patients (grade 1 for 2, grade 2 for 3, grade 3 for 1 patient). MR was mild in 4, moderate in 2, and severe in 1 (Fig. 2). A patient with moderate regurgitation had innate prolapse of the mitral valve along with ALCAPA. Another concomitant cardiac lesion was mild valvular pulmonary stenosis in 1 patient who was 21 years old at the diagnosis and the eldest of the late presenters.

Echocardiography was used as the mainstay of the diagnostic pathway, after which selective coronary artery angiography was performed to confirm the diagnosis and to plan treatment options by assessing the distance of left main coronary artery (LMCA) origin to the aorta. Selective right coronary angiography demonstrated dilation of RCA in all patients and retrograde filling of the left coronary system by numerous collaterals feeding from RCA (Fig. 3). Regarding advanced diagnostic modalities,

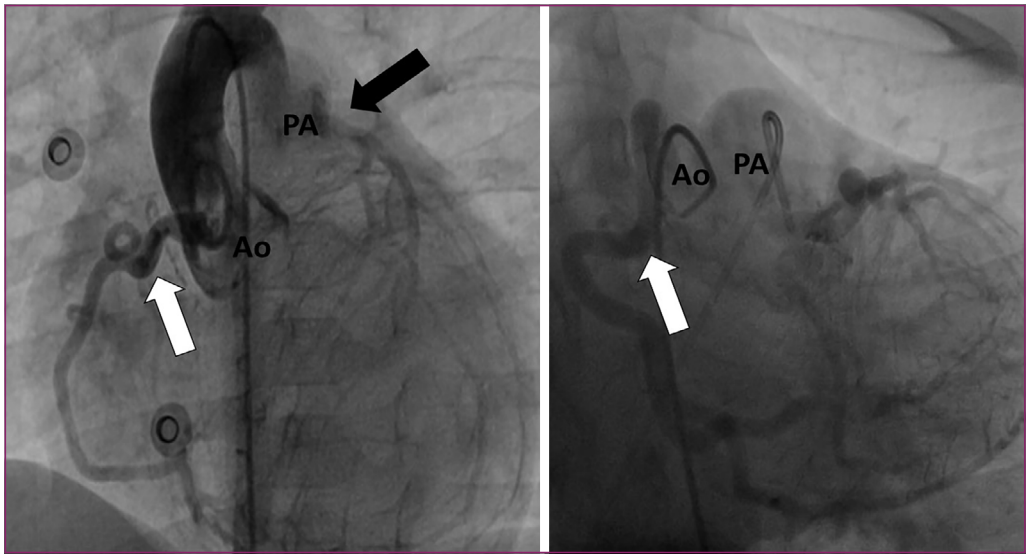

Figure 3. Coronary angiography: Aortic root injection shows dilated RCA and retrograde filling of left main coronary artery branches and pulmonary artery sequentially (LMCA and its anormalous origin is shown with black arrow, dilated RCA is shown with white arrow in both images), selective coronary angiographies showed no antegrade filling of left coronary system from aorta, right coronary artery is dilated and left system is filled via numerous collateral arteries.

Ao: Aorta; PA: Pulmonary artery.

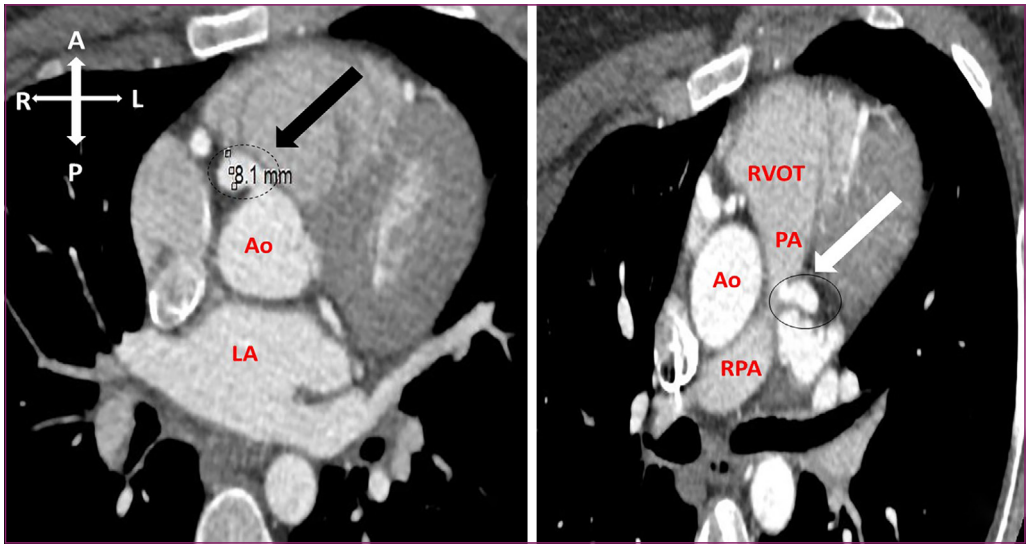

Figure 4. Computed tomography: Dilated proximal segment of right coronary artery (dotted circle and tipped by black arrow) (a), origin of left main coronary artery from left margin of pulmonary artery (dotted circle and tipped by white arrow).

Ao: Aorta; LA: Left atrium; PA: Pulmonary artery; RPA: Right pulmonary artery; RVOT: Right ventricular outflow tract.

we highlight a female patient who presented to the adult cardiology clinic with chest pain and was referred to our department following an unexpected diagnosis of ALCAPA through coronary computed tomography (CT) angiography (Fig. 4).

Treatment Strategy

Angiographic images and intraoperative findings were evaluated to decide on the most appropriate surgical technique. Direct coronary reimplantation was performed in 6 patients, whereas Takeuchi procedure (intrapulmonary tunnel from pulmonary artery to aorta) was the preferred technique in the remaining 2. One patient with a pre-operative preserved LV function required extracorporeal membrane oxygenation (ECMO) support 6 hours after surgery for 5 days due to biventricular dysfunction after Takeuchi repair. Two patients had mitral valve repair; ALCAPA was diagnosed subsequently in 1 patient who initially underwent mitral valve repair with a preliminary diagnosis of primary MR attributed to a structural mitral valve abnormality and the other patient underwent concomitant mitral valve repair for a structural anomaly during the ALCAPA surgery. All patients are alive and asymptomatic after a mean of 48 months follow-up. Remarkably, the abnormal Q waves with T wave in-

Table 2. Spectrum of signs and symptoms relative to the age of diagnosis with our comparable data provided

	Time of diagnosis		Our data (n, %)
	Infancy	Beyond ınfancy	
Symptoms/presentation	Irritability (crying, colicky like episodes especially after feeding), sweating, poor feeding/weight gain, shortness of breath, wheezing, and vomiting	Asymptomatic to sudden cardiac arrest due to life-threatening ventricular arrhythmias, chest pain, palpitations	Asymptomatic (4, 50%) Exertional chest pain (1, 13%) Low cardiac output state (2, 25%) Cardiac arrest (1, 13%)
Physical examination	Pallor, tachycardia, S3 gallop, and murmur (if concomitant mitral regurgitation)	Normal, tachycardia, S3 gallop, murmur (if concomitant mitral regurgitation)	Normal (2, 25%), tachycardia (4, 50%), murmur (3, 38%), and
Changes in			
ECG	Pathological Q waves* in leadI, aVL, and V4-V6,T wave negativity in precordial leads and ST changes	Can be entirely normal depending on the extent of collaterals, atrial and ventricular arrhythmias, infancy period changes may also be encountered	Normal (3, 38%) Consistent with ALCAPA (5, 62%)
Chest X-ray	Cardiomegaly	Can be normal	Cardiomegaly (7, 88%)
Echocardiography	LV dilation with impaired systolic function, mitral regurgitation (functionally/structurally), endocardial fibroelastosis, anterior and lateral wall hypokinesis, right coronary artery dilation, retrograde filling of left main coronary from pulmonary artery, and color Doppler images of collaterals on interventricular septum	Expected to commonly have right coronary artery dilation, collaterals on interventricular septum, systolic function of LV may be preserved and LV dilation may be mild or absent.	LV dilation (8, 100%) RCA dilation (8, 100%) Collaterals on septum (8, 100%) Endocardial fibroelastosis (6, 75%) Mitral regurgitation (7, 88%) (4 mild, 2 moderate, 1 severe) Systolic dysfunction (4, 50%) Primary mitral anomaly (3, 38%) Pulmonary stenosis (1, 13%)
Choice of treatment	Surgical	Surgical	Direct coronary reimplantation (6, 75%) Takeuchi operation (2, 25%)
Natural outcome without intervention	Death in the 1st year of life	May even survive up to late adulthood	

ALCAPA: Anomalous left coronary artery from the pulmonary artery; LV: Left ventricle; RCA: Right coronary artery. *Q wave >0.3 mv (3 mm) and duration longer than 30 ms (Hoffman JI. Electrocardiogram of anomalous left coronary artery from the pulmonary artery in infants. Pediatr Cardiol. 2013 Mar;34(3):489-91. doi: 10.1007/s00246-012-0599-7. Epub 2012 Dec 15. PMID: 23242106).

version on ECG and LV dysfunction recovered fully within 6–9 months after surgical repair in affected patients. Mitral regurgitation status of the patients at last follow-up demonstrated an improvement in two patients compared to baseline, with the rest remaining stable. None of our patients had arrhythmic event or needed coronary artery or mitral valve reintervention.

Discussion

The primary pathophysiological mechanism driving the clinical presentation in ALCAPA is the postnatal reduction in pulmonary vascular resistance, which causes a reversal of blood flow from the left coronary system into the pulmonary artery. This retrograde flow induces myocardial ischemia, meaning that survival beyond infancy is strictly dictated by the establishment of robust collateral circulation from the RCA. Once this circulatory network is achieved, the patient presents much later in life which makes recognition of this rare condition even more strenuous. Differences between infant and late presenters of ALCAPA are summarized in Table 2 for practical use.

Echocardiography is a highly important tool in the diagnostic process, to search for indirect findings such as dilation in the coronary arteries, or increased collaterals in the ventricular septum along with LV enlargement as seen in our patients. As our previously published data suggest, the direct visualization of coronary origins from the aorta in the initial ECHO can be misleading in approximately 40% of cases, and the diagnosis of dilated cardiomyopathy may be erroneously assigned to patients if secondary findings are not investigated.[2] **Therefore, noticing "LV and RCA dilation" and collaterals on IVS with color Doppler images in low scales, which were present in nearly all of our cases, is of great importance**. As late presenters expected to have plenty of collaterals, this may be confused with ventricular septal defect as happened in 1 of our patients who were followed up since 6 months of age with misdiagnosis of multiple ventricular septal defects and LV enlargement attributed to it. Mitral regurgitation associated with ALCAPA is a critical consideration which requires thorough evaluation, as its etiology whether secondary to annular dilation or an intrinsic congenital anomaly plays a crucial role in the decision-making process for mitral valve intervention. Misdiagnosis as "isolated mitral regurgitation" that underwent mitral valvuloplasty or replacement, can be seen in medical history of patients who were diagnosed as ALCAPA later in life.[3] As observed in a patient from our cohort, the absence of fibroelastosis and typical ECG findings, along with preserved systolic function, led to a delayed diagnosis of ALCAPA. This case perfectly illustrates the importance of maintaining a high index of suspicion for concurrent coronary anomalies in patients presenting with mitral valve

anomalies. Data extracted from ALCAPA cases in adult practice demonstrate that CT imaging and coronary cardiac catheterization are prominently utilized for diagnosis.[4] However, considering the anesthesia requirement and radiation burden in the pediatric population, familiarity with the echocardiographic clues of ALCAPA is of paramount importance, and its routine application would be highly recommended, especially in patients older than 1 year presenting with LV dilation. With the goal of raising awareness through our contribution to the literature, **summary of echocardiographic findings that should prompt suspicion of ALCAPA along with LV dilation include: dilation of RCA, increased ratio of the diameter of RCA to the aortic annulus (>0.14), increased echogenicity of the papillary muscles and/or mitral valve abnormalities, increased flow toward the pulmonary artery, collaterals on IVS with color Doppler images, and either identification of an inappropriate origin of the anomalous coronary artery from the pulmonary artery or non-identification of the origin of the coronary artery**. However, it is crucial to keep in mind that the apparent visualization of the left coronary artery origin from the aorta should not rule out ALCAPA, and relying on the aforementioned secondary echocardiographic findings is highly warranted for an accurate diagnosis.

Another important aspect is, as this pathology is a coronary abnormality in nature, initial pattern of presentation may be a life-threatening ventricular arrhythmia without overt LV enlargement and MR.[5] Although LV dilation and impaired function were important clues for the diagnosis, one of our patients presented with ventricular fibrillation. Therefore, ALCAPA should be kept in mind during etiological work up for malign arrhythmias regardless of age.

Due to numerous intercoronary collaterals, changes in chest X-ray and ECG may be subtle or absent which makes echocardiography the best primary diagnostic tool. Once suspected, especially for infant patients, institutionally we confirm the diagnosis with selective coronary angiography and define the distance between pulmonary origin and aorta to assist surgeons in pre-operative planning. Late presenters with appropriate heart rates may undergo coronary imaging with CT or cardiac magnetic resonance imaging to prevent complications of conventional angiography. Even though survival without surgical correction in patients against surgery is published in adult case reports, the American Heart Association and American College of Cardiology joint recommendations state that ALCAPA patients who present at adult ages should undergo surgical repair regardless of myocardial contractility.[6] The most commonly preferred surgical technique is reimplantation of the anomalous coronary into the aortic root. Depending on the coronary and great vessels relation, different options such as creation of an intrapulmonary tunnel through either autologous or prosthetic material to the aortic sinus (Takeuchi procedure), and ligation of the anomalous artery combined with vessel grafting can be performed. In our series, 2 patients required a Takeuchi repair because the remote location of the LMCA from the aortic root precluded direct coronary reimplantation. The 21-year-old patient demonstrated excellent mid-term results without baffle-related complications or re-intervention over 48 months of follow-up. The second patient, who had an LMCA arising from the non-facing pulmonary sinus, experienced early post-operative biventricular dysfunction and transient ECMO dependency likely secondary to intraoperative myocardial injury and subsequent edema but eventually achieved full myocardial recovery. During long-term surveillance, both patients remained asymptomatic with preserved ventricular function and patency of the intra-aortic baffle.

Another surgical concern is concomitant MR which remains an area of debate because the majority of MR is functional with a structurally normal mitral valve. Threshold for intervention varies widely among institutions. Zhang et al.[7] performed mitral repair in late presented ALCAPA patients with moderate-to-severe regurgitation and claimed concomitant mitral intervention is usually considered in patients with moderate or severe MR as it does not affect early mortality, though cross clamp time was longer in repaired group. Birmingham team from the UK suggested that concomitant mitral repair should be reserved for structurally abnormal valves rather than functionally abnormal valves due to LV dilation.[8] Among their 14 patients with pre-operative moderate to severe MR with functionally regurgitant valves, only one had moderate regurgitation at last follow-up without mitral valve surgery. We also support that structural assessment of the valve before any intervention by echocardiography is crucial and surgical valve repair should be performed in individuals who were expected to have significant residual regurgitation even after LV dilation has resolved.

The post-operative course in this patient cohort is generally favorable, characterized by the restoration of ventricular systolic function and the normalization of electrocardiographic findings. Kwiatkowski et al.[3] reported 90% recovery of ventricular function within 3 years after surgical repair in their patients diagnosed after 1 year of age and presented with at least moderate left ventricular dysfunction. Literature also supports recoverability in older patients which is important to prove that delayed presentation is not an indicator of unrecoverable myocardium.[3] Improvement after surgery also had been promising in our cases with moderately impaired systolic function within 6–9 months. At a mean follow-up of 48 months, post-operative ECG abnormalities resolved, and LV function and dimensions normalized with stable MR. No coronary or mitral valve reinterventions were required.

Our study offers a valuable series of late-diagnosed cases, a population otherwise limited to isolated case reports in the literature. Although the inclusion of a 21-year-old patient prevents defining the cohort as strictly pediatric, the series remains exceptionally representative of this rare pediatric subset. This substantial cohort not only enriches the existing literature on late-presenting pediatric ALCAPA but also underscores the clinical diversity and diagnostic challenges associated with this anomaly beyond infancy.

Compared to the infantile presentation, older patients with ALCAPA may remain asymptomatic or present with preserved ventricular function at the time of initial diagnosis.[9] Prompt surgical intervention aiming to establish a dual-coronary system is highly recommended following diagnosis to optimize clinical outcomes.

Limitations

Several limitations must be acknowledged, chiefly the retrospective nature of the study and the small patient cohort. Given that ALCAPA syndrome is already a rare congenital anomaly, focusing strictly on patients with a delayed diagnosis further constrained our sample size. While this specific focus may limit the broader generalizability of the data, the findings offer highly specialized and valuable clinical insights into this distinct subpopulation.

Conclusion

Diagnosis of ALCAPA should be considered in all patients with the LV dilation and/or MR regardless of age. Clinical spectrum is mostly dependent on intercoronary collaterals and may be diverse from asymptomatic to sudden cardiac arrest with preserved ventricular function. Dilated RCA and collaterals on IVS in color Doppler scan must raise high suspicion. Awareness of the condition with immediate surgical intervention is essential to provide improved prognosis for these children or possibly adults.

Disclosures

Ethics Committee Approval: The study was approved by the Mehmet Akif Ersoy Thoracic and Cardiovascular Surgery Training and Research Hospital Local Ethics Committee (no: 2026.07-108, date: 06/07/2026).

Informed Consent: Written informed consent was waived due to retrospective nature of the study.

Conflict of Interest Statement: None declared.

Funding: The author declared that this study has received no financial support.

Use of AI for Writing Assistance: None declared.

Author Contributions: Concept – A.G., P.A.; Design – B.Ç., A.G., P.A.; Supervision – P.A., A.G., S.H.; Resource – A.G., S.H.; Materials – B.Ç., P.A.; Data collection and/or processing – B.Ç., P.A.; Data analysis and/or interpretation – P.A., A.G.; Literature search – B.Ç., P.A.; Writing – B.Ç.; Critical review – A.G., S.H.

Peer-review: Externally peer-reviewed.

References

1. Shriki JE, Shinbane JS, Rashid MA, Hindoyan A, Withey JG, DeFrance JA, et al. Identifying, characterizing, and classifying congenital anomalies of the coronary arteries. Radiographics 2012;32:453–68.
2. Guzeltas A, Ozturk E, Tanidir IC, Kasar T, Haydin S. Evaluation of Anomalous Coronary Arteries from the Pulmonary Artery. Braz J Cardiovasc Surg 2017;32:29–37.
3. Kwiatkowski DM, Mastropietro CW, Cashen K, Agrawal R, Attard TM, Borasino S, et al. Characteristics and surgical outcomes of patients with late presentation of anomalous left coronary artery from the pulmonary artery: a multicenter study. Semin Thorac Cardiovasc Surg 2021;33:141–50.
4. Spiljak A. Anomalous Origin of the Left Coronary Artery from the Pulmonary Artery Syndrome in Adults: A Case-Based Clinical Review. Turk Kardiyol Dern Ars. 2025;53:607–14.
5. Talebian Yazdi M, Robbers-Visser D, Van der Bilt I, Heuts S, Alizadeh Dehnavi R, Kiès P, et al. Anomalous coronary artery from the pulmonary artery diagnosed in adulthood: a case series on variations of coronary anatomy and the diagnostic value of cardiac magnetic resonance imaging. Eur Heart J Case Rep 2022;6:ytac345.
6. Warnes CA, Williams RG, Bashore TM, Child JS, Connolly HM, Dearani JA, et al. ACC/AHA 2008 guidelines for the management of adults with congenital heart disease: a report of the American College of Cardiology/American Heart Association task force on practice guidelines. J Am Coll Cardiol 2008;52:e143–e263.
7. Zhang W, Hu R, Zhu Y, Xu Z, Meng B, Liu J, et al. Surgical outcomes for anomalous left coronary artery from the pulmonary artery: influence of late presentation. J Thorac Cardiovasc Surg 2020;159:1945–52.
8. Kudumula V, Mehta C, Stumper O, Desai T, Chikermane A, Miller P, et al. Twenty-year outcome of anomalous origin of left coronary artery from pulmonary artery: management of mitral regurgitation. Ann Thorac Surg 2014;97:938–44.
9. Laflamme E, Alonso-Gonzalez R, Roche SL, Grewal J, Wald RM, Abrahamyan L, et al. Anomalous origin of a coronary artery from the pulmonary artery presenting in adulthood: experience from a tertiary center. Int J Cardiol Congenit Heart Dis 2021;4:100169.