



Takotsubo Syndrome Presenting with Syncope and Third-Degree Atrioventricular Block Requiring Permanent Pacemaker Implantation

Şeymus Külahçoğlu (ID), Zeynep Esra Güner (ID), Barkın Kültürsay (ID), Mehmet Aytürk (ID), Ayhan Küp (ID), Abdülkadir Uslu (ID)

Clinic of Cardiology, Koşuyolu High Specialization Training and Research Hospital, İstanbul, Turkey

ABSTRACT

Takotsubo syndrome (TS) is an acute but transient heart failure syndrome and it is very uncommon for TS to present with syncope and complete atrioventricular (AV) block. In this report, we discuss a case of TS complicated by a third-degree AV block presented to the emergency department with syncope and requiring permanent pacemaker implantation. A 53-year-old female was admitted to our emergency department with complaints of syncopal episodes and chest pain. Due to ongoing chest pain, electrocardiography (ECG) findings and segmentary wall motion abnormality on the transthoracic echocardiography (TTE), she was immediately transferred to the cardiac catheterization laboratory. Coronary angiogram revealed normal coronary arteries and left ventriculography demonstrated apical ballooning and hypokinesis of the apex. Once the diagnosis of TS was established, the patient was transferred to the coronary intensive care unit (CICU). Initial ECG at CICU demonstrated complete AV block with a heart rate of 35 beats/min. On the third day of hospitalization, repeat TTE showed improved left ventricular functions with an ejection fraction of 50%. During the follow-up period in CICU, complete AV block persisted and the rhythm did not return to normal sinus rhythm after six days of monitorization. An electrophysiological study demonstrated supra-hisian atrioventricular block and atrioventricular dissociation. On the seventh day of hospitalization, TTE demonstrated recovered ventricular functions with an ejection fraction of 65%, and a dual pacemaker was then implanted. Her third-month follow-up was uneventful and TTE showed normal left ventricular functions but pacemaker interrogation revealed 99% of ventricular pacing. This case report demonstrated that the decision to implant a permanent pacemaker in such patients should be considered on a case-by-case basis, and an electrophysiological study could be valuable on this decision.

Key Words: Cardiomyopathy; syncope; atrioventricular block; cardiac pacemaker; electrophysiology

Kalıcı Kalp Pili İmplantasyonu Gerektiren Senkop ve Atrioventriküler Tam Blok ile Başvuran Takotsubo Sendromu

ÖZET

Takotsubo sendromu (TS), akut ancak geçici bir kalp yetmezliği sendromu olup TS'nin atrioventriküler (AV) tam blok ve senkop olarak prezente olması çok nadirdir. Bu yazıda acil servise senkop ile başvuran ve kalıcı kalp pili takılması gereken, üçüncü derece AV blok ile komplike olan TS olgusunu sunmayı amaçladık. Elli üç yaşında kadın hasta senkop atakları ve göğüs ağrısı şikayetiyle acil servisimize başvurdu. Göğüs ağrısının devam etmesi, elektrokardiyografide (EKG) iskemi bulgularının olması ve transtorasik ekokardiyografide (TTE) segmenter duvar hareket kusuru bulunması nedeniyle hasta acil olarak kardiyak kateterizasyon laboratuvarına alındı. Koroner anjiyografide koroner arterler normal olarak değerlendirildi ve sol ventrikülografide apekte apikal balonlaşma ile birlikte hipokinezi gösterildi. Hastaya TS tanısı konulduktan sonra, hasta koroner yoğun bakım ünitesine (KYBÜ) transfer edildi. KYBÜ'deki ilk EKG'de kalp hızı 35 atım/dk olan AV tam blok saptandı. Hastanın yatışının üçüncü gününde kontrol TTE, sol ventrikül ejeksiyon fraksiyonunun %50'ye yükseldiğini gösterdi. KYBÜ'deki takip süresi boyunca AV tam blok devam etti ve altı günlük monitörizasyondan sonra ritim normal sinüse dönmedi. Elektrofizyolojik çalışma supra-hisian AV blok ve AV disosiasyonu gösterdi. Yatışın yedinci gününde TTE'de, sol ventrikül ejeksiyon fraksiyonunun %65'e yükselerek normal olduğu izlendi, ardından hastaya çift odacıklı kalp pili implante edildi. Üç aylık takip boyunca hastada herhangi bir olay izlenmedi, sol ventrikül fonksiyonları normaldi ancak kalp pili kontrolünde ventriküler pace oranı %99 olarak izlendi. Biz bu vaka ile diyebiliriz ki; bu gibi hastalarda kalıcı kalp pili implantasyon vaka bazı değerlendirilmeli ve bu karar aşamasında elektrofizyolojik çalışmaya başvurmak gerekebilir.

Anahtar Kelimeler: Kardiyomiyopati; senkop; atrioventriküler blok; kalp pili; elektrofizyoloji

Cite this article as: Külahçoğlu Ş, Güner ZE, Kültürsay B, Aytürk M, Küp A, Uslu A. Takotsubo syndrome presenting with syncope and third-degree atrioventricular block requiring permanent pacemaker implantation. *Koşuyolu Heart J* 2022;25(1):111-4.

Correspondence

Barkın Kültürsay

E-mail: bkultursay@gmail.com

Submitted: 08.08.2021

Accepted: 19.10.2021

Available Online Date: 15.04.2022

© Copyright 2022 by Koşuyolu Heart Journal. Available on-line at www.kosuyoluheartjournal.com

INTRODUCTION

Takotsubo syndrome (TS), also known as broken heart syndrome or neurogenic stunned myocardium, is an acute cardiac disease that mimics acute coronary syndrome and is characterized by systolic dysfunction of the apical and/or mid-segments of the heart in the absence of significant coronary artery disease⁽¹⁾. The syndrome predominantly affects postmenopausal women and is preceded by a trigger factor in about 70% of patients. Emotional triggers such as the death of a close relative or acute grief may trigger the syndrome, hence the term broken heart syndrome⁽²⁾. The pathogenesis of TS is elusive and several pathophysiological mechanisms for the development of TS have been proposed. The main proposed mechanisms are myocardial ischemia, left ventricular outlet tract obstruction, blood-borne catecholamine myocardial toxicity, epinephrine-induced switch in signal trafficking, and autonomic nervous system dysfunction with sympathetic nervous system hyperactivation including local cardiac sympathetic disruption and norepinephrine seethe and spillover⁽³⁾. The syndrome is usually reversible; nevertheless, during the acute stage, a substantial number of patients develop severe complications such as arrhythmias, heart failure, and cardiac arrest. Contrary to the reversible, transient pathophysiology of TS alone, some cases of arrhythmia-complicated TS developed into more life-threatening conditions, such as intermittent asystole or sudden cardiac death⁽⁴⁾. In this report, we aimed to present a case of TS complicated by third-degree AV block presented to the emergency department with a syncopal episode and chest pain, and requiring permanent pacemaker implantation.

CASE REPORT

A 53-year-old female without any known chronic diseases was admitted to our emergency department with a syncopal episode and chest pain. She stated that her symptoms commenced after having lost her mother a day ago. On her physical examination, no significant finding was present, her blood pressure was 165/72 mmHg and her heart rate was 55 beats/min. An initial electrocardiogram (ECG) revealed normal sinus rhythm with ST-segment changes and T wave inversions in V1-V3 derivations (Figure 1A). The transthoracic echocardiography (TTE) performed in the emergency department showed akinesis of the apical segments of the left ventricle and hyperkinesis of the basal segments with an ejection fraction of 35% (Figure 1B). Due to ongoing chest pain, ECG findings, and segmentary wall motion abnormality on TTE, she was immediately transferred to the cardiac catheterization laboratory. A coronary angiogram revealed normal coronary arteries and left ventriculography demonstrated apical ballooning and hypokinesis of the apex (Figures 1C and 1D). Once the diagnosis of Takotsubo syndrome (TS) was established, the patient was transferred to the coronary intensive care unit (CICU). The initial ECG at

CICU demonstrated a complete AV block with a heart rate of 35 beats/min (Figure 2A). No temporary pacing was needed as the patient was hemodynamically stable. On day three, the repeat TTE showed mild hypokinesis of the apex of the left ventricle and an ejection fraction of 50% (Figure 2B). During the follow-up period in CICU, complete AV block persisted and the rhythm did not return to normal sinus rhythm after six days of monitorization. The electrophysiological study demonstrated supra-hisian atrioventricular block and atrioventricular dissociation. On day seven, the TTE demonstrated recovered ventricular functions with an ejection fraction of 65%, and a dual pacemaker was then implanted. She was discharged on day eight without any adverse events. Her third-month follow-up was uneventful and the TTE showed normal left ventricular functions, but pacemaker interrogation revealed 99% of ventricular pacing.

DISCUSSION

TS was first described in 1990 as an acute but transient heart failure syndrome in the absence of coronary artery stenosis. The definitive etiology is unclear, but emotional or physical stress precedes TS due to a catecholaminergic surge⁽¹⁾. Takotsubo cardiomyopathy is usually considered to have a relatively good prognosis and rarely causes sudden death, congestive heart failure, or fatal arrhythmias⁽⁵⁾. Various types of arrhythmias can complicate the acute phase of TS, such as ventricular tachycardia, ventricular fibrillation, Torsades de pointes, atrial fibrillation, sinus node dysfunction, and AV block. It is very uncommon for TS to present as syncope with a complete AV block.

The occurrence of AV block is rarely associated with TS, with a prevalence of about 2.9%⁽⁴⁾. In our patient presenting with syncope, the initial ECG demonstrated normal sinus rhythm and we were not able to document AV block at admission, but the patient later developed third-degree AV block. Due to the reversible nature of this disease and our patient being hemodynamically stable, we did not implant a transvenous temporary pacemaker. It is suggested that diffuse spasms in small branches of the coronary arteries may be responsible for atrioventricular conduction disturbances⁽⁶⁾. It is also important to note that many cases of AV block associated with TS do not restore normal AV nodal function even after recovery of ventricular functions and thereby require permanent pacemaker implantation⁽⁶⁾. In an electrophysiological study by Nault et al., the lack of resolution of a high-degree AV block one year after TS was demonstrated and eventually resolved two years later⁽⁷⁾. More interestingly, even temporary or permanent pacemaker implantation due to previous AV block history can be a trigger of TS itself, creating a paradoxical causality⁽⁸⁾. Thus, it remains unknown whether TS causes AV block or AV node dysfunction as complications, or conversely, whether AV block as a physical stressor causes TS.

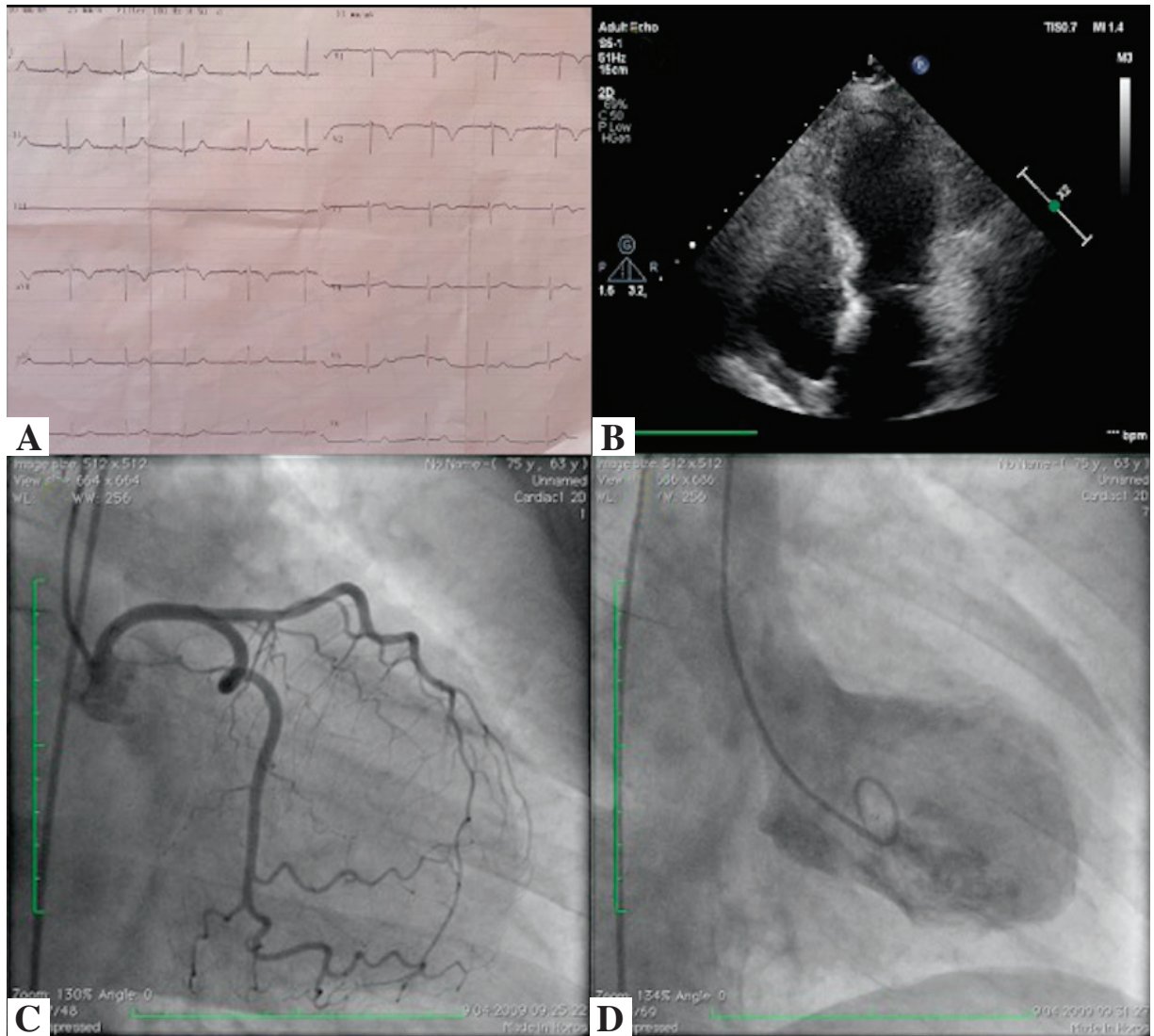


Figure 1. (A). Initial ECG in emergency department demonstrating normal sinus rhythm with ST-segment changes and T wave inversions in V1-V3 derivations. (B). TTE performed in emergency department showing akinesis of the apical segments of the left ventricle and hyperkinesis of the basal segments with and ejection fraction of 35%. (C). Coronary angiogram revealed normal coronary arteries and (D), left ventriculography demonstrated apical ballooning and hypokinesis of the apex.

ECG: Electrocardiogram; TTE: Transthoracic echocardiography.

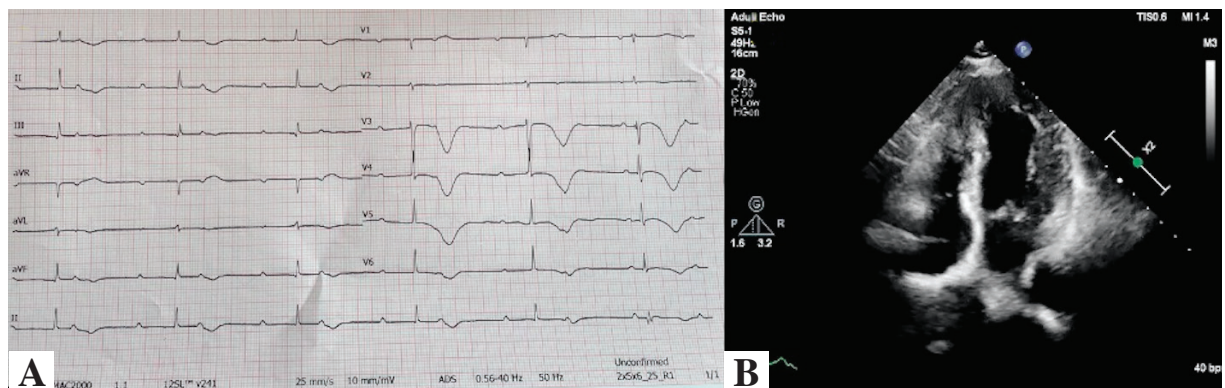


Figure 2. (A). Initial ECG in CICU demonstrated complete AV block with a heart rate of 35 beats/min. (B). Repeat TTE on day three showing mild hypokinesis of the apex of the left ventricle and an ejection fraction of 50%.

CICU: Coronary intensive care unit; ECG: Electrocardiogram; TTE: Transthoracic echocardiography.

Therefore, AV block as a presentation of TS poses a therapeutic predicament with regard to timing and the need to place a temporary or permanent pacemaker. As our patient was 53 years old, had an emotional stressor, and did not have a cardiac history, degenerative atrioventricular conduction abnormality was unlikely. Moreover, because the patient did not have any reversible etiology of AV conduction disturbance, the electrophysiological test demonstrated supra-hisian conduction abnormality, and the AV block persisted after recovery of ventricular functions, we decided to implant a permanent pacemaker.

The appropriate timing of pacemaker implantation for TS cases complicated by AV block remains unclear. Furthermore, determining the optimal device selection biventricular vs. dual pacemaker, or implantable cardioverter-defibrillator (ICD) is fundamental. The decision to implant a permanent pacemaker should be considered on a case-by-case basis, given the scarcity of literature. As TS is a transient heart failure syndrome and left ventricular functions recover in most cases, implantation of an ICD could be a valuable option only for those presenting with cardiopulmonary arrest and/or ventricular arrhythmias⁽⁵⁾. For patients presenting with first-degree or Mobitz type I or II AV block, watchful waiting and Holter or loop recording after discharge could be suitable. In a review by McGee et al., 24 cases of complete AV block complicating TS were identified. In four of the cases, a pacemaker was not implanted due to the resolution of the heart block. In a further two cases, the AV block was resolved post-implantation of the pacemaker⁽⁹⁾. This brief review indicated that most of the TS cases complicated by complete AV block required permanent pacemaker implantation, and those patients' AV block did not resolve on follow-up after the implantation. Moreover, in patients with complete heart block and who do not have fully recovered left ventricular functions after the acute phase of TS, biventricular pacing could be an appropriate approach as the estimated ventricular pacing ratio remains high.

CONCLUSION

TS is an acute but transient heart failure syndrome and it is very uncommon for TS to present as syncope with complete AV block. Many cases of AV block associated with TS do not

return to sinus rhythm even after the recovery of ventricular functions, and thereby require permanent pacemaker implantation. The decision to implant a permanent pacemaker should be considered on a case-by-case basis, and an electrophysiological study could be valuable in this decision.

Informed Consent: Written informed consent was obtained from patient who participated.

Peer-review: Externally peer-reviewed.

Author Contributions: Concept/Design - BK; Analysis/Interpretation - ZEG; Data Collection - MA; Writing - ŞK; Critical Revision - BK; Final Approval - AU; Statistical Analysis - AK; Obtained Funding - MA; Overall Responsibility - ŞK, BK.

Conflict of Interest: All authors declare that they do not have conflict of interest.

Financial Disclosure: The authors declared that this study has received no financial support.

REFERENCES

1. Y-Hassan S, De Palma R. Contemporary review on the pathogenesis of takotsubo syndrome: The heart shedding tears: Norepinephrine churn and foam at the cardiac sympathetic nerve terminals. *Int J Cardiol* 2017;228:528-36. [\[Crossref\]](#)
2. Cramer MJ, De Boeck B, Melman PG, Sieswerda GJ. The 'broken heart' syndrome: What can be learned from the tears and distress? *Neth Heart J* 2007;15:283-5. [\[Crossref\]](#)
3. Y-Hassan S. Clinical features and outcome of epinephrine-induced takotsubo syndrome: Analysis of 33 published cases. *Cardiovasc Revasc Med* 2016;17:450-5. [\[Crossref\]](#)
4. Brown KH, Trohman RG, Madias C. Arrhythmias in takotsubo cardiomyopathy. *Card Electrophysiol Clin* 2015;7:331-40. [\[Crossref\]](#)
5. Parekh A, Sengupta V, Zainea M. An unusual case report of stress-induced cardiomyopathy presenting as ventricular fibrillation cardiopulmonary arrest and third-degree atrioventricular block. *Eur Heart J Case Rep* 2021;5:ytab142. [\[Crossref\]](#)
6. Cativo EH, Valvani R, Mene-Afejuku TO, Cativo DP, Mushiyevev S. A rare association of Takotsubo cardiomyopathy with high-degree atrioventricular block. *Case Rep Cardiol* 2017;6989438. [\[Crossref\]](#)
7. Nault MA, Baranchuk A, Simpson CS, Redfearn DP. Takotsubo cardiomyopathy: a novel "proarrhythmic" disease. *Anadolu Kardiyol Derg* 2007;7(Suppl 1):101-3.
8. Terui T, Iwai-Takano M, Watanabe T. Permanent pacemaker implantation in a patient with takotsubo cardiomyopathy and complete atrioventricular block. *Case Rep Cardiol* 2021;6637720. [\[Crossref\]](#)
9. McGee MJ, Yu W, McCarthy J, Barlow M, Hackworthy R. Complete heart block complicating takotsubo syndrome: case report and literature review. *Case Rep Cardiol* 2020;7614836. [\[Crossref\]](#)