



# Rare Combination of Pulmonary Sling and Aberrant Right Subclavian Artery with Left Aortic Arch in The Same Infant

Betül Çınar<sup>1</sup> , Sezen Ugan Atik<sup>1</sup> , Aysel Türkvatan Cansever<sup>2</sup> , Sertaç Haydın<sup>3</sup> , Alper Güzeltaş<sup>1</sup> 

<sup>1</sup> Department of Pediatric Cardiology, Mehmet Akif Ersoy Thoracic and Cardiovascular Surgery Training and Research Hospital, Istanbul, Turkey

<sup>2</sup> Department of Radiology, Mehmet Akif Ersoy Thoracic and Cardiovascular Surgery Training and Research Hospital, Istanbul, Turkey

<sup>3</sup> Department of Pediatric Cardiovascular Surgery, Mehmet Akif Ersoy Thoracic and Cardiovascular Surgery Training and Research Hospital, Istanbul, Turkey

## ABSTRACT

Although rare, vascular sling-ring complexes together in the same patient may be encountered. Once clinical complaints compatible with vascular ring anomalies are described, it should be kept in mind that more than one anomaly may be associated. By this case, the diagnostic and therapeutic course of pulmonary sling and aberrant right subclavian artery in an infant with breathing and feeding difficulties was presented.

**Key Words:** Aberrant right subclavian artery; children; pulmonary sling.

## Pulmoner Sling ve Aberran Sağ Subklavyen Arter Birlikteliği

### ÖZ

Nadir de olsa aynı hastada vasküler sling-ring anomalileri birlikte görülebilir. Vasküler halka anomalileri ile uyumlu klinik şikayetler varlığında birden fazla anomalinin ilişkili olabileceği akılda tutulmalıdır. Bu olgu ile solunum ve beslenme güçlüğü çeken bir bebekte pulmoner sling ve normal sağ subklavyen arterin tanı ve tedavi seyri sunulmuştur.

**Anahtar Kelimeler:** Anormal sağ subklavyen arter; çocuk; pulmoner sling.

## INTRODUCTION

Pulmonary sling (PS) and aberrant right subclavian artery (ARSA) are separate vascular ring anomalies which are caused by the incomplete involution of embryonic structures that give origin to those vessels. From anatomical point of view, in patients with PS anomaly, the left pulmonary artery originates from the right pulmonary artery and encircles the distal trachea through its course between the trachea and esophagus to the hilum of the left lung. The other entity, ARSA, is characterized by its arise directly from the aortic arch instead of originating from the brachiocephalic artery. Most of the times these two are seen separately, so that their coexistence in an infant is extremely rare. In this case report, we present the unusual coexistence of multiple vascular ring anomalies in an infant, providing the successful surgical management to correct the pathologies. The aim is to bring awareness that, though rarely, PS and ARSA in the context of left dominant aortic arch may coexist.

## CASE REPORT

A four-month-old, 3.5 kg female infant, whose birth weight was 2.5 kg after a full term labor, was admitted to our out-patient clinic due to the complaints of recurrent exacerbations of noisy breathing and barking cough that deteriorate after feeding episodes. Other than failure to thrive, on physical examination, a mild stridor that became more evident as she cried was heard along with clear pulmonary vesicular breath sounds and 93% saturation of oxygen was obtained on the room air. Telecardiogram revealed no pathology, as well the electrocardiogram presented normal sinus rhythm, normal QRS axis for her age and heart rate of 130 beats per minute. Echocardiography showed that the left pulmonary artery was originating from the right pulmonary artery on the modified parasternal short-axis

*Cite this article as: Çınar B, Ugan Atik S, Türkvatan Cansever A, Haydın S, Güzeltaş A. Rare combination of pulmonary sling and aberrant right subclavian artery with left aortic arch in the same infant. Koşuyolu Heart J 2021;24(Suppl 1):S68-S70.*

## Correspondence

**Betül Çınar**

**E-mail:** cinar\_betul@hotmail.com

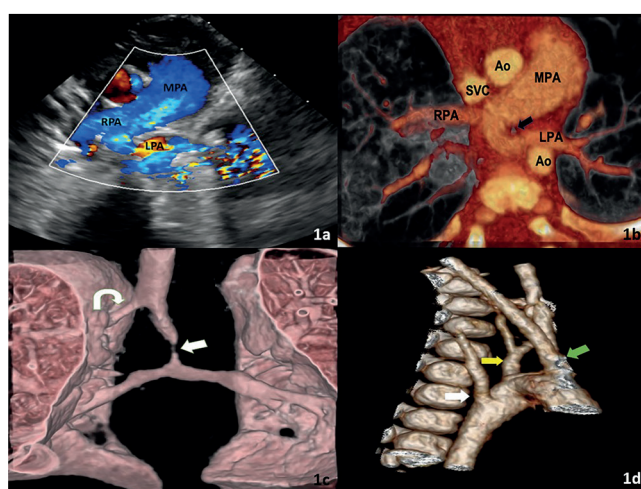
**Submitted:** 14.04.2021

**Accepted:** 25.08.2021

**Available Online Date:** 25.08.2021

© Copyright 2021 by Koşuyolu Heart Journal. Available on-line at [www.kosuyoluheartjournal.com](http://www.kosuyoluheartjournal.com)

view with the measurements as follows: the main pulmonary artery: 11.2 mm (Z score: +1.80), the right pulmonary artery: 6.1 mm (Z score: +1.27) and the left pulmonary artery: 5 mm (Z score: +0.53) (Figure 1a). Additionally, a patent ductus arteriosus (PDA) that drains into the main pulmonary artery via a left-to-right shunt with a color flow diameter of 2.6 mm at the narrowest point, which provides a continuous flow sample and 60 mmHg gradient between the aorta and the pulmonary artery on continuous-wave Doppler, has taken attention on both short axis and suprasternal views. On computed tomography, it was confirmed that the pulmonary trunk continued as the right main pulmonary artery and gave a branch to the left pulmonary artery from its posterior aspect (Figure 1b). The left main pulmonary artery showed aberrant course in the posterior of the trachea, extending from the midline to the left hemithorax creating significant pressure on the trachea through its course (Figure 1c). Moreover, a right subclavian artery emerging from the descending aorta was observed, while the PDA was also visible (Figure 1d). After the diagnosis of PS accompanied with ARSA and PDA was clarified, the relief of the left pulmonary artery behind the trachea with anastomosing it to the left side of the main pulmonary artery, division of both PDA and ARSA were performed as the surgical correction. The patient, whose general condition remained stable in the postoperative period, was discharged eventually. The clinical follow-up of the patient is ongoing and uneventful with gradual resolution of the presenting symptoms.



**Figure 1.** Echocardiographic modified parasternal short axis (a) and transverse reformatted CT image (b) demonstrating the left pulmonary artery which originates from the right pulmonary artery with its course between the trachea (black arrow) and the aorta. 3D reformatted image of the airways (c) clearly depicts the significant compression on the distal trachea (arrow). A tracheal bronchus variant is also seen (curved arrow). 3D reformatted image of the aortic arch (d) shows the origins of the common carotid trunk (green arrow), supraaortic vessels and aberrant right subclavian artery as well (white arrow). Yellow arrow denotes the left subclavian artery (MPA: Main pulmonary artery, LPA: Left pulmonary artery, RPA: Right pulmonary artery, Ao: Aorta, SVC: Superior caval vein).

## DISCUSSION

In our case report, the point to draw attention to is that PS and ARSA can be encountered in the same patient especially if the presentation reflects a combination of both respiratory and digestive symptoms. Both anomalies are a group of incomplete vascular rings for which the embryological root must be revised in order to better understand. During the fourth and fifth weeks of development, the aortic sac gives rise to six bilateral aortic arches which will eventually form the great vessels by regression of some and persistence of others. PS occurs from an unexpected involution of the proximal left sixth arch which would supply blood to the left pulmonary bud. An anastomotic vessel linking the primitive pulmonary circulations becomes the anomalous left pulmonary artery which courses to the left hilum between the trachea and esophagus. A PDA originating from the left sixth arch and a persistent left superior caval vein originating from the left common cardinal vein are seen to be frequently accompany to PS. On the other hand, in ARSA the right aortic arch regresses “between” rather than distal to the common and right subclavian arteries thus preventing the formation of brachiocephalic trunk. As a result, the vessel arises as the last branch of the left aortic arch and passes obliquely from the left to the right, usually posterior to the esophagus<sup>(1)</sup>.

The association of the subclavian arteries from the abnormal origin with the PS has been previously described. However, the association of PS with ALSA rather than ARSA has been shown more frequently in publications. We suppose that the rarity of ARSA and PS together with left dominant aortic arch makes our patient special. Wittenborg and colleagues published that ARSA existed as an additional anomaly in a postmortem study of their one patient with PS who had cyanotic attacks from the neonatal period<sup>(2)</sup>. As for speaking of additional cardiovascular anomalies, a large study from Xie et al with their 47 PS patients, 3 patients had been reported to have associated ARSA, in the meantime ventricular septal defect, atrial septal defect, PDA and persistent left superior caval vein were their additional common findings in PS patients<sup>(3)</sup>. Clinical presentation most commonly starts with symptoms of stridor, cough, recurrent upper respiratory tract infections and even cyanotic episodes in case of severe tracheal obstruction or already existing tracheomalacia. Although it has been described that intrinsic tracheobronchial stenosis or diverticula may be noticed especially in patients with pulmonary sling, no anatomical tracheal variation has been observed in our patient following the relief of the stenosis caused by the vascular pressure. Esophageal compression is usually posterior, so slow feeding or fatigue during feeding are among the symptoms that may occur in infancy, whereas some patients may maintain an asymptomatic clinical course especially with ARSA. In the published series of 21 cases with vascular ring anomalies,

which was conducted in our center, the most frequent symptoms reported at presentation were wheezing (48%), shortness of breath (40%) and difficulty swallowing (20%), respectively<sup>(4)</sup>. Our patient had recurrent upper respiratory tract issues related to the compression of the left pulmonary artery on the trachea, which was corrected surgically with the clamping of the left pulmonary artery from the right pulmonary artery in the beating heart and its division. Afterwards, the opening in the right pulmonary artery was sutured primarily and the left pulmonary artery was released from the back of the trachea and anastomosed to the left side of the main pulmonary artery. At the same session, as the case also had difficulties with feeding and swallowing, the pressure of aberrant right subclavian was released by its division at its branching point from the descending aorta and the PDA was also divided.

On the path to the diagnosis, a detailed evaluation by echocardiography can be a proper start. Suprasternal examination is very useful in showing the direction of the aortic arch and the anatomical configuration of the structures branching from it. Once the side of the aortic arch is established, the absence of visualization of its branching from brachiocephalic trunk, which is the first branch emerging from the ascending aorta, acts as a diagnostic indicator for an ARSA. Another useful window is parasternal short axis evaluation as it delineates the course of the main pulmonary artery and its branches. Therefore, although transthoracic echocardiography may not be the best imaging technique for the diagnosis of vascular ring anomalies, a suprasternal and parasternal short axis views aiming at vascular ring anomalies should be performed providing full scan for possible extra cardiovascular anomalies for all patients with vascular ring-compatible symptoms. Moreover, the utilization of radiological screening techniques to both detail the diagnosis and guide the surgical planning would be beneficial. Although different opinions continue to be published in terms of diagnostic superiority of

magnetic resonance imaging and computed tomography in vascular anomalies, in our clinic tomography with low dose radiation usage is preferred as it does not require sedation, and shows trachea and bronchial anatomy in more detail<sup>(5)</sup>.

In conclusion, our case showed that multiple vascular anomalies can be seen together in the same patient, and this rare combination should be kept in mind in patients with recurrent, medical therapy-resistant respiratory and nutritional symptoms.

---

**Informed Consent:** Informed consent form was obtained from patient.

**Peer-review:** Externally peer-reviewed.

**Author Contributions:** Concept/Design - All of authors; Analysis/ Interpretation - All of authors; Data Collection - All of authors; Writing - All of authors; Critical Revision - All of authors; Statistical Analysis - All of authors; Obtained Funding - All of authors; Overall Responsibility - All of authors; Final Approval - All of authors.

**Conflict of Interest:** The authors have no conflicts of interest to declare

**Financial Disclosure:** The authors declared that this study has received no financial support.

---

## REFERENCES

1. Ilina M, Lilley S. Embryology of the great vessels. *Clinical Embryology*. Springer, 2019:275-88.
2. Wittenborg MH, Tantiwongse T, Rosenberg BF. Anomalous course of left pulmonary artery with respiratory obstruction. *Radiology* 1956;67:339-45.
3. Xie J, Juan YH, Wang Q, Chen J, Zhuang J, Xie Z, et al. Evaluation of left pulmonary artery sling, associated cardiovascular anomalies, and surgical outcomes using cardiovascular computed tomography angiography. *Scientific Reports* 2017;7:1-10.
4. Tola H, Ozturk E, Yildiz O, Ereğ E, Haydin S, Turkvatan A, et al. Assessment of children with vascular ring. *Pediatr Int* 2017;59:134-40.
5. Leonardi B, Secinaro A, Cutrera R, Albanese S, Trozzi M, Franceschini A, et al. Imaging modalities in children with vascular ring and pulmonary artery sling. *Pediatric Pulmonology* 2015;50:781-8.