



Pacemaker Lead Related Severe Tricuspid Stenosis and A History of Severe COVID-19 Pneumonia: A Case Report

Kadriye Memiç Sancar¹ , Gamze Babür Güler¹ , Enes Arslan¹ , Ender Öner¹ , Ekrem Güler² , Mustafa Yıldız¹

¹ Department of Cardiology, Mehmet Akif Ersoy Thoracic and Cardiovascular Surgery Training and Research Hospital, Istanbul, Turkey

² Department of Cardiology, Faculty of Medicine, University of Istanbul Medipol, Istanbul, Turkey

ABSTRACT

Tricuspid stenosis occurs after the implantation of a ventricular pacemaker lead and is a rare complication. An inflammatory response is stimulated when the pacemaker leads are passing through the tricuspid valve which leads to fibrosis in the long-term. In our case report, we aim to present a patient with asymptomatic multiple pacemaker lead- related tricuspid stenosis and with a history of severe COVID-19 pneumonia.

Key Words: Pacemaker lead; transesophageal echocardiography; tricuspid valve.

Pacemaker Lead İlişkili Ciddi Triküspit Stenozu ve Ciddi COVID-19 Pnömoni Hikayesi: Olgu Sunumu

ÖZ

Triküspit stenozu ventriküler pacemaker lead implantasyonu sonrası gelişen ve nadir görülen bir komplikasyondur. Pacemaker lead triküspit kapağı geçtiğinde inflamatuvar yanıt gelişir ve bu durum uzun dönemde fibroz ile sonuçlanır. Bu olgu sunumunun amacı, ağır geçirilmiş COVID-19 pnömonisi ve pacemaker lead ilişkili asemptomatik ciddi triküspit stenozu olan bir olguyu sunmaktır.

Anahtar Kelimeler: Pacemaker lead; transözefageal ekokardiyografi; triküspit kapak.

INTRODUCTION

Tricuspid stenosis (TS) is a rare complication that may occur after the implantation of a ventricular pacemaker electrode⁽¹⁾. An inflammatory response (inflammation) occurs when the pacemaker leads are passing through the tricuspid valve (TV), and this condition can lead to fibrosis in the long term⁽²⁾. A wide array of studies has reported cardiovascular (CV) complications in COVID-19 patients^(3,4). We aimed to present a patient who had a history of prolonged hospitalization due to COVID-19 pneumonia and was referred to our cardiology clinic and was detected to have multiple looped pacemaker leads through radiological examination, a condition as severe as COVID-19 pneumonia.

CASE REPORT

A 68-year-old female patient was referred to our clinic for further evaluation after having been diagnosed with TS in another outpatient clinic. Her COVID-19 PCR test was negative. The patient had lately stayed in the hospital for 20 days due to severe COVID-19 pneumonia (Figure 1). She had a pacemaker lead implanted 20 years ago due to a complete atrioventricular (AV) block. In our clinic, her examination findings were as follows: her pulse was regular with a heart rate of 85 bpm, her blood pressure was 128/79 mmHg, and her oxygen saturation was 95%. She had neither any complaints nor signs of hepatomegaly, lower extremity edema, and jugular venous distension. Newly performed chest radiography suggested the presence of a loop caused by ventricular lead at the TV level and the existing leads of the former pace implantation (Figure 2). The echocardiographic evaluation reported normal ranges for size and function of the right and left ventricles. A transthoracic echocardiogram identified a TS with a mean gradient of 8 mmHg and a maximum gradient of 16 mmHg at the normal resting heart rate (Figure 3). Pressure half time was measured

Cite this article as: Memiç Sancar K, Babür Güler G, Arslan E, Öner E, Güler E, Yıldız Y. Pacemaker lead related severe tricuspid stenosis and a history of severe COVID-19 pneumonia: a case report. Koşuyolu Heart J 2021;24(3):252-254.

Correspondence

Kadriye Memiç Sancar

E-mail: drkadik@gmail.com

Submitted: 26.08.2021

Accepted: 27.08.2021

Available Online Date: 29.08.2021

© Copyright 2021 by Koşuyolu Heart Journal.
Available on-line at
www.kosuyoluheartjournal.com

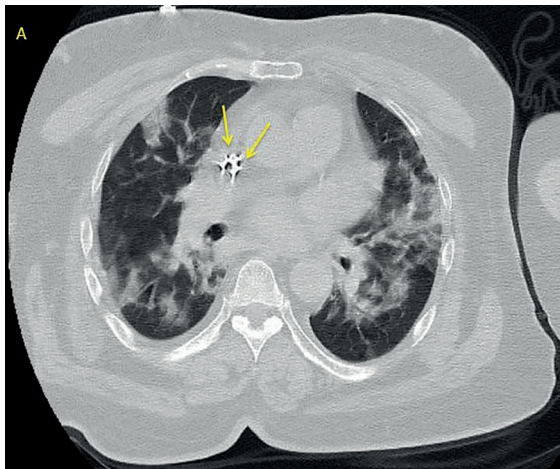


Figure 1. Chest computed tomography in severe COVID-19 pneumonia showing pace leads in RA and multiple lesions involving multiple lobes of bilateral lungs.

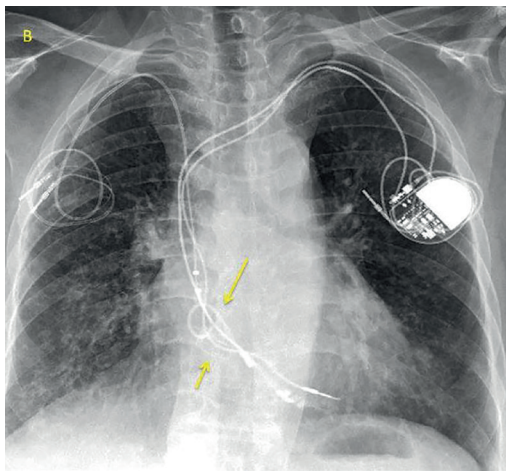


Figure 2. Chest radiography after hospital discharge showing multiple leads.

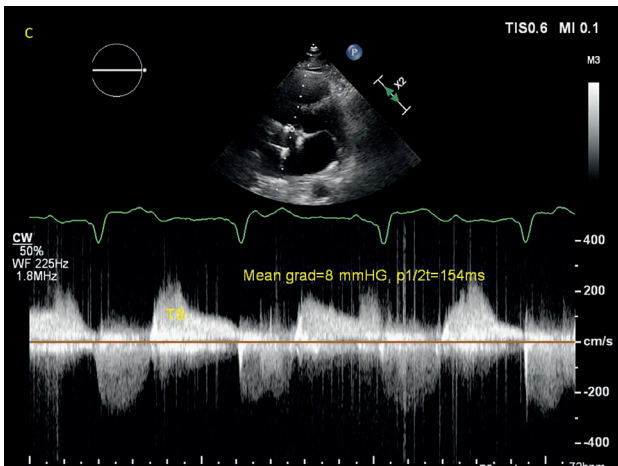


Figure 3. Continuous-wave Doppler of tricuspid stenosis jet showing high tricuspid mean gradient and pressure half-time (T1/2) values.

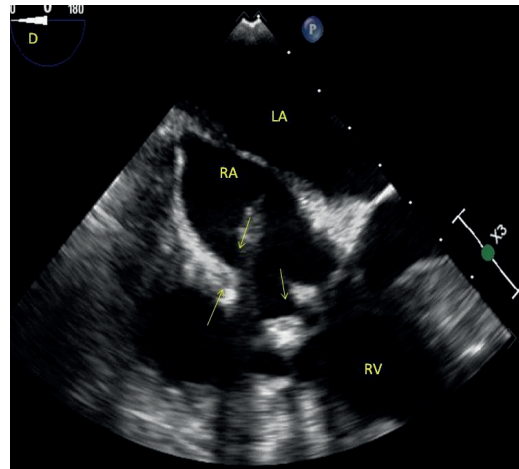


Figure 4. Mid-esophageal four-chamber view of transesophageal echocardiography showing looped and calcified leads (RA: Right atrium, LA: Left atrium, RV: Right ventricle).

as 154 milliseconds. Inferior vena cava size was normal with normal inspiratory collapse. The TV was limitedly evaluated in the transesophageal echocardiography due to the calcified leads which filled the right atrium (RA) (Figure 4). The TV posterior leaflet was thicker and had a restricted leaflet opening. Leads were preventing tricuspid inflow and caused possible adhesions and retraction of the TV. TS was found to be associated with both multiple lead-induced occlusion and lead-induced fibrosis of the valve. The patient was showing no clinical and echocardiographic signs of heart failure and having no suspected infective endocarditis during her consultation, thus the Heart Team planned the medical treatment and decided to closely monitor the patient.

DISCUSSION

A wide spectrum of complications, including acute coronary syndrome, myocarditis, acute-onset heart failure, arrhythmias, and cardiac arrest may arise in the presence of COVID-19 infection^(3,4).

Damage to TV leaflets or subvalvular structures may be observed due to lead implantation or manipulation⁽¹⁾. These lead-related injuries include laceration, leaflet perforation, and transection of papillary muscles or chordae tendineae⁽²⁾. Imaging techniques are of vital importance in the evaluation of the relationship between the TV and the pacemaker lead or subvalvular structures.

Tricuspid regurgitation (TR) is the most common TV disease which occurs due to lead implants⁽⁵⁾. The lead passes through the TV or directly interacts with chordae tendineae and impairs leaflet coaptation. Together with the mechanical impact, the long-time interaction between the leaflet and the leads damages the mobility and coaptation of the leaflet causing inflammation and fibrosis⁽²⁾.

Lead-related TS is not common in the literature⁽¹⁾. The clinical course is mostly asymptomatic in the long-term, and the diagnosis is delayed, thus the patient presents with right heart failure⁽⁶⁾. In the literature, lead-related TS was reported to be treated with surgical replacement, surgical valvuloplasty, or percutaneous balloon valvuloplasty⁽⁷⁾. Uijlings et al., presented a surgical treatment of a pace-related TS in a patient presenting with right heart failure⁽⁷⁾. In our country, Cetiner et al., performed a successful percutaneous valvuloplasty to a severe symptomatic TS developed after endocardial VVI pacemaker lead implantation in an 18-year-old⁽⁸⁾. However, corrective interventions are highly challenging in lead-associated TV damage because of the ventricular lead position across the TV.

In conclusion, our case is significant as the patient did not have any findings that suggest right heart failure despite the pacemaker lead-related TS and prior COVID-19 pneumonia. Although radiologically revealed COVID-19 pneumonia and multiple leads were worrisome in the first place, the asymptomatic condition of our patient and the possible risks of invasive procedures were the main determining factors in the treatment plan of our patient.

Informed Consent: Informed consent was obtained.

Peer-review: Externally peer-reviewed.

Author Contributions: Concept/Design - KS, GG; Analysis/Interpretation - EA, EO; Data Collection - EA, EO; Writing - KS; Critical Revision - GG, MY; Statistical Analysis - MY; Final Approval - All of Authors.

Conflict of Interest: The authors have no conflicts of interest to declare.

Financial Disclosure: The authors declared that this study has received no financial support.

REFERENCES

1. Husain A, Raja FT, Fatallah A, Fadel B, Alsanei A, Raja FT, et al. Tricuspid stenosis: an emerging disease in cardiac implantable electronic devices era. Case report and literature review. *J Cardiol Cases* 2017;15:190-3. [\[Crossref\]](#)
2. Chang JD, Manning WJ, Ebrille E, Zimetbaum PJ. Tricuspid valve dysfunction following pacemaker or cardioverter-defibrillator implantation. *J Am Coll Cardiol* 2017;69:2331-41. [\[Crossref\]](#)
3. Shi S, Qin M, Shen B, Cai Y, Liu T, Yang F, et al. Association of cardiac injury with mortality in hospitalized patients with COVID-19 in Wuhan, China. *JAMA Cardiol* 2020;5:802-10. [\[Crossref\]](#)
4. Xu Z, Shi L, Wang Y, Zhang J, Huang L, Zhang J, et al. Pathological findings of COVID-19 associated with acute respiratory distress syndrome. *Lancet Respir Med* 2020;8:420-2. [\[Crossref\]](#)
5. Polewczyk A, Kutarski A, Tomaszewski A, Brzozowski W, Czajkowski M, Polewczyk M, et al. Lead dependent tricuspid dysfunction: analysis of the mechanism and management in patients referred for transvenous lead extraction. *Cardiol J* 2013;20:402-10. [\[Crossref\]](#)
6. Krishnan A, Moulick A, Sinha P, et al. Severe tricuspid valve stenosis secondary to pacemaker leads presenting as ascites and liver dysfunction: a complex problem requiring a multidisciplinary therapeutic approach. *J Interv Card Electrophysiol* 2009; 24: 71-75. [\[Crossref\]](#)
7. Uijlings R, Kluin J, Salomonsz R, Burgmans M, Cramer MJ. Pacemaker lead-induced severe tricuspid valve stenosis. *Circ Heart Fail* 2010;3:465-7. [\[Crossref\]](#)
8. Çetiner N, Baştuhan IY, Özyiğit T, Mutluer FO, Çeliker A. Pacemaker lead-induced tricuspid stenosis treated with percutaneous valvotomy. *Turk J Pediatr* 2020;62:681-4. [\[Crossref\]](#)