



A Simple and Safe Technique for Intraoperative Peritoneal Dialysis Catheter Insertion in Neonates

Yenidoğanlarda İntraoperatif Periton Diyaliz Katateri Takılması için Basit ve Güvenli Bir Teknik

Dilek Suzan¹([iD](#)), Bahar Temur²([iD](#)), Selim Aydın²([iD](#)), Ersin Ereğ²([iD](#))

¹ Acıbadem University School of Medicine, Department of Pediatric Cardiovascular Surgery, Istanbul, Turkey

² Acıbadem University School of Medicine, Department of Cardiovascular Surgery, Istanbul, Turkey

INTRODUCTION

Extravascular fluid retention is a common problem after complex congenital heart surgery in neonates due to capillary leak, which may result in pulmonary and systemic tissue edema which can decrease respiratory system compliance, impair gas exchange, alter hemodynamics, and delay metabolic recovery. This clinical condition is further exacerbated by postoperative low cardiac output states and secondary renal dysfunction. Transient peritoneal dialysis is a common practice to prevent these complications. It has been demonstrated that the combination of perioperative ultrafiltration sustained with peritoneal dialysis (PD) provides significant improvement in postoperative hemodynamics, cardiac function, and renal functions besides providing the required negative fluid balance in especially neonates with complex congenital heart diseases and affected survival positively. It has also been reported that the use of PD catheters to drain the fluid passively is effective for promoting negative fluid balance as a less aggressive means. Prophylactic insertion of a PD catheter intraoperatively may provide to achieve desirable fluid management without delay^(1,2).

Usual practice for intraoperative PD catheter insertion is passing the catheter into the peritoneal cavity through a purse-string suture located on the subxiphoid area. But this method may carry the risk of leakage of the dialysis solution into the mediastinal cavity and might increase the risk of mediastinal infection. Here, we report a simple and safe method for intraoperative PD catheter implantation technique during cardiac operations in neonates.

Technique

After weaning from cardiopulmonary bypass (CPB), a 6/0 prolene purse-string suture is put on the peritoneum at the subxiphoid area. A small stab wound is made. Through it, a right-angled clamp is inserted into the left side of the peritoneal cavity and with the guidance of the tip of the clamp, a small puncture incision is made on the left side of the abdominal wall (Figure 1). Tip of the clamp is pushed outside through this small puncture. PD catheter is held and taken inside the peritoneal cavity (Figure 2). The right-angled clamp is taken off and the purse-string suture is closed firmly. A silk suture is tied to the PD catheter to keep it in place (Figure 3). We usually use soft silicon PD catheters, Tenckhoff type. Kendall Quinton Curl Catheter (Tyco Healthcare Group LP, Mansfield, MA, USA) of 62 cm length.

Comment

Insertion of a PD catheter during the postoperative period usually necessitates a 1 to 2 cm subumbilical incision to reach the peritoneum surgically. This technique has a risk for hepatic or bowel injury. Leakage of the dialysate solution through the wound and omental herniation is also common complications. This technique may cause delay in management since it necessitates experienced staff, specialized equipment and extra time. Risk of contamination peritonitis and surgical site infection might be other disadvantages of this

Cite this article as: Suzan D, Temur B, Aydın S, Ereğ E. A simple and safe technique for intraoperative peritoneal dialysis catheter insertion in neonates. Kosuyolu Heart J 2020;23(3):227-9.

Correspondence

Dilek Suzan

E-mail: suzandilek@yahoo.com

Submitted: 16.07.2020

Accepted: 28.07.2020

Available Online Date: 29.12.2020

© Copyright 2020 by Kosuyolu Heart Journal.

Available on-line at

www.kosuyoluheartjournal.com

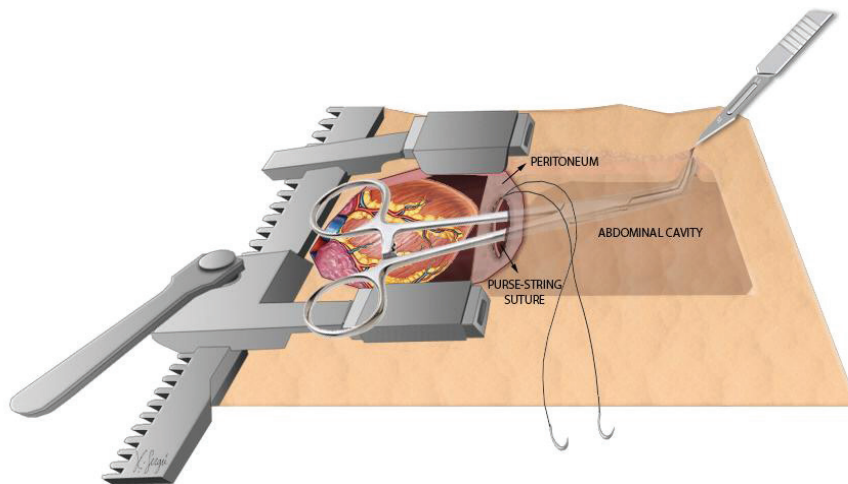


Figure 1. Inserted right-angled clamp through the purse-string suture on the peritoneum.

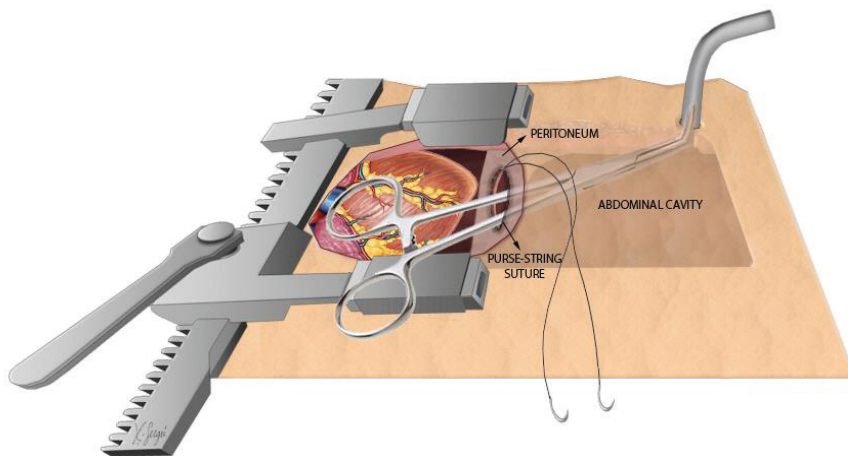


Figure 2. Tip of the clamp is pushed through the puncture incision of the abdominal cavity and PD catheter is taken into the peritoneal cavity.

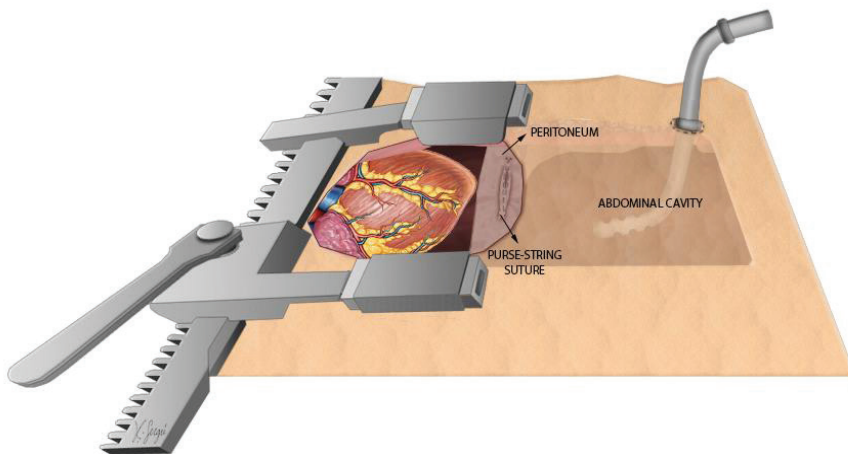


Figure 3. Both purse-string suture on the peritoneum side and silk suture on the abdominal cavity are tied.

technique⁽³⁻⁵⁾. Intraoperative insertion of the PD catheter through the subxiphoid opening minimizes the risk of hepatic and bowel injury, prevents the omental herniation through the skin, but it might still herniate into the mediastinum. Leakage of the dialysate solution into the mediastinum and leakage of the mediastinal drainage into the peritoneal cavity are other potential disadvantages.

Our technique is safe and effective to prevent these complications and provides a safe barrier between the pericardium and the peritoneum. Risk of infection, omental herniation and dialysate leakage may be low with this technique. We propose to insert routine intraoperative PD catheter with this technique in neonates who undergo complex congenital heart surgery to help achieve the desired fluid management immediately after surgery. We usually leave the PD catheter to close passive drainage and start peritoneal dialysis rapidly in case of necessity.

Informed Consent: Written informed consent was obtained from patient who participated.

Peer-review: Externally peer-reviewed.

Author Contributions: Concept/Design - DS; Analysis/Interpretation - DS; Data Collection - BT, SA, DS; Writing - DS; Critical Revision - BT, EE, SA; Statistical Analysis - EE, SA, BT, DS; Obtained Funding - DS, BT, SA, EE; Final Approval - EE; Overall Responsibility - DS, EE.

Conflict of Interest: The authors have no conflict of interest to declare.

Financial Disclosure: The authors declared that this study has received no financial support.

REFERENCES

1. Xinjin L, Jianping X, Xiangdong S, Xia C. Peritoneal dialysis after repair of congenital heart disease in children. *Chin Med Sci J* 2003;18:100-4.
2. Alkan T, Akçevin A, Türkoğlu H, Paker T, Şaşmaz A, Bayer V, et al. Postoperative prophylactic peritoneal dialysis in neonates and infants after complex congenital cardiac surgery. *ASAIO Journal* 2006;52:693-7.
3. Radtke J, Lemke A, Kemper MJ, Nahan B, Koch MJ. Surgical complications after peritoneal dialysis catheter implantation depend on children's weight. *Pediatr Surg* 2016;51:1317-20.
4. Macchini F, Valadè A, Ardissino G, Testa S, Edefonti A, Torricelli M, et al. Chronic peritoneal dialysis in children: catheter related complications. A single centre experience. *S Pediatr Surg Int* 2006;22:524-8.
5. Yata N, Ishikura K, Hataya H, Ikeda M, Honda M. Peritoneal dialysis catheter-related complications. *Nihon Jinzo Gakkai Shi* 2003;45:378-80.