

---

# COMPARISON OF COLOUR DOPPLER AND DESCENDING PHLEBOGRAPHY IN CHRONIC VENOUS INSUFFICIENCY OF THE LOWER EXTREMITY

---

M. SÜNGÜN, M.D.  
B. S. CEBEÇİ, M.D.  
S. DEMİREĞEN, M.D.  
D. SABA, M.D.  
M. US, M.D.  
N. ÖZCAN, M.D.  
and  
E. DURAN, M. D.

From: GATA Haydarpaşa  
Education Hospital, Istanbul  
Türkiye  
Address for  
reprints:  
Mutasım SÜNGÜN, M.D.,  
GATA Haydarpaşa  
Education Hospital,  
Istanbul, Türkiye

*The purpose of this study is to identify and compare the value of colour Doppler and descending phlebography in the differential diagnosis and surgical therapy of chronic venous insufficiency of the lower extremities.*

*Twenty-three extremities of 18 patients with chronic venous insufficiency admitted to GATA Education Hospital, Cardiovascular Surgery Department were included in this study. Colour Doppler and descending phlebography were performed to all of the extremities in order to determine the incompetent valves and the degree of insufficiency, and assess the place of surgical intervention.*

*Venous reflux was found in colour Doppler examination of 45 levels; including 18 in saphenofemoral junction, 19 in superficial femoral veins, 8 in deep femoral veins. First degree venous insufficiency was obtained in descending phlebography of two deep femoral veins reported to be normal in colour Doppler study. In one limb with a first degree saphenofemoral insufficiency obtained in colour Doppler, there wasn't any reflux with descending phlebography.*

*Colour Doppler examination is sufficient in the diagnosis of chronic venous insufficiency. It shows the anatomical distribution and the degree of insufficiency accurately, but descending phlebography should be done to all limbs where surgical intervention is programmed in order to choose the ideal technique. In other words, descending phlebography is the gold standard, and is absolutely indicated in the surgical therapy of chronic venous insufficiency.*

*Key words: Descending phlebography, colour Doppler, chronic venous insufficiency*

---

**C**hronic venous insufficiency (CVI) is the failure to reduce pressure in the leg especially after exercise due to valve incompetence or obstruction in deep superficial veins. Perforating vein insufficiency usually accompanies this clinical situation<sup>1-3</sup>. Although deep vein thrombosis is considered to be the most common cause of valvular incompetence and venous reflux. Reflux can also occur as a result of congenitally defective venous valves and give rise to CVI<sup>4, 5</sup>. Chronic venous

insufficiency is estimated to affect 0.5 % of the adult population <sup>6</sup>. The manifestations of the disease are leg swelling, varices, pigmentation, liposclerosis restricting daily life and disabling physical activity of the patients <sup>4</sup>. The physical examination findings of CVI permit a clinical grading of the limb, and such a grading is an important criteria in the selection of surgical treatment <sup>7</sup>.

Although many cases can be treated with elastic compression stockings and proper skin care, surgical therapy is rather routine in practice of being a matter of choice in suitable cases. Surgical options available for deep venous reconstruction for reflux are: vein valve transplantation, venous transposition, and most commonly valve resuspension <sup>4,8-11</sup>. The methods used in diagnosis must give an answer to these questions <sup>12</sup>:

1. Is chronic venous insufficiency present? 2. What is the cause of the disease; obstruction, valve incompetence, or both? 3. What is the anatomical distribution? 4. If the reason is valvular incompetence what is the degree or severity of it? 5. Currently there are a number of both invasive and noninvasive modalities available to the physician for the evaluation of CVI in today's technological circumstances. Colour Doppler, a new diagnostic modality is now believed to take its place besides invasive ambulatory venous pressure measurement, ascending-descending phlebography, noninvasive plethysmography, and duplex sonography. With the chance to operate on

incompetent veins, a comparison must be made between the available methods of investigation in order to determine the most accurate one or ones in terms of patient, and technique selection for surgery.

Our aim in this study is to assess and compare the role of colour Doppler and descending phlebography in the differential diagnosis and surgical treatment of CVI of the lower extremities.

## METHOD

In GATA Education Hospital Cardiovascular Surgery Department, 18 male patients between the ages 22-48 (mean 28) with CVI in 23 lower extremities were evaluated. According to clinical grading of International Vascular Surgery Association, 5 extremities were in grade I, 12 in grade II, and 5 in grade III <sup>7</sup>(Table 1). Colour Doppler and descending phlebography were performed to all of the extremities.

Colour Doppler were applied with suitable wall stress and pattern intervals by Toshiba 270 SSAHB and 7.5 Mhz linear probe. This method was performed by the same doctor in 45 degrees reverse Trendelenburg position. The deep and superficial veins were investigated while patients doing a Valsalva manoeuvre. First the common femoral vein, then the superficial and deep femoral veins were demonstrated at the level of saphenofemoral junction in the groin (Level 1). Popliteal vein was found with the probe

**Table 1: Clinical grading of limbs on the basis of physical examination**

<u>Grade</u>	<u>Symptoms</u>	<u>Physical Findings</u>
1	Mild swelling, heaviness, vein dilation	Ankle edema <1cm, dilated superficial veins, normal skin and subcutaneous tissue
2	Modulate to severe swelling, heaviness, varicosities, skin changes	Edema >1 cm, multiple dilated veins, ICPV (mild), Pigmentation (mild), liposclerosis (mild)
3	Severe swelling, calf pain with or without claudication, ulcers	Edema >2 cm, multiple dilated veins, ICPV (severe), multiplane vein varicosities, marked skin pigmentation, severe liposclerosis

ICPV: Incompetent Perforating Vein

Taken from Welch HJ. et al. J Vasc Surg 1992;16:914.

located approximately 3 cm above the knee in the popliteal fossa region, while the extremity on external rotation (Level 2). Posterior tibial vein was visualised approximately 5 cm proximal to the medial malleolus (Level 3). Flows were evaluated under normal respiration and during Valsalva manoeuvre which was explained to the patient in details before the examination.

Descending phlebography was done by a colleague of us who was not aware of the results of colour Doppler examination. Descending phlebography was done in the 45 degrees reverse Trendelenburg position with a 18 G cannula inserted in the common femoral vein at the groin. While the common femoral vein was visualised by the contrast medium (Iohexol 300 mgr/dl), the patients were asked to perform Valsalva manoeuvre which helped to identify the level of the incompetent valves in the saphenofemoral junction, deep and superficial femoral veins.

### RESULTS

The venous system was visualised in all extremities with coloured Doppler and descending phlebography. Vein reflux in descending phlebographies were interpreted according to Herman's modification of Kistner's classification<sup>1</sup> and the grade of reflux evaluated by colour Doppler corresponded to the distribution of anatomical levels at which reflux was detected (Table 2). The reflux found in colour Doppler and descending phlebography was graded by the criteria of these diagnostic tools (Table 3). Vein reflux was found in colour Doppler examination at 45 levels including 18 saphenofemoral junctions, 19 superficial and 8 deep femoral veins. First grade vein reflux was obtained in descending phlebography of 2 deep femoral veins that reported to be competent in colour Doppler examination. In one limb with a first grade reflux in saphenofemoral junction on colour Doppler, no reflux was detected on descending phlebography. Statistical analysis indicated

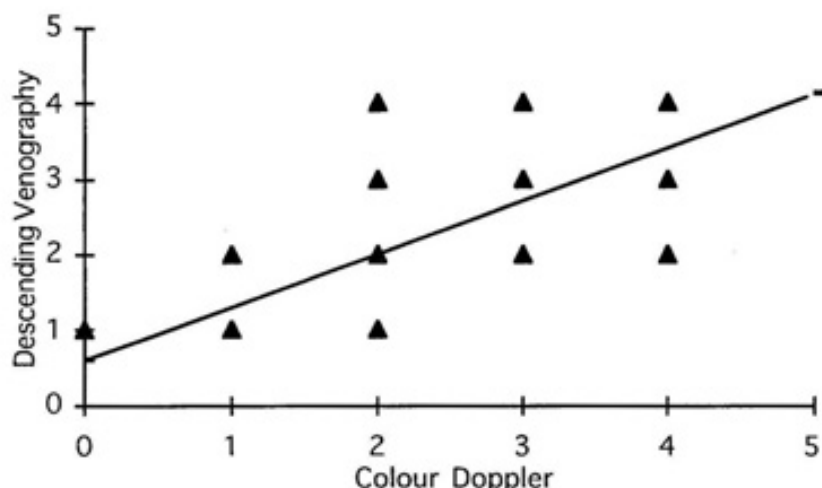
**Table 2: Grading of venous reflux detected by descending phlebography and colour Doppler**

Grade	Symtoms	Physical Findings
0	No reflux beyond confluence of common femoral vein	No reflux in femoral vein at level 1
1	Reflux down most proximal valve in superficial femoral vein	Reflux at level 1
2	Reflux down to knee	Reflux at levels 1 and 2
3	Reflux below knee	Reflux at levels 1, 2 and 3
4	Reflux down to ankle	Reflux at all levels, including 4

Taken from Baker SR.et al. Lancet 1993;341:401.

**Table 3: Comparison of grade of reflux on colour Doppler and Descending Phlebography**

Colour Doppler	Descending Phlebography				
	0	1	2	3	4
0		2			
1	1	3	1		
2		2	6	1	1
3			3	9	3
4			1	6	8



**Table IV.**  
The relation between degree of reflux at colour Doppler and descending phlebography.

good agreement between the grades of reflux detected on descending phlebography and colour Doppler (correlation index = 0.77) (Table 4).

There were 4 levels of obstruction, 1 in superficial femoral, 3 in posterior tibial veins of 23 extremities (17.4 %) examined by colour Doppler (Fig. 1A). In descending phlebography of the limb with obstruction at the superficial femoral vein, marked collateral circulation and vein wall irregularity was noticed (Fig. 1B). This was one of the 6 limbs having ulceration evaluated as grade 3.

Saphenofemoral junction incompetence alone in two, superficial and deep femoral vein incompetence combination in two, and saphenofemoral junction combined with superficial vein incompetence in one were obtained in the other patients with leg ulcers (Fig. 2A-B).

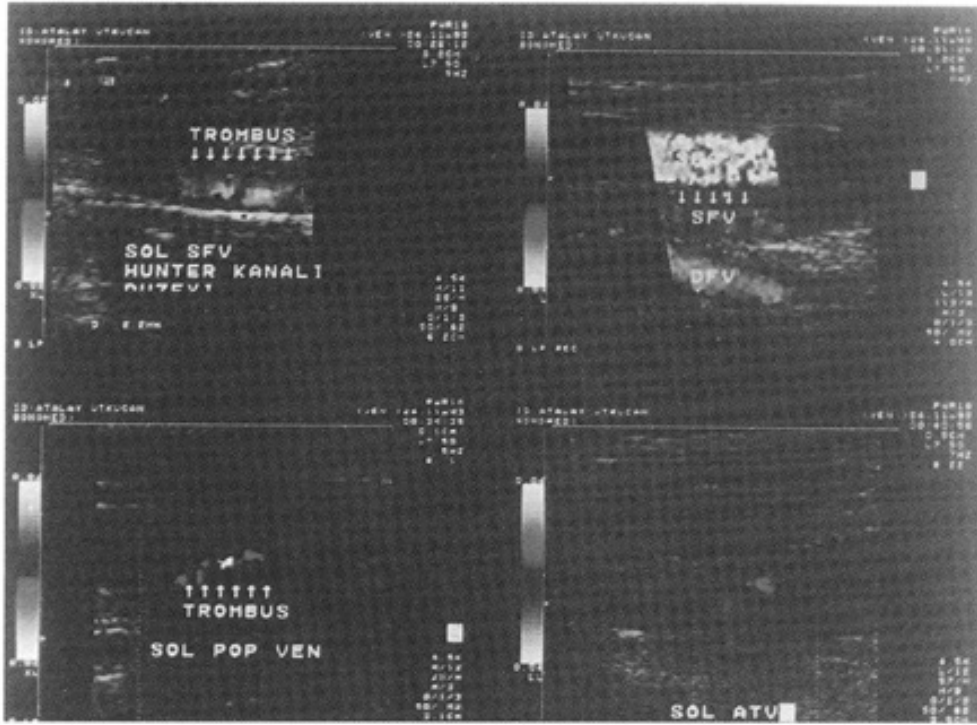
### DISCUSSION

Reflux in superficial veins alone can cause serious skin problems and ulcerations, in cases having normal deep and perforating vein systems<sup>13,14</sup>. Van Rij, determined incompetence at saphenofemoral and saphenopopliteal junctions of 72 % of extremities with leg ulcers, where there was not any reflux in deep veins. It was suggested that skin changes and ulcerations must not always be related to deep vein valvular

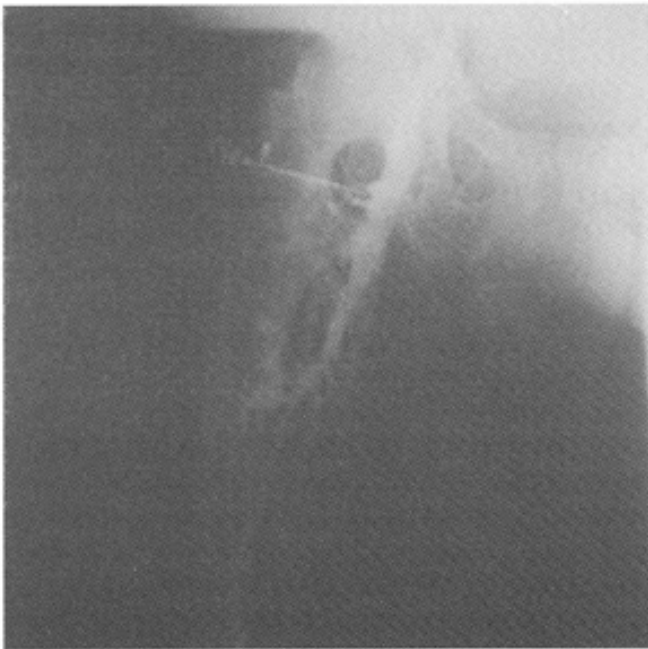
incompetence<sup>15</sup>. In this study, there was only saphenofemoral junction incompetence in the 2 of the 5 extremities alone found with both diagnostic tools in the 2 of 6 limbs. For this reason, if the etiologic cause is under suspicion in a third grade chronic venous insufficiency, it must be remembered that superficial vein incompetence determined by colour Doppler could be the only reason. Some authors suggest capillary circulation abnormalities can be the only cause of ulcers in patients with clinical grade 2 or 3 CVI, without any hemodynamic alterations in deep vein system<sup>2,12,14</sup>.

The reverse flow in the pathogenesis of CVI was first defined as free blood flow by Trendelenburg in 1891<sup>3</sup>. Van Bemmelen and colleagues described long standing reflux at common femoral vein of normal extremities in 10 degrees reverse Trendelenburg position during Valsalva manoeuvre<sup>5</sup>. Rosfors suggests that, there is minimal regurgitation in the descending phlebography of normal population even if isotonic contrast media is used<sup>16</sup>. Vasdekis has claimed that measurements during Valsalva manoeuvre are not physiological, and the real blood flow should be observed while walking or during exercise<sup>3</sup>.

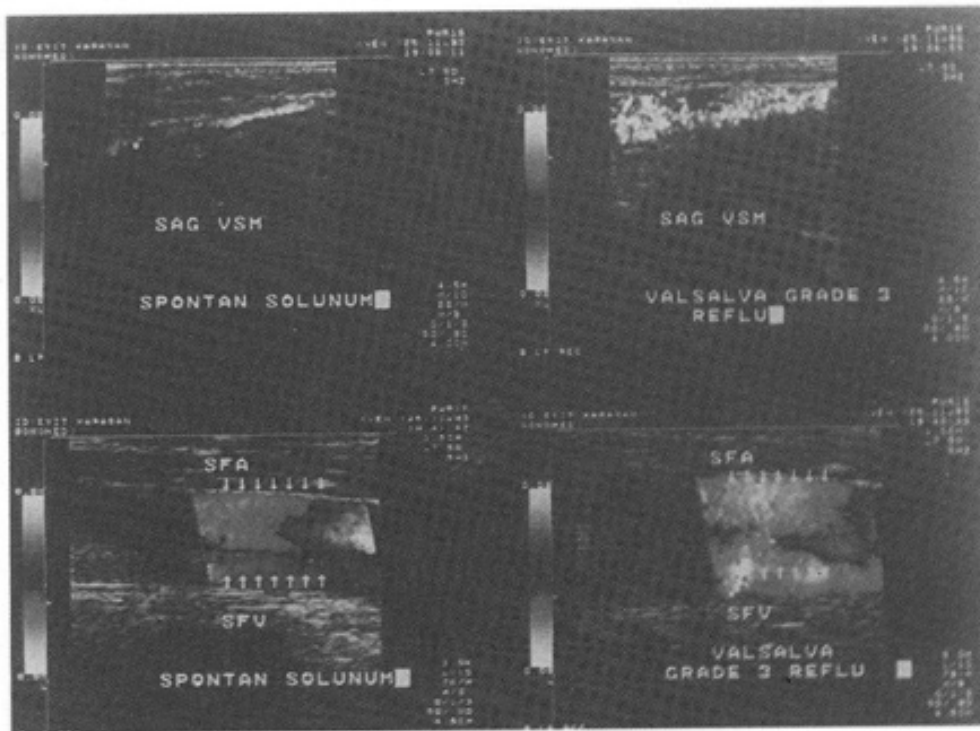
We agree with this decision because measurements during Valsalva manoeuvre are not physiological. It is very rare to make a Valsalva manoeuvre in daily activities. For this reason, measurements with both colour



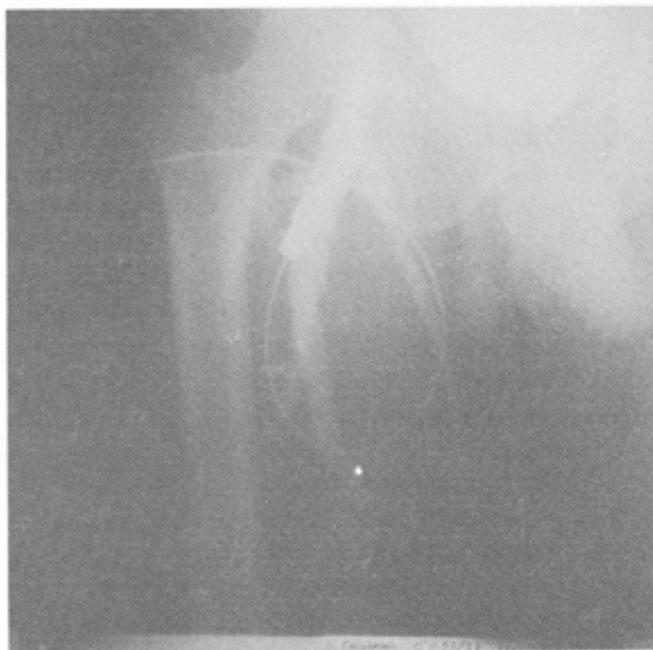
**Figure 1 A.** Obstruction in superficial femoral vein at colour Doppler.



**Figure 1 B.** Descending phlebography of the same extremity; profound collateral circulation and vein wall irregularities are seen.



**Figure 2 A.** Insufficiency in saphenous vein and superficial femoral vein at colour Doppler.



**Figure 2 B.** Descending phlebography of the same extremity.

Doppler and phlebography during Valsalva manoeuvre may lead to misdiagnose the degree of incompetence. This is also true because of the impossibility of making the tests during walking.

Masuda and Kistner in a comparative study of symptomatic and asymptomatic extremities found that the incompetence in thigh valves were the same in upright with 15 degree reverse Trendelenburg position, while making Valsalva manoeuvre using distal cuff<sup>17</sup>. It may seem to be more physiological to make measurements in an upright position, but the reliability of measurements under gravitational force without any affect of the muscle pump should be discussed.

Masuda suggested that the valves in the iliac veins are rather small, and not important that they could be neglected<sup>17</sup>. But we believe that only one good working valve is enough to adversely effect the result of a descending phlebography done from the contralateral femoral vein. For this reason phlebography was performed from the femoral vein of the limb involved.

In descending phlebography a good working valve is supposed to prevent the assessment of an incompetent valve distally, and contrast media by impinging to the obstructed segment may show an appearance of a competent valve<sup>2, 5, 18</sup>. However, if the aim is to restore a competent valve, the presence of one or more incompetent distal valves does not affect the surgical decision<sup>8-11, 19</sup>. Also the profound collateral circulation and irregular vascular images in the obstruction level helps to identify the appearance of a competent valve in descending phlebography. Descending phlebography is not the first step in diagnosis of CVI because it's invasive. Colour Doppler investigation done primarily can diagnose obstructions, and helps interpreting of the findings in descending phlebography.

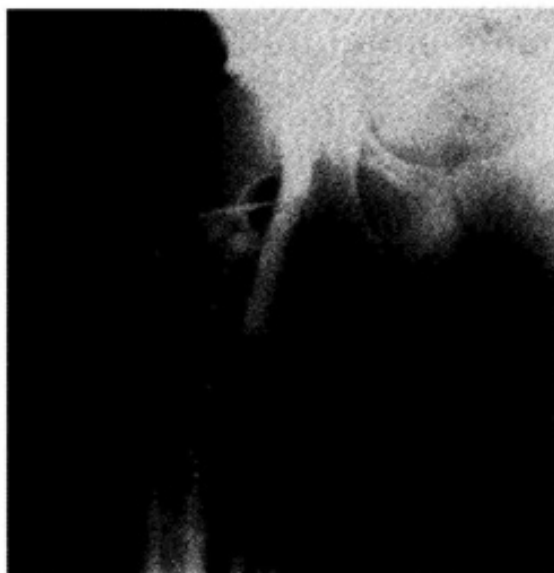Colour Doppler is a non invasive, practical, repeatable technique without any risks of complications, but it needs more expertise. Venous occlusion and valve incompetence can be diagnosed by colour Doppler, but visualisation of the deep femoral vein is rather harder<sup>2</sup>. We believe that it can not show incompetent valves in all levels, and can not

determine the pathologic anatomy of valves in detail. Baker et al suggests to use pneumatic tourniquet to assess the valves in all levels, but also blames that it is not accurate<sup>1</sup>.

Descending phlebography is a invasive method, may not be accepted by the patients because of known risks such as bleeding, haematoma, and allergic reactions due to contrast media. However it is the only method to assess the valvular anatomy and its details in today's circumstances<sup>3, 16, 18</sup>. In Neglen and Raju's words "Surgical treatment of valvular insufficiency is usually based on phlebographic findings<sup>18</sup>.

Today colour Doppler can give the answers to the 4 questions that should be asked in the CVI diagnosis<sup>12</sup>. We may say that coloured Doppler can diagnose CVI, define the cause and anatomical distribution and the grade of the reflux. But a good working valve can change the clinical situation in CVI and therefore valve resuspension is one of the surgical procedures that is most commonly used<sup>9-11</sup>. At this point any method determining accurately the pathologic anatomy and the level of the valve should be termed ideal. In these years that surgical therapy is applicable, another question must come to mind in terms of diagnostic procedure selection. And this should be; does it assess the pathologic anatomy accurately? This is possible with descending phlebography (Fig. 3).

Coloured Doppler should be applicated in all cases where CVI is suspected because it is noninvasive and easy to perform. Decision of surgical intervention can be taken according to Doppler because it is sufficient in diagnosis of CVI and obtaining the etiology and valvular incompetence level. Descending phlebography must be done to all patients needing operation to assess the pathologic anatomy of the valve and to select the surgical technique.



**Figure 3.** Mild insufficiency in superficial femoral vein at descending phlebography. The level and the pathological anatomy of the incompetent valve is seen.

### REFERENCES

1. Baker SR, Burnand KG, Sommerville KM, Thomas ML, Wilson NM, Browse NL: Comparison of venous reflux assessed by duplex scanning and descending phlebography in chronic venous disease. *Lancet* 1993;341:400-403.
2. Wiengarten MS, Branas CC, Czeredarczuk M, Schmidt JD, Wolferth CC: Distribution and quantification of venous reflux in lower extremity chronic venous stasis disease with duplex scanning. *J Vasc Surg* 1993;18:753-759.
3. Vasdekis SN, Clarke GH, Nicolaidis AN: Quantification of venous reflux by means of duplex scanning. *J Vasc Surg* 1989;10:670-677.
4. Porter JM, Rutherford RB, Clagett GP, Cranley JJ, O'Donnell TF, Raju S, Zierler RE, Browse N, Nicolaidis A: Reporting standards in venous disease. *J Vasc Surg* 1988;8:172-181.
5. Van Bemmelen PS, Bedford G, Beach K, Strandness DE: Quantitative segmental evaluation reflux with duplex ultrasound scanning. *J Vasc Surg* 1989;10:425-431.
6. Schanzer H, Peirce EC: A rational approach to surgery of the chronic venous stasis syndrome. *Ann Surg* 1982;195:225.
7. Welch HJ, Faliakou EC, McLaughlin RL, Umphrey SE, Belkin M, O'Donnell TF: Comparison of descending phlebography with quantitative photoplethysmography, plethysmography, and duplex quantitative valve closure time in assessing deep venous reflux. *J Vasc Surg* 1992;16:913-920.
8. Karagöz H, Sungün M, Kocailik A, Doğan N, Duran E: Kronik venöz yetmezliğin cerrahi tedavisinde ven kapağı onarımı, oluşturulması ve transplantı. *GKD Cerr Dergisi* 1992;1:186-191.
9. O'donnell TF Jr, Mackey WC, Shepard AD, et al: Clinical, hemodynamic and anatomic follow up of direct venous reconstruction. *Arch Surg* 1987;122:474-479.
10. Ferris EB, Kistner RL: Femoral vein reconstruction in the management of chronic venous insufficiency. A 14-year experience. *Arch Surg* 1982;117:157-163.
11. Taheri SA, Lazer L, Elias S: Status of vein valve transplant after 12 months. *Arch Surg* 1982;117:1313-1319.



12. Iafrati MD, Welch H, O'Donnell TF, Belkin M, Umphrey S, McLaughlin R: Classification of chronic venous insufficiency. *J Vasc Surg* 1994;19:1001-1007.
13. Labropoulos N, Leon M, Nicolaides AN, Giannoukas AD, Volteas N, Chan P: Superficial venous insufficiency. Correlation of anatomic extent of reflux with clinical symptoms and signs. *J Vasc Surg* 1994;20:953-958.
14. Shami SK, Sarin S, Cheattle TR, Scurr JH, Smith PDC: Venous ulcers and the superficial venous system. *J Vasc Surg* 1993;17:487-490.
15. Van Rij AM, Solomon C, Christie R: Anatomic and physiologic characteristics of venous ulceration. *J Vasc Surg* 1994;20:759-648.
16. Rosfors S, Bygdeman S, Nordström E: Assessment of deep venous incompetence. A prospective study comparing duplex scanning with descending phlebography. *Angiology* 1990;463-468.
17. Masuda EM, Kistner RL, Eklof B: Prospective study of duplex scanning for venous reflux: Comparison of Valsalva and pneumatic cuff techniques in the reverse Trendelenburg and standing positions. *J Vasc Surg* 1994;20:711-720.
18. Neglen P, Raju S: A comparison between descending phlebography and duplex Doppler investigation in the evaluation of reflux in chronic venous insufficiency: A challenge to phlebography as the "gold standard". *J Vasc Surg* 1992;16:687-693.
19. Karagöz H, Doğan N, Kocailik A, Süngün M, Duran E: Treatment of congenital venous avaluulosis using a surgically created autogenous vein valve. *Cardio Vasc Surg* 1993;1:131-133.