

# VASCULAR MANIFESTATION OF BEHÇET'S DISEASE: FEMORAL ARTERY ANEURYSM

M. DEĞERTEKİN MD,  
M. GENÇBAY MD,  
H. DRESKENELİ MD,\*  
Y. BAŞARAN, M.D.,  
İ. DİNDAR, M.D.,  
F. TURAN MD.

**From:** Koşuyolu Heart  
and Research Hospital,  
Kadıköy, İstanbul  
\* Marmara University  
Department of  
Rheumatology,  
İstanbul

*A 31-year-old male patient with Behçet's disease was admitted to the hospital with a right femoral artery aneurysm and previous complaints of oral ulcers.*

*With the presumptive diagnosis of right femoral artery aneurysm, immunosuppressive therapy was started, and the patient was followed in cardiology and rheumatology departments. Despite medical therapy, the aneurysm became larger. The patient's complaints has increased in past three months, and surgical resection was performed.*

*Nature of vascular involvement and femoral aneurysm in Behçet's disease is discussed.*

**Key words:** Behçet's disease, femoral artery aneurysm

**Address for  
reprints:**

Muzaffer Degertekin, MD  
Kosuyolu Heart and  
Research Hospital  
81020  
Kadıköy, İstanbul, Türkiye  
Phone: 90 216 326 69 69  
Fax: 90 216 339 04 41

**B**ehçet's disease, originally described by Dr. Hulusi Behçet in 1937, is a non-bacterial inflammatory disease that was initially defined by the presence of uveitis, aphthous stomatitis and genital ulcers (1). Now, it is regarded as a systemic vasculitis affecting both arteries and veins. Although cardiovascular involvement is rare in Behçet's disease, it has been considered as a major cause leading to fatal outcome. Here, we report a patient with Behçet's disease who had a large femoral artery aneurysm which was treated by surgical resection after two years of follow-up.

## CASE REPORT

A 31-year-old man was admitted to the cardiology department with a two yearly history of recurrent right swollen groin. Additionally, he had recurrent aphthous ulcers on the buccal mucosa. There was not any important complaints in his past history.

On his physical examination, there was a pulsatile mass on his right groin; in addition, there were scars of ulcers on the buccal mucosa. Two subcutaneous nodules (0.5 x 1 x 1 cm) was prominent on the extensor surface of the upper extremities. Physical examination revealed no signs of any other system involvement.

In laboratory examinations, C-reactive protein (CRP), anti-nuclear antibody (ANA), ASO, anti-DNA and RF were found to be negative. Sedimentation rate was 38 mm/h and HLA-B5 was positive. ECG and chest X ray were

normal. pathergy test was positive. Pulmonary function tests, lung perfusion scintigraphy, and transthoracic echocardiography demonstrated normal findings.

Coronary angiography, aortography and left ventriculography findings were in normal limits (Fig1A-B). Peripheral arterial angiography revealed a 5.2x3.8 cm aneurysm at the right common femoral artery (Fig 2). The distal angiographic pattern of the aneurysm and of the left femoral artery was normal.

The diagnosis of Behçet's disease was based on oral ulcers, positive pathergy test, peripheral arterial involvement and positive HLA- B5 tissue antigen.

immunosuppressive treatment was started immediately with cyclophosphamide. During first six months oral treatment was continued, later pulse intravenous cyclophosphamide therapy was given once a month for one year. At the follow-up examinations there was not any regression in size of the aneurysm.

In spite of immunosuppressive therapy, aneurysmatic mass became larger and the complaints of the patient increased. Surgical resection of the aneurysm was decided. Following the resection of the aneurysmatic common femoral artery, a synthetic vascular prosthesis (PTFE) was interposed. There was not any complication during surgery and hospital follow-up period. Before being discharged from the hospital, steroid and oral anticoagulation therapy was started. Two months after his operation, patient's clinical and physical examination revealed no complications.

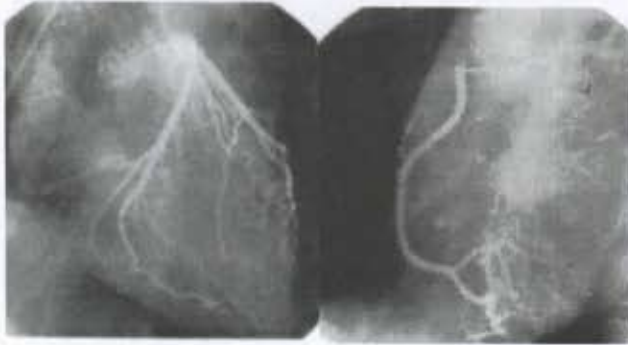


Fig 1 A. Normal coronary angiography.

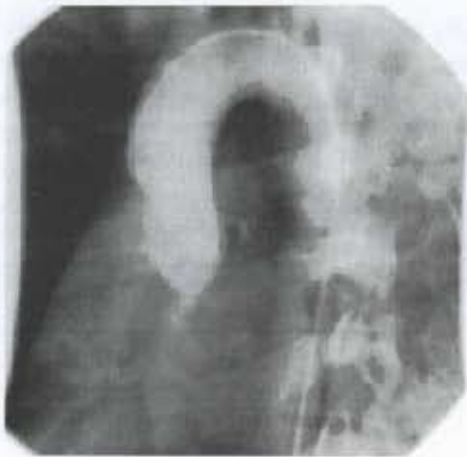

Fig 1 B. Aortographic image.

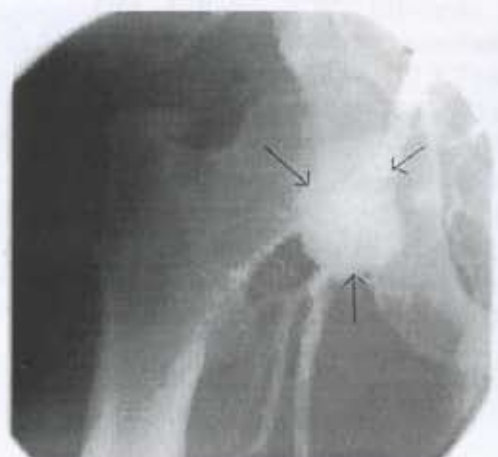

Fig 2. Right femoral artery aneurysm.

## DISCUSSION

Behçet's disease is characterised by coexistence of oral and genital ulcers associated with relapsing uveitis (2). It is more often in men than in women, the ratio being 2.3/1. Mean age range of onset is the third decade. Familial occurrence is rare, and it seems unlikely that genetic factors are important in development of the disease.

Clinical spectrum and severity depends on extension of vasculitis. It has been clearly shown that systemic vasculitis is related to both arterial and venous system. According to recent reports, manifestations of vascular pathologies were seen up to 1/3 of patients (3).

Previous reports demonstrated that rate of cardiovascular pathologies ranged from 7% to 29% in Behçet's disease (4-6). There is a consensus that major cause of death was related to manifestations of cardiovascular system.

Several theories have been developed to explain progression of aneurysm and thrombosis. Endothelial cell injury caused by immune complex deposit may induce impairment of fibrinolysis. Furthermore, microvascular thrombus formation is considered to be a result of endothelial cell ischemia which leads to aneurysm, and increased platelet aggregation (7-9).

There is no satisfactory treatment for Behçet's disease. Systemic administration of corticosteroids has been reported to cause some remission in symptoms. In recent years, treatment with immunosuppressive drugs was found beneficial in suppressing the inflammatory process. Other methods of treatment that were used with varying degrees of success include blood or plasma transfusions, and fibrinolytic drugs (phenformin and ethylestrenol). In the presence of arterial involvement and particularly of the aneurysm formation, long term results of surgical treatment are relatively poor; thus, surgery should be kept as a last chance for these patients (10,11).

In our patient, immunosuppressive therapy was given to suppress systemic inflammation and provide regression of aneurysm.

Throughout the immunosuppressive therapy, the symptoms did not change, and the femoral aneurysm's size became larger. Corticosteroid therapy was given before and after the surgery. This therapy might play an important role in prevention of postoperative complications which occur frequently, and may have an impact on prognosis. During the follow-up of our case, steroid and oral anticoagulation therapy was continued. Currently, the patient has no complaints since two months.

Our experience has shown that in spite of medical therapy, progression of a large aneurysm can not be prevented completely unless the aneurysm is surgically removed.

Observation of this case also revealed that temporary relief of symptoms should not mislead one into accepting adequacy of medical treatment. Timing and the necessity of surgical approach should be monitored by angiographic and sonographic guidance right from the start of early signs of cardiac involvement.

## REFERENCES

1. Behçet H: Uber rezidierende, apthoese, durch ein virus verursachte Geschwure am Mund, am Auge und an den Genitalien. *Dermatol Wochenschr* 1937; 105: 1152-1157.
2. Vanhalensey K, Ramahi KM, Hazmi M: Right atrial, right ventricular and left ventricular thrombi in (incomplete) Behçet's disease. *Eur Heart J* 1990; 11: 957-959.
3. Mendes LA, Magran L, Aldea GS: Right ventricular thrombosis: An unusual manifestation of Behçet's Disease. *J Am Soc Echocardiogr* 1994; 7: 438-440.
4. Wakabayashi Y, Tawarahara K, Kurata C: Aneurysms of all sinuses of valsalva and aortic valve prolapse secondary to Behçet's disease. *Eur Heart J* 1996; 17: 1766-1770.
5. James G, Thomson A: Recognition of the diverse cardiovascular manifestations in Behçet's disease. *Am Heart J* 1982; 103: 457-458.
6. Koc Y, Gullu I, Akpek G: Vascular involvement in Behçet's disease. *J*

- Rheumatol 1992; 19: 402-410.
7. Shmitz-Heubnex U, Knop J: Evidence for an endothelial cell dysfunction in association with Behçet's disease. *Thromb Res* 1984; 34: 277-285.
  8. Chajeh T, Aronowski E, Izak G: Decreased fibrinolysis in Behçet's disease. *Thromb Diath Hemorrh* 1973; 29: 610-618.
  9. Jordan JM, Allen NB, Pizzo SV: Defective release of tissue plasminogen activator in systemic and cutaneous vasculitis. *Am J Med* 1987; 34: 397-400.
  10. Sechas M, Laps C, Gougoulakis A: Vascular manifestation of Behçet's disease. *Int Angiology* 1989; 8: 145-150.
  11. Tüzün H, Sayın A, Karaözbek Y: Peripheral aneurysm in Behçet's disease. *Cardiovasc Surg*, 1993; 1:3, 220-224