

# DOUBLE-CHAMBERED RIGHT VENTRICLE AND MEMBRANOUS SEPTAL ANEURYSM

M. KAPLAN, MD,  
M. DEMİRTAŞ, MD,  
S. ÇİMEN, MD,  
H. SAYRAK, MD\*,  
B. KETENCİ, MD,  
Ö. TESKİN, MD,  
S. DAĞSALI, MD,  
T. TEZEL, MD,  
A. ÖZLER, MD

**From:**

Siyami Ersek Thoracic and  
Cardiovascular Surgery  
Center,  
Department of Pathology,  
Göztepe SSK Hospital,  
Istanbul, Türkiye

**Adress for  
reprints:**

Dr. Mehmet Kaplan  
67. Ada Kardelen 4-4  
D:11 81120 Ataşehir  
İstanbul, Türkiye  
Tel : +90 216 4557452  
Fax : +90 216 3379719

*Double-chambered right ventricle (DCRV) is an uncommon form of right ventricular obstruction. The differential diagnosis of DCRV from the other causes of right ventricular outflow tract obstruction is very important. Concomitant membranous ventricular septal defect is found in at least 80% of the patients. There may be an aneurysmatic pouch in the septum. We operated on a nineteen-year-old woman with a membranous septal aneurysm whose diagnosis was confirmed by the echocardiographic and angiographic findings. During the operation concomitant double-chambered right ventricle was detected. We performed the resection of anomalous fibrous and muscular bundles and patch closure of the resection of the ventricular septal defect using right atriotomy and right ventriculotomy, respectively. Postoperatively, direct pressure measurements revealed a gradient of 10 mm Hg between the two right ventricular chambers. No shunt was present on the interventricular septum.*

**Key words:** Double-chambered right ventricle, membranous septal aneurysm, right ventriculotomy, right ventricular outflow tract obstruction.

**D**ouble-chambered right ventricle (DCRV) is a division of the right ventricle into two chambers by a hypertrophied muscular bundle, usually located at the sinus-infundibulum junction, causing right ventricular outflow tract obstruction (1). It is an uncommon form of right ventricular outflow tract obstruction, accounting for 1-1.5 % of all congenital heart lesions (2).

Special attention should be given to the preoperative diagnosis of DCRV. If it is not considered as one form of pathology obstructing the right ventricular outflow tract, and if, during the operation, the opening in the right ventricle surrounded by muscle bundles is mistaken for ventricular septal defect (VSD) and closed with a patch, mortality ensues.

## CASE REPORT

A nineteen-year-old woman was admitted to our hospital with complaints of weakness and palpitation that occurred during physical activity since seven years of age. She has sought treatment at our hospital eight years ago, but an operation was not recommended because of the misinterpretation of very high right-sided pressures.

On physical examination, heart rate and blood pressure were measured as 78/min and 110/70 mm Hg, respectively. A systolic murmur was detected especially at the mesocardiac and pulmonary areas, being 3-4/6 in intensity.

Chest x-ray revealed increased vascularization especially in the hilar areas. Echocardiographic examination showed a pouch-like formation extending from the membranous ventricular septal defect to the right ventricle. The pressures in two separate locations of the right ventricle were measured as 80 mm Hg and 20 mm Hg, respectively. The diagnosis was a membranous septal aneurysm protruding into the right ventricle and causing obstruction of the right ventricular outflow tract (RVOT) and ventricular septal defect. During left ventricular angiography, a pouch-like image was formed by the opaque material passing from the membranous septum to the right ventricle (Fig. 1). An operation was planned with the diagnosis of ventricular septal defect and membranous septal aneurysm.

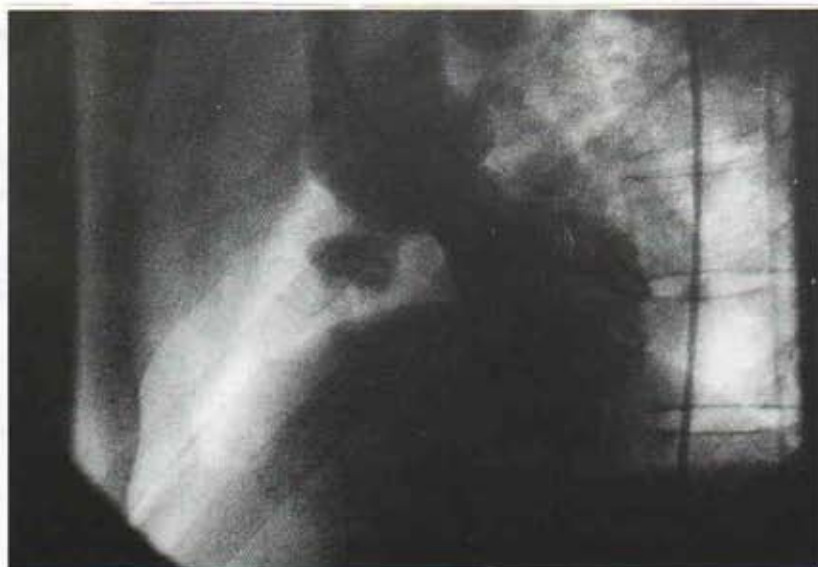## Operation Technique

Surgical correction was carried out via median sternotomy and standard cardiopulmonary bypass. Bicaval cannulation was performed and moderate hypothermia (28°C), cold K<sup>+</sup> cardioplegic arrest and external cooling were utilized.

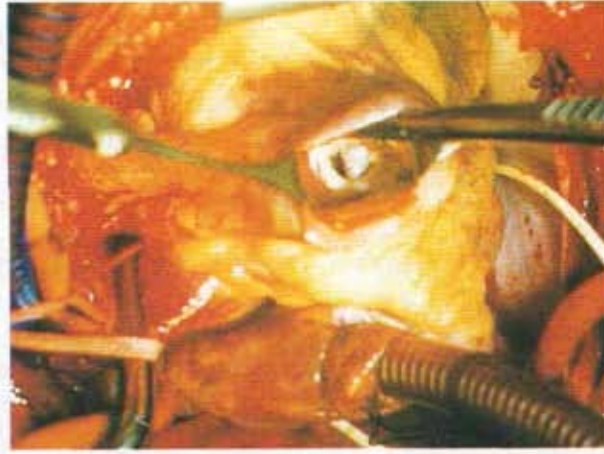Approach to the ventricular septal defect was made through right atriotomy. We observed the dissector advancing through the pulmonary artery from the open space which was thought to be the ventricular septal defect. Upon failure to reach VSD through right atriotomy, right ventriculotomy was performed at the RVOT. In the right ventricle, a smooth-edged fibrotic open space with a diameter of 1 cm obstructing the right ventricular outflow tract, was found. The space was surrounded by hypertrophic and anomalous muscle bundles.

This open space separated the inflow and outflow portions of the right ventricle. We were unable to observe the RVOT and pulmonary trunk via right atriotomy, nor the tricuspid valve and its subvalvular apparatus were visible through right ventriculotomy. A perimembranous ventricular septal defect was present in the inflow portion of the right ventricle, adjacent to the septal leaflet of the tricuspid valve.

Anomalous bundles and fibrotic tissues were resected, preserving the moderator band. The right ventricular cavity was enlarged, allowing a 20 mm dilatator to pass. The pulmonary



**Fig. 1.** Preoperative left ventriculography of the patient showing a ventricular septal defect with an aneurysmal formation of the septum.



**Figure 2.** Operative view showing a muscular diaphragm in the right ventricle with an orifice of 10 mm lined with white fibrous tissue.

cusps and pulmonary artery were of normal width and structure. Ventricular septal defect was closed via right atriotomy using a Gore-Tex patch (Fig. 2).

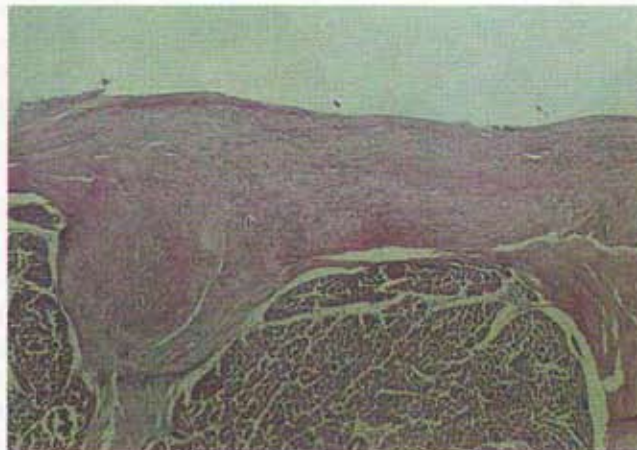
The right atrium and right ventricle were closed. Cross-clamp was taken off and cardiopulmonary bypass was terminated when normal temperature and pressure levels were attained. Direct pressure measurements revealed a 10 mm Hg gradient between the proximal and distal right ventricular chambers. No shunt was detected in oxygen saturations. The duration of cross-clamp and cardiopulmonary bypass were 97 and 120 minutes, respectively.

The patient was extubated at the postoperative 8th hour. Her hemodynamic state was stable. In the postoperative second day, she was discharged from the intensive care unit.

Control echocardiographic examinations were made. Right ventricular pressure was 25 mm Hg and there was no gradient between the right ventricle and pulmonary artery. A laminary flow was found in the pulmonary artery. There was no passage from the interventricular septum. The patient was discharged from hospital with penicillin prophylaxis on the postoperative 8th day.

### **Pathologic Findings**

Pathologic examination of the resected specimen using hematoxylin-eosin (x100) revealed thickened endocardium with abundant collagenous and elastic fibers running parallel to the surface. No fibrosis of the subendocardial myocardium was present (Fig. 3).



**Figure 3.** Thickened endocardium with abundant collagenous and elastic fibers (hematoxylin-eosin, x100).

## DISCUSSION

Right ventricular outflow obstructions arise due to various factors including malposed infundibular hypertrophy (tetralogy type), anomalous right ventricle muscle bundles, membranous septum "wind sock" aneurysm (3), accessory tricuspid leaflet, subpulmonary fibrous diaphragm (4,5,6), and neoplasms.

Double-chambered right ventricle was first described by Lucas et al. in 1962 (7) as a distinct anatomic entity of RVOT obstruction resulting from anomalous muscle bundles in the subinfundibular position. These authors reported two cases in which failure to recognize the nature of the obstruction resulted in an inadequate surgical treatment and mortality.

There are two chambers, the pressures being high in the proximal chamber and normal in the infundibular cavity, respectively. The right ventricular infundibulum and pulmonary valve are not stenotic, differentiating DCRV from RVOT obstruction seen in the Tetralogy of Fallot.

Obstructing muscle bundles should be distinguished from the moderator band. Anomalous muscles and bundles may originate from the septoparietal complex distant from the moderator band (8). In addition, superior and posteromedial malposition of the moderator band and its eventual hypertrophy may be the principal morphology of this lesion (9,10). On the other hand, a non-obstructive anomalous muscle may become obstructive in time (1).

Fellows et al. (11), in a series of 24 patients with DCRV, reported a rate of 85% for ventricular septal defect, two of which were associated with membranous septal aneurysm formation.

There may be various cardiac anomalies such as VSD (80-95%), pulmonary valvular stenosis (33%) (12), discrete subaortic stenosis (13,14,15), coronary artery anomalies (single coronary artery) (16), and double outlet right ventricle (17,18,19).

Wong and associates (20) reported that development of DCRV in patients with a VSD

was unclear and, among patients with a membranous VSD, approximately 3% had concomitant DCRV. Simpson et al. (12) reported the incidence of DCRV as 10-11% in patients undergoing surgery for a VSD.

The embryogenic mechanism of the DCRV-VSD relationship is unclear. However, improper expansion of the bulboventricular junction may result in incomplete fusion of the bulbar and endocardial cushion elements that normally close the superior position of the ventricular septum (10).

Perloff and associates (14) described two types of subinfundibular obstruction in 1965, caused by hypertrophy of the oblique component of normal bulbar muscle adjacent to the trabecula septomarginalis and by hypertrophy of abnormal muscle groups, respectively (2,8,14). Sector echocardiography and subcostal imaging and transesophageal echocardiography are of great value in diagnosis and pulsed Doppler ultrasonography may reveal turbulent flow in the RVOT (9,21). Cardiac catheterization and angiography are essential in visualizing the proximal and distal right ventricular chambers and in detecting pressure gradients. By withdrawing the catheter in the pulmonary artery, normal pressure in the distal chamber and then the increased pressure in the proximal chamber can be detected (11).

Anomalous band resection should be performed using right ventriculotomy (22). Should concomitant VSD be present, the closure can be carried out via right atriotomy (23). Resection of anomalous muscle bundles requires the preservation of the moderator band and mobilization of the septal and parietal bands with special attention being given to the tricuspid valve's papillary muscles.

In conclusion, preoperative diagnosis of DCRV is of particular significance and it should be differentiated from the other causes of right ventricular outflow tract obstruction. Accurate pre-surgical detection of DCRV and associated anomalies may lead to an improved surgical outcome and may help surgeons avoid unexpected adverse events.

## REFERENCES

1. Matina D, Van doesburg NH, Fauron JF, Guerin R, Davignon A. Subxiphoid two-dimensional echocardiography diagnosis of double-chambered right ventricle. *Circulation* 1983;67:885-8.
2. Hartmann AF, Goldring D, Ferguson TB, et al. The course of children with the two-chambered right ventricle. *J Thorac Cardiovasc Surg* 1970;60:72-83.
3. Cosio F, Wang Y, Nicoloff DM. Membranous right ventricular outflow obstruction. *Am J Cardiol* 1973;32:1000-3.
4. Gomes AS, Nath PH, Singh A, et al. Accessory flap like tissue causing ventricular outflow obstruction. *J Thorac Cardiovasc Surg* 1980;80:211-6.
5. Jain V, Subramanian DCH, Lambert EC. Concomitant development of infundibular pulmonary stenosis and spontaneous closure of ventricular septal defect. *Am J Cardiol* 1969;24:247-54.
6. Pate JW, Richardson RL, Giles HH. Accessory tricuspid leaflet producing right ventricular outflow tract obstruction. *N Engl J Med* 1968;279:867-88.
7. Lucas RV Jr, Varco RL, Lillehei RW, et al. Anomalous muscle bundle of the right ventricle. Hemodynamic consequences and surgical considerations. *Circulation* 1962;25:443-55.
8. Hartman AF Jr., Goldring D, Carlsson E. Development of right ventricular obstruction by aberrant muscular bands. *Circulation* 1964;30:679-85.
9. Shimada R, Tajimi T, Koyanagi S, et al. Two-dimensional echocardiographic findings in double chamber right ventricle. *Am Heart J* 1984;108:1059-61.
10. Rowland TW, Rosenthal A, Castenada AR. Double chamber right ventricle. Experience with 17 cases. *Am Heart J* 1975;89:455-62.
11. Fellows KE, Martin EC, Rosenthal A. Angiographic view of obstructing muscle bands of the right ventricle. *Am J Roentgenol* 1977;128:249-56.
12. Simpson WF, Sade RM, Crawford FA, Taylor AB, Fyle DA. Double chambered right ventricle. *Ann Thorac Surg* 1987;44:7-10.
13. Coates JR, McClenathan JE, Scott LP. The double-chambered right ventricle : a diagnostic and operative pitfall. *Am J Cardiol* 1964;14:561-7.
14. Perloff JK, Ronan JA, De Leon AC. Ventricular septal defect with the two-chambered right ventricle. *Am J Cardiol* 1965;16:894-900.
15. Baumstark A, Fellows KE, Rosenthal A. Combined double-chambered right ventricle and discrete subaortic stenosis. *Circulation* 1977;57:299-302.
16. Blasetto JW, Donahov JS, Shuck JW. Single coronary artery in association with anomalous right ventricular muscle bundles. *Am Heart J* 1988;115:1122-3.
17. Judson JP, Danielson GK, Ritter DG, Hagler DJ. Successful repair of coexisting double-outlet right ventricle and two chambered right ventricle. *J Thorac Cardiovasc Surg* 1982;84:113-21.
18. Singh M, Agarwala MK, Grover A, Pathak V, Varma JS. Clinical, echocardiographic, and angiographic profile of patients with double-chambered right ventricle : experience with 48 cases. *Angiology* 1999;50:223-31.
19. Chang RY, Kuo CH, Rim RS, Chou YS, Tsai CH. Transoesophageal echocardiographic image of double-chambered right ventricle. *J Am Soc Echocardiogr* 1996;3:347-52.
20. Wong PC, Sanders SP, Jonas RA, et al. Pulmonary valve-moderator band distance and association with development of double-chambered right ventricle. *Am J Cardiol* 1991;68:1681-6.
21. Çil E, Saraçlar M, Özkutlu S, et al. Double-chambered right ventricle: experience with 52 cases. *Int J Cardiol* 1995;50:19-29.
22. Penkoske PA, Duncan N, Collius-Nakai RL. Surgical repair of double-chambered right ventricle with or without ventriculotomy. *J Thorac Cardiovasc Surg* 1987;93:385-93.
23. Ford DK, Bullaboy CA, Derkac WM, et al. Transatrial repair of double-chambered right ventricle. *Ann Thorac Surg* 1988;45:412-5.