

ANATOMIC BASIS FOR MITRAL REMODELING AND EVALUATION OF THE LONG-TERM OUTCOMES OF MITRAL REPAIR

M. BALKANAY, MD,
N. ULUSOY BOZBUĞA,
MD,
E. AKINCI, MD,
R. DAĞLAR, MD,
G. İPEK, MD,
Ö. İŞİK, MD,
C. YAKUT, MD

From: Department of
Cardiovascular Surgery,
Koşuyolu Heart and
Research Hospital, İstanbul,
Türkiye

**Address for
reprints:**

Dr. Nilgün Ulusoy Bozbuğa
Koşuyolu Kalp ve
Araştırma Hastanesi
S1020 Koşuyolu, İstanbul,
Türkiye
Tel: +90 216 3266969
Fax: +90 216 3390441
e-mail:
kosuyolu@superonline.com

Out of a wide spectrum, this study presents our institutional early and late results of 753 patients who have undergone mitral valve reconstruction in the period between 1985 and 2000. There were 536 female (71.2%) and 217 male (28.8%) patients, mean age was 36.4 years ranging between 3-72. The etiological factors were recognized as rheumatic valvular disease in 80.8%, degenerative mitral valve disease in 8.2%, congenital valve disease in 6.3%, ischemic mitral valve disease in 4.7% of the patients. The preoperative diagnosis was predominant stenosis in 135 cases (17.93%), predominant regurgitation in 271 cases (35.98%), and mixed lesion in 347 cases (46.08%). According to NYHA classification, most of the patients were in class III. Mitral valve findings determined the type of mitral surgery. Mitral valvuloplasty techniques consisted of annuloplasty in 375 patients (prosthetic ring annuloplasty in 89, Kay annuloplasty in 117, Wooler annuloplasty in 108, and other kinds of modified annuloplasty techniques in 61), augmentation of the mitral leaflets in 105 patients (the extension of the posterior leaflet with autologous pericardium in 49, and repair of the mitral cleft in 56), release of retracted subvalvular apparatus in 418 patients (commissurotomy, splitting of chordae tendineae and/or papillary muscles, resection of secondary chordae tendineae, fenestration of fused chordae), restriction of increased mitral valve mobility in 43 patients (the quadrangular resection of anterior leaflet in 22, shortening of elongated chordae in 32, chordoplasty in 16). Simultaneous aortic valve surgery was performed in 160 of the cases with aortic reconstruction in 62 patients. 114 patients underwent tricuspid valve repair associated with mitral valvuloplasty.

The operative mortality was 0.66% and the hospital mortality was 1.81%. The reoperation rate for mitral valve insufficiency or restenosis was 12.5% in 94 patients. A complete follow-up was available in 78.1% of the patients with a mean observation time of 49.2 months (2410.8 patient-years).

According to our institutional policy, mitral valvuloplasty should be tried if possible because of its more physiological approach and its potential to improve long-term results. These experiences indicated that mitral reconstruction procedures were effective surgical approaches in repairing the valves that otherwise would need to be replaced.

Key words: Mitral remodeling, mitral repair, mitral valve

Since the first successful repair of regurgitant mitral valve by annulus plication under direct vision was reported by Lillehei and associates (1) in 1957, with an increasing understanding of the pathophysiologic mechanisms of the diseased valve, the attention has been focused on reconstructive surgery for acquired valvular disease. An essential component of valve repair is remodeling the mitral valve. The aim of the reconstruction of mitral valve is to restore not only normal valve anatomy but also optimal valve function in all components of the mitral valve apparatus, rather than in the annulus alone.

Out of a wide spectrum, this study presents our institutional early and late results of 753 patients who have undergone mitral valve reconstruction in the period between 1985 and 2000.

PATIENTS AND METHOD

From 1985 to 2000, 753 patients with mitral valve disease had mitral repair procedures to obtain optimal valve function. The age of the patients ranged from 3-72 (mean 36.4), 536 patients were female (71.2%), 217 patients were male (28.8%). Most of the patients were in class III according to the NYHA classification. 393 patients (52.2%) were in normal sinus rhythm, 360 patients (47.8%) were in atrial fibrillation. The etiological factors were recognized as rheumatic valvular disease in 608 patients (80.8%), degenerative mitral valve disease in 62 patients (8.2%), congenital valve disease in 48 patients

(6.3%), ischemic mitral valve disease in 35 patients (4.7%). The preoperative diagnosis was predominant stenosis in 135 cases (17.93%), predominant regurgitation in 271 cases (35.98%), and mixed lesion in 347 cases (46.08%). Patient characteristics are summarized in Table 1.

Accurate valve analysis was achieved by transthoracic echocardiography (TTE), additionally by transesophageal echocardiography (TEE) in most of the patients before the operation, and by controlling with fluid under direct inspection and TEE during the operation and also valve competence was evaluated in fibrillation just after cross-clamp releasing.

The mitral valve findings determined the type of mitral surgery. Mitral valvuloplasty techniques consisted of annuloplasty in 375 patients (prosthetic ring annuloplasty in 89, Kay annuloplasty in 117, Wooler annuloplasty in 108, and other kinds of modified annuloplasty techniques in 61), augmentation of the mitral leaflets in 105 patients (the

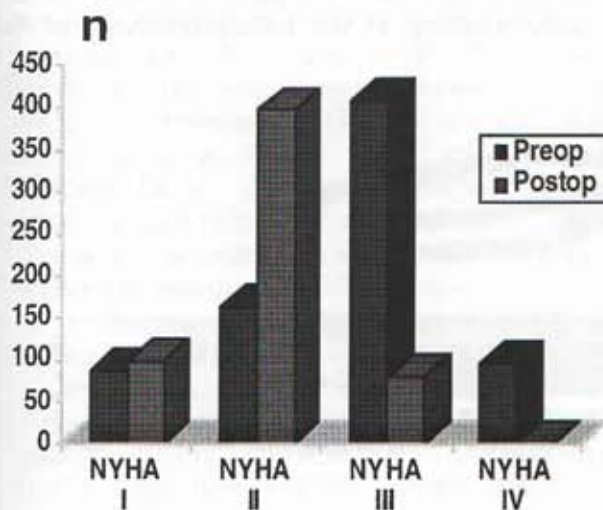
Table 1. Patient characteristics

	n	(%)	Age	Range
Total	753	100	36.4	(3-72)
Sex				
Female	536	71.2	34.2	(7-66)
Male	217	28.8	37.5	(3-72)
Etiology				
Rheumatic	608	80.8	37.2	(13-59)
Degenerative	62	8.2	58.1	(33-72)
Congenital	48	6.3	12.2	(3-53)
Ischemic	35	4.7	59.3	(52-61)
Diagnosis				
Stenosis	135	17.9		
Regurgitation	271	36.0		
Mix	347	46.1		
Pathology				
Isolated	536	71.2		
Mitro-Aortic	160	21.5		
Triple	77	10.3		
ECG				
SR	393	52.2		
AF	360	47.8		

Table 2. Type of valvuloplasty

	n
Annular Procedures	
Annuloplasty	
Ring	89
Kay	117
Wooler	108
Modified	61
Total	375
Augmentation of leaflets	
Cleft repair	55
Posterior leaflet extension	49
Anterior leaflet patching	1
Total	105
Release of subvalvular apparatus	
Commissurotomy	418
Splitting	
Papillary muscles	388
Chordae tendineae	290
Fenestration	66
Total	418
Restriction of leaflet mobility	
Quadrangular resection	22
Shortening	32
Chordaplasty	16
Total	62

extension of the posterior leaflet with autologous pericardium in 49, and repair of the cleft in 55), the release of retracted subvalvular apparatus in 418 patients (commissurotomy, splitting of chordae tendineae and/or papillary muscles, resection of secondary chordae tendineae, fenestration of fused chordae), the restriction of increased

**Figure 1.** Pre- and postoperative classification of the patients according to NYHA

mitral valve mobility in 43 patients (the quadrangular resection of anterior leaflet in 22, the shortening of elongated chordae in 32, chordaplasty in 16). Most of the patients had more than one maneuver to attain competence (mean 1.3). Mitral valvuloplasty techniques are summarized in Table 2.

Simultaneous aortic valve surgery was performed in 160 of the cases with aortic reconstruction in 62 patients. 114 patients underwent tricuspid valve repair (tricuspid DeVega annuloplasty in 103, tricuspid valve commissurotomy in 28) associated with mitral valvuloplasty.

Statistical Analysis

The data collection methodology and data analysis strategy for mitral valve operations were applied according to the Koşuyolu Heart and Research Hospital practice (2).

Patients' events were tabulated according to the set of definitions provided in the "Guidelines for Reporting Morbidity and Mortality After Cardiac Operations"(3, 4). The occurrence of clinical outcomes during follow-up period was evaluated by using Kaplan-Meier survival curves.

RESULTS

The operative mortality was 0.66% out of 753 patients (5 patients) and the hospital mortality was 1.81% (14 patients). Eleven thromboembolic events were recorded in patients whose heart rhythm were atrial fibrillation and who had left atrial thrombus before the operation.

Patients' functional status was evaluated pre- and post-operatively (Figure 1).

The reoperation rate for mitral insufficiency and/or restenosis was 12.5% (94 patients). In 8 patients, the mitral valve was repaired again. In the remaining patients, prosthetic valve replacement was performed (Figure 2).

A complete follow-up was available in 78.1% of the patients with a mean observation time of 49.2 months, ranging between 9-129 months (2410.8 patient-years).

5-year survival rate was 98.1% in our series.

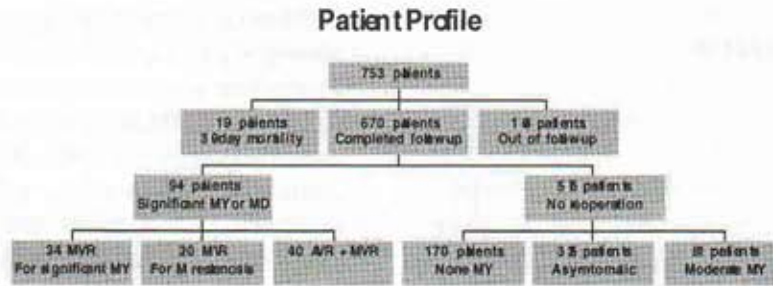


Figure 2. Results of mitral valvuloplasty

Actual 5-year thromboembolism-free rate was 96.8% and 5-year reoperation-free rate was 89.7% (Figure 3).

Anticoagulation was used in patients who were in atrial fibrillation. The other patients received low-dose aspirin therapy.

DISCUSSION

With an increasing awareness of limitations of both mechanical prostheses and bioprostheses, attention has been refocused on valvuloplasty because of its being a more physiologic approach and its potential to improve long-term results. Mitral valve replacement in the young age group and particularly in women of child-bearing age, still presents a serious problem in terms of anticoagulation and limited durability of the bioprosthesis. Fundamental techniques of valve repair for mitral valve disease have been well

established during the past twenty years (5-8). Valvuloplasty for mitral regurgitation has clear advantages over prosthetic replacement. All repair procedures carry a low operative risk. The operative mortality rate for mitral valve repairs was 0.66% in our series. Late survival rate after mitral valve repair is improved with respect to that of mitral valve replacement (9).

The incidence and cause of the failure of mitral valvuloplasty vary according to the cause of mitral valve disease. The estimated reoperation rate for mitral valve repair during a five-year interval is 10.3%, although we cannot be certain that all patients undergoing reoperation returned to our clinic.

Reconstructive mitral valve surgery should be considered for the patients in whom the appropriate techniques were able to be applied in accordance with the intraoperative findings. More sophisticated approaches based on understanding of the pathophysiology of the




Figure 3. Actuarial survival of the patients

diseased mitral valve and better knowledge of reconstructive surgery will result in a better operative outcome, as well as the application of valvuloplasty to an expanded population of patients.

From Koşuyolu Heart and Research Hospital, a preliminary report on mitral valvuloplasty has appeared in 1987 (10). Increasing mitral valvuloplasty cases in which fundamental reconstruction techniques were applied were reported in several other times (11,12).

Mitral disease's characteristic of being a multifactorial pathology was stressed by the other authors as well (13,14). Our experience confirmed that in merely 10% of the patients annular dilatation was the sole cause of mitral regurgitation. Chordal abnormalities (thickening/shortening, elongation, or rupture) and leaflet pathologies were observed to be responsible in a high percentage of the patients (15-17). It seemed that performing a comprehensive valvuloplasty (other than annuloplasty) had a compelling logic. Many aspects of valvuloplasty technique were adapted or modified to suit the characteristics of the population (17-21). New techniques were evolved and others were used with indications different from those originally intended.

In most reported series, the possibility of successful repair did not exceed 85%. This is generally due to inherent complexity of the combined lesion which involves all parts of the mitral apparatus (15,16). There were some presented commissural fusion cases that required opening to improve cuspal mobility, even in rheumatic lesions. A pliable anterior leaflet was the most important condition for an adequate valvuloplasty (22). Also a rigid and small posterior leaflet was relatively an adverse factor. A careful analysis of the anatomic and functional status of mitral valve lesion was necessary to ensure that a relevant repair was performed in each lesion.

A restrictive element represents a more difficult repair problem compared to dilatation or elongation. In our experience of valve repair in rheumatic valvular disease, the patients usually had retraction of the posterior leaflet with short, fibrotic chordae tendineae. In case the leaflet tissue is lacking, mobilization by resection of the secondary

chordae and fenestration of the marginal chordae are not enough to obtain adequate coaptation. Patch enlargement provides a better mobilization of the posterior leaflet tissue, a large surface of coaptation, less turbulence, a lesser degree of residual stenosis (23).

By contrast, in developing countries, the patients with rheumatic mitral valve disease are much older like they were in our series. The results of valvuloplasty are much better here, obviously because the pathologic process is more stable and the patients are not subjected to reinfection (24).

The presence of severe dysfunction of the left ventricle did not preclude valvuloplasty where the subvalvular mechanism is preserved. On the other hand, poor left ventricular function increases the likelihood of embolism from the prosthetic valve (25, 26). Hence, we no longer consider a poor left ventricle to be a contraindication to valvuloplasty.

Early failure of mitral valve repair is probably due to technical factors (27). Valvular failure may also have resulted from poor patient selection or inadequate intraoperative assessment of mitral valve function after the repair (28, 29, 30). Using intraoperative transesophageal echocardiography to assess the repaired mitral valve will be a factor in diminishing incidence of early failure in mitral valve repair.

CONCLUSION

We concluded that valve repair for mitral valve disease was associated with better long-term survival and left ventricular performance, as well as lower thromboembolic and anticoagulant-related hemorrhagic complications compared to mitral valve replacement with a mechanical prosthesis. Our institutional policy is that mitral valvuloplasty should be tried if possible because of its being a more physiological approach and its potential to improve long-term results. These experiences indicated that mitral reconstruction procedures are effective surgical approaches in repairing the valves that otherwise would need to be replaced.

REFERENCES

1. Lillehei CW, Gott VL, Wall RA, Vargo RL. Surgical correction of pure mitral insufficiency by annuloplasty under direct vision. *Lancet* 1957;77:446-9.
2. Bozbuğa N, Işık Ö, Berki T, Yakut C. The database formation and statistical modeling for valvular operations at Koşuyolu Heart and Research Hospital. *Koşuyolu Heart J* 1997;2:156-163.
3. Edmunds LH, Clark RE, Cohn LH, Miller DC, Weisel RD. Guidelines for reporting morbidity and mortality after cardiac valvular operations. *J Thorac Cardiovasc Surg* 1988;96:351-3.
4. Edmunds LH Jr, Clark RE, Cohn LH, Grunkemeier GL, Miller DC, Weisel RD. Guidelines for reporting morbidity and mortality after cardiac valvular operations. *Ann Thorac Surg* 1996;62:932-5.
5. Carpentier A. Cardiac valve surgery-the "French Correction." *J Thorac Cardiovasc Surg* 1983;86(3):323-37.
6. Deloch A, Jebara VA, Relland JY, Chauvaud S, Fabiani JN, Perier P, Dreyfus G, Mihaileanu S, Carpentier A. Valve repair techniques. The second decade. *J Thorac Cardiovasc Surg* 1990;99(6):990-1002.
7. Chauvaud S, Jebara VA, Chachques JC, el Asmar B, Mihaileanu S, Perier P, Dreyfus G, Relland J, Couetil JP, Carpentier A. Valve extention with glutaraldehyde-preserved autologous pericardium. Results in mitral valve repair. *J Thorac Cardiovasc Surg* 1991;102(2):171-8.
8. Bernal JM, Rabasa JM, Olalla JJ, Carrion MF, Revuelta JM. Repair of chordae tendinea for rheumatic mitral valve disease. A twenty-year experience. *J Thorac Cardiovasc Surg* 1996;111:211-7.
9. Fernandez J, Joyce DH, Hirschfeld KJ, Chen C, Yang SS, Laub GW, Adkins MS, Anderson WA, Mackenzie JW, McGrath LB. Valve-related events and valve-related mortality in 340 mitral valve repairs. A late phase follow-up study. *Eur J Cardiothorac Surg* 1993;7:263-70.
10. Işık Ö. Reconstructive surgery in mitral valve disease. Unpublished specialization thesis in cardiovascular surgery, Koşuyolu Heart and Research Hospital, İstanbul, 1987.
11. Işık Ö, Balkanay M, Zeybek R, Bayezid Ö, Yakut C. Clinical results of the mitral valve. *Vascular Surg* 1991;25:595-9.
12. İpek G, Gürbüz A, Erdinç M, Berki T, Işık Ö, Yakut C. Clinical results of mitral valve reconstruction. *Koşuyolu Heart J* 1993;2:38-42.
13. Luxereau P, Dorent R, Gevigney G, Bruneval P, Chomette G, Delahaye G. Aetiology of surgically treated mitral regurgitation. *Eur Heart J* 1991;12(Suppl B):2-4.
14. Bashour TT, Andreae GE, Hanna ES, Mason DT. Reparative operations for mitral valve incompetence: An emerging treatment of choice. *Am Heart J* 1987;113:1199-1206.
15. Antunes MJ, Magalhaes MP, Colsen PR, Kinsley RH. Valvuloplasty of rheumatic mitral valve disease. A surgical challenge. *J Thorac Cardiovasc Surg* 1987;94:44-56.
16. Lessana A, Carbone C, Romano M, Palsky E, Quan Y H, Escorsin M, Jegier B, Ruffenach A, Lutfalla G, Aime F, Guerin F. Mitral valve repair: results and the decision-making process in reconstruction. Report of 275 cases. *J Thorac Cardiovasc Surg* 1990;99:639-44.
17. Skoularigis J, Sinovich V, Joubert G, Sareli P. Evaluation of the long-term results of mitral valve repair in 254 young patients with rheumatic mitral regurgitation. *Circulation* 1994;90(Part 2):167-74.
18. Scrofani R, Morigga S, Salati M, Fundaro P, Danna P, Santoli. Mitral valve remodelling: long-term results with posterior pericardial annuloplasty. *Ann Thorac Surg* 1996;61:895-9.
19. Kalil RA, Lucchese FA, Prates PR, Santana JRM, Faes FC, Pereria E, Nesralla IA. Late outcome of unsupported annuloplasty for rheumatic mitral regurgitation. *J Am Coll Cardiol* 1993;22:1915-20.
20. Duran CG, Revuelta JM, Gaité L, Alonso C, Fleitas MG. Stability of mitral

- reconstructive surgery at 10 to 12 years for predominantly rheumatic valvular disease. *Circulation* 1988;78(Suppl 2):91-6.
21. Bernal JM, Rabasa JM, Vilchez FG, Cagigas JC, Revuelta JM. Mitral valve repair in rheumatic disease. The flexible solution. *Circulation* 1993;88(4 Pt 1):1746-53.
 22. Grossi EA, Galloway AC, Leboutiller III M, Steinsberg B, Baumann FG, Delianides J, Spencer FC, Colvin SB. Anterior leaflet procedures during mitral valve repair do not adversely influence long-term outcome. *J Am Coll Cardiol* 1995;25:134-6.
 23. Bozbuğa N, Mansuroğlu D, Işık Ö, Berki T, Gürbüz A, Balkanay M, İpek G, Dağlar B, Yakut C. Mitral posterior leaflet extension. *Cor Europeum* 1997;6:78-81.
 24. Kumar AS, Rao PN, Saxena A. Results of mitral valve reconstruction in children with rheumatic heart disease. *Ann Thorac Surg* 1995;60:1044-7.
 25. David TE, Komeda M, Pollick C, Burns RJ. Mitral valve annuloplasty: the effect of the type of left ventricular function. *Ann Thorac Surg* 1989;47:524-8.
 26. Gams E, Schad H, Heimisch W, Hagl S, Mandler N, Sebinig F. Importance of the left ventricular apparatus for cardiac performance. *J Heart Valve Dis* 1993;2:642-5.
 27. Cerfolio RJ, Orszulak TA, Pluth JR, Harmsen WS, Schaff HV. Reoperation after valve repair for mitral regurgitation: early and intermediate results. *J Thorac Cardiovasc Surg* 1996;111:1117-84.
 28. Turner E, Wisenbaugh T, Sinovich V, Cronje S, Sareli P. Morphologic patterns in patients undergoing reoperation after repair of rheumatic mitral regurgitation. *Am J Cardiol* 1993;71:455-7.
 29. Antunes MJ. Reoperation after repair of rheumatic mitral regurgitation. *Am J Cardiol* 1994;74:722-3.
 30. Fednandez J, Joyce DH, Hirschfeld K, Chen C, Laub GW, Adkins MS, Anderson WA, Mackenzie JW, McGrath LB. Factors affecting mitral valve reoperation in 317 survivors after mitral valve reconstruction. *Ann Thorac Surg* 1992;54:440-8.