

ACCESSORY MITRAL VALVE TISSUE CAUSING OUTFLOW TRACT OBSTRUCTION: CASE REPORT

H. BİNGÖL, MD,
M.H. US* , MD,
A.T. YILMAZ, MD,
M. UZUN, MD,
H. TATAR, MD

From:

Gülhane Military Medical
Academy, Department of
Cardiovascular Surgery
Etlik-Ankara/Türkiye
* Gülhane Military Medical
Academy, Haydarpaşa
Training Hospital
Department of
Cardiovascular Surgery
İstanbul/Türkiye

Several congenital mitral valve abnormalities may cause left ventricular outflow tract obstructions. Echocardiography and angiography demonstrated accessory mitral valve tissue in 5 patients. Associated lesions included ventricular septal defect (VSD) in two patients, aortic insufficiency (AI) in two patients and mitral insufficiency (MI) in 3 patients. In all patients the accessory valve tissue causing outflow tract obstruction was excised. Additionally VSD were repaired with Gore-tex patch in two patients, myectomy in three patients and mitral valve replacement in one patient. Accessory mitral tissue may cause a dynamic obstruction. The differential diagnosis of accessory mitral valve tissue is important from the reasons of fixed gradient associated with IHSS.

Key words: Accessory mitral valve tissue, left ventricular outflow tract obstruction

Left ventricular outflow tract obstruction (LVOTO) occurs due to several types of congenital abnormalities. Several mitral valve abnormalities such as the prolapse of redundant chordae or leaflets or accessory mitral valve tissue are rare causes of LVOTO (1). Three types of congenital mitral valve abnormalities may cause LVOTO: i) abnormal attachment of the anterior leaflet of the mitral valve to the ventricular septum, ii) parachute mitral valve, iii) accessory mitral valve tissue (2). The clinical features of the accessory mitral valve is less known and may be associated with other congenital cardiac abnormalities. In this study we present our experience in 5 patients.

PATIENT AND METHODS

Between 1997 and 2001, 5 patients were admitted with complaints of chest pain and dyspnea. The patients' clinical features were determined in Table I.

Case 1. A 20 year old man was admitted in May 1997. A systolic ejection murmur of grade 3/6 was present at the mid-left sternal edge. Echocardiography and catheterization revealed an inlet type

Adress for

reprints:

Dr. Hakan BİNGÖL
Gülhane Military Medical
Academy, Department of
Cardiovascular Surgery
Etlik-Ankara/Turkey
Tel: +90 312 304 52 73
e-mail:
hbingol@gata.edu.tr

ventricular septal defect (VSD), LVOTO, moderate aortic insufficiency, moderate mitral insufficiency (MI) and a 50 mmHg peak systolic gradient between the left ventricle and the aorta. Cardiopulmonary bypass was established with moderate hypothermia. Through right atrial, aorta and left atrial approach, accessory mitral valve tissue was observed in the LVOT through the inlet type VSD with the attachment to the anterior mitral leaflet and the tricuspid septal leaflet. Accessory mitral valve tissue was excised and the mitral valve was repaired with a 5/0 propylene suture and Carpentier's ring annuoplasty was done. VSD was closed with a Gore-tex patch.

Case 2. A 36 year old man was admitted in September 1997. The physical examination revealed a 3/6 grade systolic murmur at the left sternal edge. Echocardiography and catheterization demonstrated moderate MI, hypertrophy of the septum, 90 mmHg peak gradient between the left ventricle and the aorta and a sac like accessory mitral valve tissue causing LVOTO (Fig 1). At the operation through the left atriotomy the sac like accessory mitral valve tissue causing LVOTO was observed by using cardiopulmonary bypass and moderate

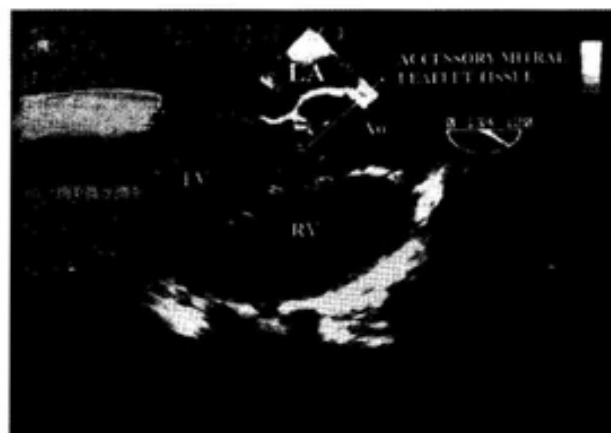


Figure 1. Accessory valve tissue attached to anterior mitral leaflet in two dimensional echocardiography.

hypothermia. At first, the repair of anterior mitral leaflet was attempted but it was observed that the valve tissue was not suitable for repairing so the mitral valve was replaced by using a St. Jude mechanical prosthesis No:27. Additional myectomy was done.

Case 3. A 41 year old man was admitted in February 1998. The physical examination

Table 1. Preoperative and operative characteristics of patients

Patients (yr/sex)	Anomaly	Gradient mmHg	Pathology	Associated lesions	Approach	Surgical therapy
20/M	VSD LVOTO AI-MI	50	Accessory leaflet tissue connected from anterior mitral leaflet to tricuspid septal leaflet through inlet VSD	inlet VSD	RA Aorta LA	Excision VSD repair (using gore-tex patch) Mitral valve repair
36/M	LVOTO MI	90	Sachlike accessory tissue attached to anterior mitral leaflet	Septal hypertrophy	LA	Myectomy MVR
41/M	LVOTO MI	65	Parachute-like structure attached to anterior mitral leaflet	Septal hypertrophy	LA Ao	Myectomy Mitral valve repair
22/M	LVOTO	75	Sachlike accessory tissue	Septal hypertrophy	Ao	Myectomy Excision
24/M	LVOTO AMS AI	60	Abnormal, elongate and fused chordae	AMS	RA Ao	Excision VSD repair (using gore-tex patch)

Ao: aorta, MI: mitral insufficiency, AI: aortic insufficiency, RA: right atrium, LA: left atrium, MVR: mitral valve replacement, AMS: aneurysm of membranous septum

revealed 2/6 systolic murmur at the left sternal edge. Echocardiography and catheterization revealed moderate MI, septal hypertrophy and LVOTO (65 mmHg systolic gradient between the left ventricle and the aorta). Cardiopulmonary bypass was established. Initially aortotomy was done and septal hypertrophy and accessory mitral valve tissue were observed. Myomectomy was done through the aortotomy. Then a parachute like structure attached to the anterior mitral leaflet causing LVOTO was observed through the left atriotomy. The anterior mitral leaflet was repaired with a 5/0 propylene suture and Kay annuloplasty was performed for mitral insufficiency.

Case 4. A 22 year old man was admitted in March 1999. The physical examination revealed a 2-3/6 grade systolic murmur at the left parasternal area. Echocardiography demonstrated a LVOTO with a 75 mmHg peak gradient between the left ventricle and the aorta. Cardiopulmonary bypass was established by using a single venous cannule and moderate hypothermia. Aortotomy was done and the septal hypertrophy and the accessory mitral valve tissue attached to the anterior mitral leaflet with the 3 chordae were observed. Myomectomy and the excision of mitral valve tissue were done. The mitral valve coaptation was controlled and no insufficiency was observed.

Case 5. A 24 year old man was admitted in september 2001. The physical examination revealed a 2-3/6 grade systolic murmur at the left sternal edge. Echocardiography revealed a LVOTO with a 60 mmHg peak gradient between the left ventricle and the aorta, membranous VSD and a mild aortic insufficiency. Cardiopulmonary bypass was established and an aneurysm of the membranous septum was observed through right atriotomy and closed with a Gore-tex patch. The aortotomy was done and the abnormal, elongated and fused chordae causing LVOTO was observed. Accessory mitral valve tissue was excised through the aorta.

None of the the patients had any early postoperative complications. The patients were discharged at mean postoperative

9.2±1.4 days. Postoperative TEE was done to all patients at the postoperative 7th day and the mean outflow tract gradient was 11.8 ± 3.9 mmHg.

DISCUSSION

Subaortic stenosis can be grouped into 4 different types. In Type I the main cause is the subvalvular fibrous diaphragm. In Type II muscular formation beneath the aortic cusps cause the outflow tract obstruction. In type III the cause is the abnormally attached mitral valve to the interventricular septum. In Type IV, a LVOTO is called when an accessory mitral valve tissue forms the obstruction. Accessory mitral valve tissue is a rare congenital anomaly which causes LVOTO (3). The aetiology of the accessory mitral valve tissue is not known well but is probably due to the abnormal development of endocardial cushion (4). Maclean and associates first described the accessory mitral valve tissue (5). According to Faggian and associates the accessory mitral valve tissue is classified into two types as; Type I: fixed and Type II: mobile. In type I, the accessory valve tissue is firmly anchored to the interventricular septum by short chordae. In mobile type, parachute-like leaflet floating in the ventricular outflow tract may cause the LVOTO (6). Accessory valve tissue have generally been associated with other abnormalities such as tetralogy of Fallot, transposition of the great arteries and atrioventricular septal defects. The clinical signs of the accessory valve tissue vary according to its location and the coexisting cardiac malformations (7). Echocardiography is the most useful technique for the diagnosis. Arboliras reported an accessory mitral valve tissue for the first time echocardiographically in 1985 (8).

McElhinney et al. reported 21 patients with systemic, pulmonary or bilateral obstructions due to accessory valve tissues. According to McElhinney, in most of the cases the left outflow tract was affected (systemic alone: 13 patients and bilateral: 3 patients) but in our study in all of the five patients the left ventricular tract was affected. The accessory valve tissue was associated with subaortic

membraneous or muscular obstruction (9).

Catheterization usually reveals a mass in the subaortic area and misdiagnosis can be observed. Catheterization is only useful to investigate other associated congenital malformations (1). Differential diagnosis of accessory mitral valve tissues from other subvalvular obstructions such as discrete subaortic stenosis and idiopathic hypertrophic subaortic stenosis is very important for the surgical approach and postoperative results (10). According to its prevalence, differential diagnosis of accessory mitral valve tissues may be underestimated. Moreover, during the cross clamp period it is difficult to observe the accessory valve tissue. Preoperative TEE is the most appropriate procedure for the diagnosis of accessory valve tissue.

In our cases, all operations were performed using cardiopulmonary bypass and aortotomy was the most preferred approach to identify the accessory mitral valve tissue causing LVOTO like other authors did. If the approach to the valve tissue from aortotomy is not satisfactory, an additional left atrial approach can be done.

Accessory mitral tissue may cause dynamic obstructions similar to those of idiopathic hypertrophic subaortic stenosis (IHSS) (10). In the course of time, obstruction becomes fixed and secondary asymmetric septal hypertrophy occurs. The differential diagnosis of accessory mitral valve tissue from IHSS is important, because no improvement occurs except in surgical therapy. Therefore the reasons of fixed gradients (accessory mitral valve tissue, discrete subaortic membrane, tunnel type subaortic stenosis) associated with IHSS must be investigated definitely and if so surgical treatment should be done in order to place dual chamber pacing and negative inotropic agents usage.

REFERENCES

1. Sono J, McKay R, Arnold RM. Accessory mitral valve leaflet causing aortic regurgitation and left ventricular outflow tract obstruction. *Br Heart J* 1988;59:491-7.

2. Cruz MC, Warnes CA. Accessory mitral valve leaflet. *J Heart Valve Dis.* 2000; 9: 791-3.
3. Ascutto RJ, Ross-Ascutto NT, Kopf GS, Kleinman CS, Talner NS. Accessory mitral valve tissue causing left ventricular outflow obstruction (two dimensional echocardiographic diagnosis and surgical approach) *Ann Thorac Surg.* 1986;42:581-4.
4. Van Praagh R, Corwin RD, Dahlquist EH Jr, Freedom RM, Mattioli L, Nebesar RA. Tetralogy of Fallot with severe left ventricular tract obstruction due to anomalous attachment of the mitral valve to the ventricular septum. *Am J Cardiology.* 1970;26:93-101.
5. Maclean LD, Culligan JA, Kane DJ. Subaortic stenosis due to accessory tissue on the mitral valve *J Thorac Cardiovasc Surg* 1963;45:382-8.
6. Faggian G, Frescura C, Thiene G, Bortolotti U, Maazzucco A, Anderson RH. Accessory tricuspid valve tissue causing obstruction of the ventricular septal defect in tetralogy of Fallot. *Br Heart J* 1983;49:324-7.
7. Yoshimura N, Yamaguchi M, Oshima Y, Oka S, Ootaki Y, Tei T, Ogawa K. Clinical and pathological features of accessory valve tissue. *Ann Thorac Surg* 2000;69:1205-8.
8. Arboliras ET, Tajik AJ, Puga FJ, Ritter DG, Seward JB. Accessory mitral valve tissue in association with discrete subaortic stenosis: A two dimensional echocardiographic diagnosis. *Echocardiography* 1985;2:191-5.
9. McElhinney DB, Reddy VM, Silverman H, Hanley FL. Accessory and anomalous atrioventricular valvar tissue causing outflow tract obstruction. *J Am Coll Cardiology.* 1998;32:1741-8.
10. Garret HE, Spray TL. Accessory mitral valve tissue: An increasingly reconized cause of left ventricular outflow tract obstruction. *J Cardiovasc Surg.* 1990; 31:225-30.