

# A CASE OF RAPIDLY RESOLVING PHANTOM TUMOR AFTER ACUTE VENTRICULAR FUNCTIONAL IMPROVING FOLLOWING CABG

T. YAVUZ, MD,  
A. ÖCAL, MD,  
C. NAZLI, MD\*,  
O. KINAY, MD\*,  
E. İBRİŞİM, MD,  
A. KUTSAL, MD

**From:**

Department of  
Cardiovascular Surgery,  
Faculty of Medicine,  
University of Süleyman  
Demirel, Isparta, Türkiye  
\* Department of  
Cardiology, Faculty of  
Medicine, University of  
Süleyman  
Demirel, Isparta, Türkiye

**Address for  
reprints:**

Dr. Turhan Yavuz  
Süleyman Demirel  
Üniversitesi Tıp Fakültesi  
Kalp ve Damar Cerrahisi  
ABD,  
Isparta, Türkiye  
Tel: +90 246 232 40 27  
e-mail:  
turhan.kvc@doctor.com

---

*Phantom tumor is an oedema formation developing in interlobar fissures due to congestive heart failure. Generally and typically it disappears following intense diuretic treatment.*

*Our case was a male, age of 53, who was suffering from atypical anginal pain located in the epigastric region for 1 year. The patient's predominant complaint was an epigastric located pain causing severe discomfort and he was in congestive heart failure state. The phantom tumor appearance was evident in the right lung field in chest roentgenogram. The coronary arteriography revealed severe ventricular hypokinesis, with a 95% stenosis accompanying dissection in LMCA (Left Main Coronary Artery), a total occlusion in RCA (Right Coronary Artery) and ostial complete occlusion in the left anterior descending artery (LAD). The echocardiography also showed severe ventricular hypokinesis and left ventricular end diastolic pressure (LVEDP), and LV ejection fraction were obtained to be 27 mmHg, 20% respectively. A prompt operation was planned. An LAD-LIMA anastomosis and aorto-RCA, Cx and OMI anastomoses using saphenous vein grafts were constructed for coronary revascularisation.*

*Reviewing the daily chest roentgenograms, it was observed that the phantom tumor appearance in the right lung field was disappeared in a few days and completely disappeared on the postoperative fourth day. Also the thorax computerised tomography was normal.*

*Our case might be considered important in terms of revealing the effect of CABG on acute ventricular improving in a case with poor left ventricular ejection fraction.*

**Key Words:** coronary bypass, phantom tumor, poor ventricular

---

**I**nterlobar pleural effusions causing tumor-like images in chest roentgenograms can develop in some cases with congestive heart failure. It is called the phantom tumor or

pseudotumor (1). It rapidly dissolves following intense congestive heart failure treatment. Presenting with round or fusiform forms in chest roentgenograms, phantom tumor should be distinguished from pulmonary infarcts, pulmonary or metastatic tumoral nodules and tuberculomas (2).

It typically resolves following intense diuretic treatment as a distinctive feature from other pathological processes.

Phantom tumor might also develop during the course of congestive heart failure due to ischemic heart diseases.

Our case might be considered important in terms of revealing the effect of CABG on acute ventricular improving in a case with poor left ventricular ejection fraction.

### CASE

A male, age of 53, was presented with epigastric located atypical anginal pain occurring after physical activity periods for 1 year. His medical history revealed a past myocardial infarction which occurred 2 months ago. He was suffering from epigastric located pain causing severe discomfort and with a congestive heart failure state. After obtaining electrocardiography and cardiac enzyme changes, he was hospitalized into the coronary intensive care unit. The chest roentgenogram revealed phantom tumor in the right lung field

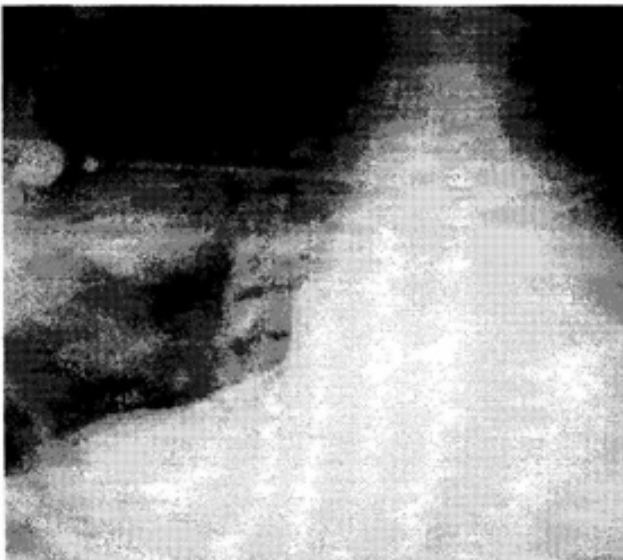
with a size of 5x5 cm (figure 1). Echocardiographically, LV (left ventricle) ejection fraction was 20%. Coronary arteriography revealed severe ventricular hypokinesis, 95% stenosis accompanying dissection in LMCA, total occlusion in RCA and ostial complete occlusion in LAD.

### Clinical Course

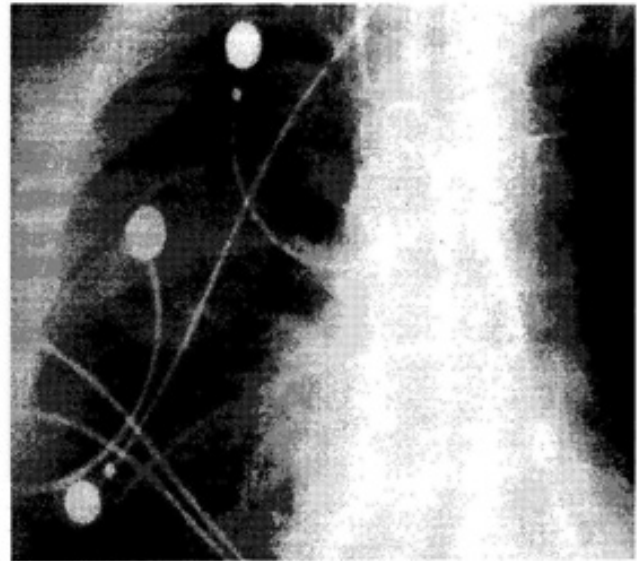
Preoperatively, intraaortic balloon counterpulsation was inserted. Following median sternotomy LIMA (left internal mammary artery) was harvested as a graft. Aorta and vena cava were cannulated in a standard fashion. Left ventricular contractions were diminished on inspection.

LAD-LIMA anastomosis and aort-RCA, Cx and OMI anastomosis using saphenous vein grafts were constructed for coronary revascularization. The operation was terminated with the support of intraaortic balloon counterpulsation (IABC) and positive inotropic drugs. The patient was extubated on the 16th hour, postoperatively. Low dose positive inotropic support and IABC in low frequency were continued.

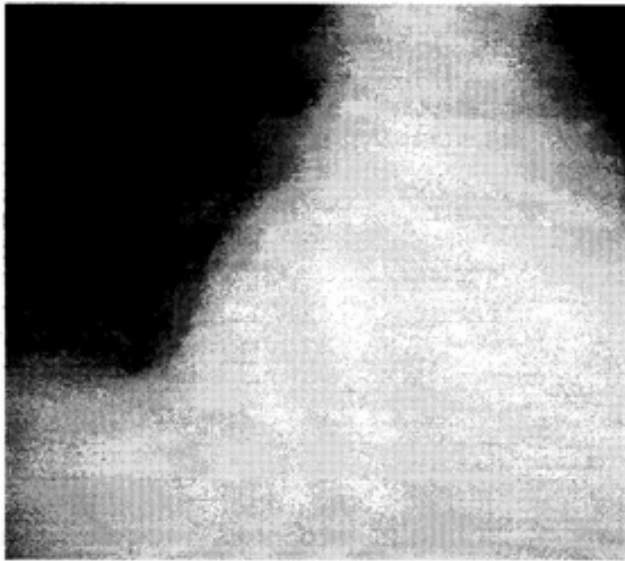
The phantom tumor appearance in the right lung field was slightly diminished in chest roentgenogram on postoperative first day (figure 2). The patient was transferred into the clinical room from the cardiac surgical intensive care on the postoperative third day.



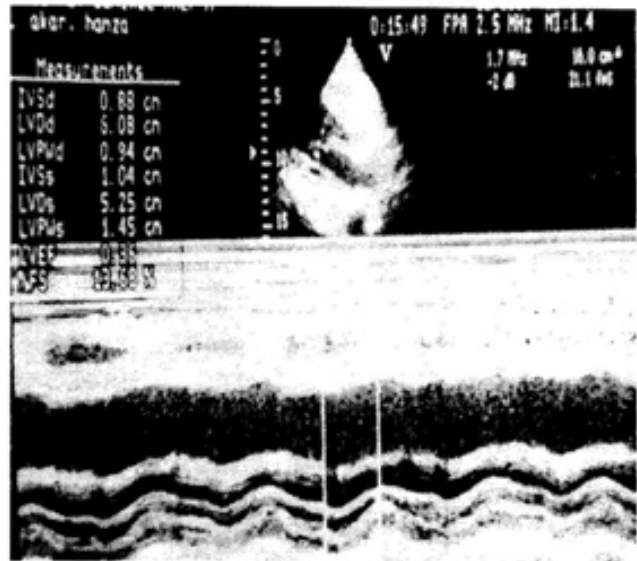
**Figure I.** Phantom tumor appearance in preoperative chest roentgenogram.



**Figure II.** Phantom tumor appearance in the right lung field was slightly diminished in chest roentgenogram on postoperative first day.



**Figure III.** Phantom tumor image was completely disappeared in chest roentgenogram on postoperative fourth day .



**Figure IV.** Postoperative seventy day LV ejection fraction with echocardiography was 36 %.

The phantom tumor image was completely disappeared in the chest roentgenogram on the postoperative fourth day (figure 3). The thorax computerized tomography was taken to confirm the resolving of the phantom tumor and it was obtained completely clear. The postoperative seventy day LV ejection fraction with echocardiography was 36 % (figure 4). The patient was discharged uneventfully on the postoperative seventh day.

### DISCUSSION

The mortality of CABG (coronary artery bypass graft) begins to rise when LV ejection fraction falls below 0.40. But the increased incidence of recurrent angina and late nonfatal myocardial infarction were not to be found in relation with the ejection fraction levels (3).

The factors affecting the surgical outcome of patients with poor left ventricular function following CABG are unclear. But the operative treatment can be performed with safety and serves well symptomatic improving and favorable survival (4).

Operative mortality of surgical treatment is low with favorable results in patients with coronary artery disease and poor left

ventricular ejection fraction particularly when myocardial viability was documented preoperatively (5). The CABG improves global systolic and diastolic LV function and relieves symptoms in cases with severe left ventricular dysfunction and myocardial hibernation (6).

NHYA classes and the left ventricular ejection fraction improves and if present, congestive heart failure resolves following operation (7). Improvements in NHYA class, diminishing of the anginal episodes and increases in the LV ejection fraction (echocardiographically) occurs in time.

In our case, resolving of a preoperative evident phantom tumor on the postoperative third day is important in terms of typically implicating ventricular functional improving.

It is not possible everytime to obtain a complete improve in left ventricular ejection fraction of patients with poor left ventricular function echocardiographically in the postoperative period. It doesn't mean that operation didn't work well for those patients. In a study it was shown that ejection fraction was improved in myocard perfusion scans in rest and with stimulation although ejection fraction in rest didn't (8). In our case the perioperative and on postoperative first week

ejection fractions were 20% and 30% respectively. However, the rapidly resolving of the preoperative evident phantom tumor in postoperative early period is an indirect indicator of increase in ventricular performance.

Finally; operations could be performed with low mortality if viability tests were done preoperatively in patients with poor left ventricular function. Those patients improve rapidly including the congestive heart failure state following CABG.

Our case is important in terms of showing that the effect of coronary artery bypass surgery on acute ventricular improving with a case of poor left ventricular function.

### REFERENCES

1. Kweider M, Simma M. Phantom tumor in left heart failure. *Pneumologie* 1989;43(5):259-261.
2. Molino Trinidad C, Sola Pascual P et al. Phantom tumor (author's transl) *Med Clin (Barc)* 1979;15;73(3):109-113.
3. Risum O, Nitter Hauge S, Abdelnoor, et al. Mortality and morbidity after coronary artery bypass surgery related to preoperative left ventricular ejection fraction: a follow up study. *Eur Heart J*.1996;17(6):817-818.
4. Chan RK, Raman J, Lee KJ, et al. Prediction of outcome after revascularisation in patients with poor left ventricular function. *Ann Throc Surg* 1996;61(5):1428-1434.
5. De Carlo M, Milano AD, Borzoni G, et al. Myocardial revascularisation in patients with ischemic cardiomyopathy and left ventricular dysfunction. *Cardiologia* 1997;42(5):481-488.
6. Pepper J, Fox K, Underwood SR. Hibernating myocardium: clinical and functional response to revascularisation: *Eur J Cardiothoracic Surg* 1997;11(6):1105-112.
7. Shapira I, Isakov A, Yakirevich V, Topilsky M. Long term results of coronary artery bypass surgery in patients with severely depressed left ventricular function. *Chest* 1995 Dec;108(6):1546-1550.
8. Elhendy A, Cornel JH, van Domburg RT, Bax JJ, Roelandt JR. Effect of coronary artery bypass surgery on myocardial perioperative ejection fraction response to inotropic stimulation in patient improvement in resting ejection fraction. *Am J Cardiol* 2000;1:86(5):490-494.