

# SUPERIOR VENA CAVA SYNDROME DUE TO SUBCLAVIAN HEMODIALYSIS CATHETER

SIBEL POÇAN\*,  
MURAT ÖZSOY\*,  
ÇIĞDEM TÛTÛNCÛ\*,  
MERİH GÖKBEN\*,  
MELİH HULUSI US\*\*,  
AHMET TURAN YILMAZ\*\*

*The widespread use of subclavian dialysis catheters has revealed a high incidence of venous thrombosis and exposed their potential to cause major obstructive complications that may compromise permanent vascular access. We present a case of a patient with superior vena cava syndrome resulting from dialysis access catheter placed in the subclavian vein. The patient's symptoms and signs were typical. Angiography showed obstruction of the superior vena cava with thrombosis. Surgical repair consisted of thrombectomy and patch repair of superior vena cava with autologous pericardium. The complaints of the patient decreased significantly after operation. In view of this late vascular complication, use of subclavian dialysis catheters should be kept in a minimum by creating an early a-v fistula.*

**From:**

GATA HAYDARPAŞA TRAINING  
HOSPITAL , ISTANBUL  
Anesthesiology and Reanimation  
Department\*  
Cardiovascular Surgery Department \*\*

**Key words:** Superior vena cava syndrome, dialysis catheter.

Since its original description in 1969, subclavian vein catheterization has become increasingly popular as a method of temporary vascular access for hemodialysis (1). Subclavian hemodialysis catheters are easy to insert using a modified Seldinger technique and can be used immediately. Dual-lumen catheters provide high blood flow, low recirculation, and low venous resistance. Subclavian vein catheterization has been shown to be quite safe but may be associated with life-threatening complications like pleural and mediastinal injuries, neurological damage, superior vena cava rupture and air embolism. The list of long-term complications continues to grow and includes unilateral and bilateral subclavian vein stenosis problems that may prelude further access for hemodialysis (2). We report herein the case of superior vena cava syndrome as a result of chronic indwelling hemodialysis catheter.

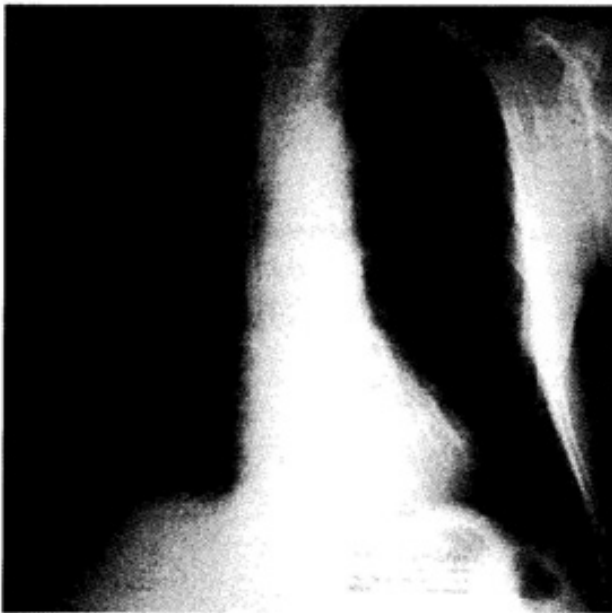**Address for**

**reprints:**

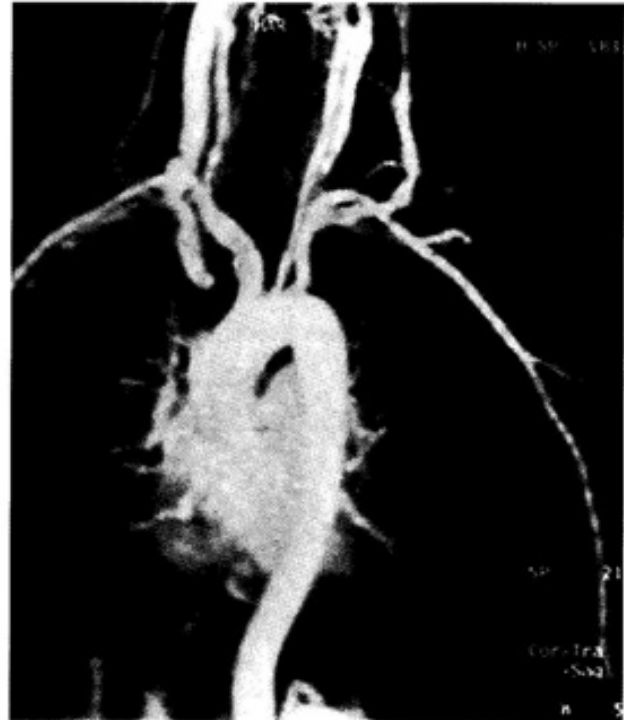
SİBEL POÇAN  
GATA HAYDARPAŞA TRAINING  
HOSPITAL  
ANESTHESIOLOGY AND REANI-  
MATION DEPARTMENT  
Selimiye Mah. Tibbiye Cad. 34670  
Kadıköy/Istanbul/TURKEY  
Phone number: +90-(216) 542-2781  
e-mail address:  
sibelpocan@hotmail.com

## REPORT OF THE CASE

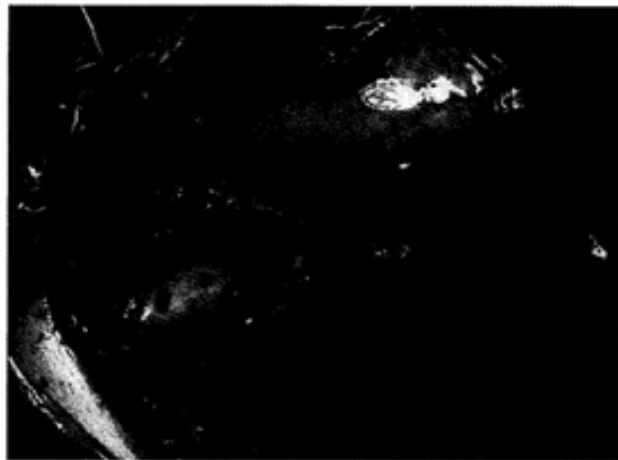
A 44 year old man with endstage renal failure secondary to hypertension were treated with hemodialysis over ten years. Unfortunately, because of problems regarding arteriovenous fistulae, multiple central venous cannulations were required for dialysis. Last time right subclavian vein cannulation was performed permanently and used several times during 3 months for hemodialysis. In early July 2004 he presented with sudden onset of facial swelling and distended veins over his chest wall. Complaints of the patient were increasing as he lied down and with hydration. The chest x-ray revealed no mediastinal widening, subclavian catheter was seen in right subclavian vein (figure 1). Magnetic resonance imaging and angiogram revealed the obstruction of vena cava superior at the level of innominate vein (figure 2). In a two days period; history of dyspnea, headache and hypertension were also included into the case. The patient had anticoagulation therapy , dialysis support , antihypertensive medication before the operation.



**Figure I:** The chest x-ray revealed no mediastinal widening, subclavian catheter was seen in right subclavian vein



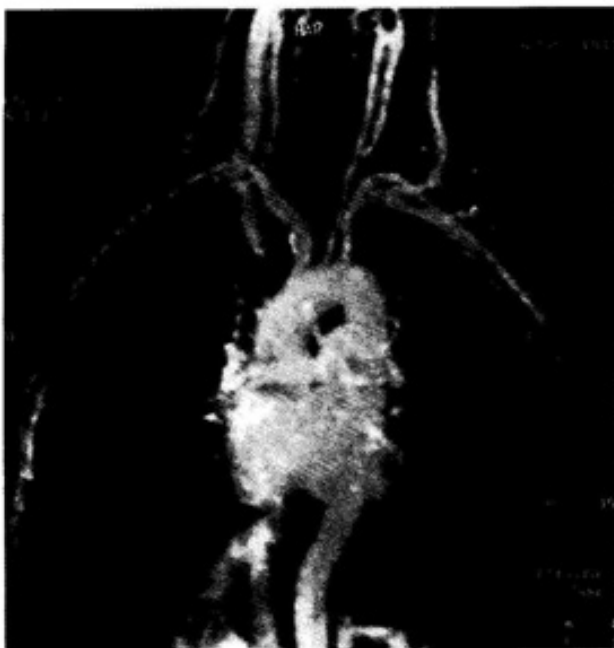**Figure II:** Magnetic resonance imaging and angiogram revealed the obstruction of the vena cava superior at the level of innominate vein.



**Figure III:** Surgical repair consisted of thrombectomy and patch repair of superior vena cava with autologous pericardium

Premedication was performed with midazolam and monitorization was applied to the patient. Invasive femoral artery monitorization was used. Left femoral vein was preferred for venous administrations. Pentothal sodium 2.5 mg/kg, fentanyl 0,1 mcg/kg, vecuronium 0.1 mg/kg were used for anesthesia induction and

maintained with isoflurane, fentanyl, air/oxygen mixture. Hemodynamic stability was preserved and overhydration was avoided during operation. Surgical repair consisted of thrombectomy and patch repair of superior vena cava with autologous pericardium (figure 3). Also, PTFE tube graft was placed between left brachial artery and cephalic vein to create a-v by-pass. Patient recovered both clinical and anatomical after the operation (figure 4).



**Figure IV:** Patient recovered both clinically and anatomically after the operation.

## DISCUSSION

This case description, adds subclavian hemodialysis catheters to the list of causes of superior vena cava syndrome and expands the list of complications of chronic indwelling subclavian hemodialysis catheters. A number of studies showed no significant long-term sequelae from subclavian dialysis catheters. In a prospective study extending over 5 years Vanholder et al observed no fatal complications in 257 consecutive patients who had subclavian vein catheterization for hemodialysis (2).

Recently, reports of alarmingly high rates of subclavian catheter-related thrombosis have begun to emerge. Ratcliffe and Oliver performed venography through the subclavian cannula on eight consecutive hemodialysis patients (3). They discovered large clots in the lumen of the catheters in seven of eight patients. The catheters, however, functioned adequately from 1 to 6 weeks in six of eight patients, indicating the silent nature of the thrombosis. Spinowitz et al, performed peripheral venograms in 13 patients who either had indwelling catheters in the subclavian vein or had been previously catheterized (4). Six of these 13 patients had slight to severe narrowing of the subclavian vein. The authors concluded that subclavian vein stenosis is quite commonly not related to the duration of catheter placement and frequently resolves spontaneously.

The exact etiology underlying the venous thrombosis at present is speculative. The most likely initiating event in the pathogenesis of subclavian vein thrombosis is the endothelial injury caused during catheter insertion. The oscillating movement of the catheter during the hemodialysis procedure may further injure the endothelium. Single as well as dual lumen catheters are associated with thrombosis and the catheter material itself may also be thrombogenic. Localized infection at the catheter site may also activate the coagulation cascade (5). Probably a combination of several factors plays a role in thrombus formation. The catheter-associated thrombus may potentially resolve spontaneously or it can organize into a scar, resulting in stenosis of the vessel. There have been no reported cases of spontaneous resolution of subclavian vein stenosis.

Subclavian vein obstruction is usually clinically silent. Poor function and repeated clotting of the vascular access have been suggested as

causes to occult venous stenosis (6). A recent report by Schwab et al has also documented the potential benefit of balloon angioplasty for dialysis catheter-related subclavian vein stenosis (7). Other reports have recommended that endovascular managements were not superior to surgical repairment (8,9).

In the patient in this report, superior vena cava syndrome (SVCS) and central vein stenosis developed insidiously over 3 months. There was never any edema of the upper extremities, probably due to extensive venous collateral circulation, which developed over a period of time. Hemodialysis itself may have altered the clinical expression of SVCS by serving the same purpose as the diuretics that have been advocated as conservative management of patients with SVCS (5). Cimochoowski et al. suggested in a report that internal jugular vein catheters for dialysis may have a dramatically low incidence of central vein stenosis (0%) compared with subclavian catheters (70%) (10). Hamer and Tagboto recently reported a case with SVCS who suffered respiratory arrest and died while waiting surgery cause of thrombus along the right internal jugular dialysis catheter and partial obstruction of the superior vena cava (11).

Based upon the available literature and our recent experience, we make the following recommendations: 1) prior to the insertion of a subclavian vein catheter, venography should be considered in patients who had multiple subclavian catheters and those who have other evidence of possible central vein stenosis, 2) if a significant stenosis is discovered, endovascular or surgical management should be considered, 3) internal jugular catheterization should be considered, 3) internal jugular catheterization should be considered in patients requiring prolonged dialysis with temporary access given the potential reduced risk of central vein stenosis,

and 4) permanent vascular access should be provided prior to initiating dialysis whenever possible.

## CONCLUSION

Subclavian catheters should be avoided for hemodialysis by creating a permanent vascular access at the earliest possible time. Physicians dealing with such catheters should be aware of the dangers inherent in such devices. Subclavian hemodialysis catheter-related stenosis of the central veins should be included in the differential diagnosis of SVCS in a dialysis patient and should be added to the growing list of complications from subclavian dialysis catheters.

## REFERENCES

1. Erben J, Kuasrikka J, Bustclay J: Experience with routine use of subclavian vein cannulation in hemodialysis. *Proc EDTA* 6: 59-62, 1969.
2. Vanholder R, Lemeire N, Verbenick J, et al: Complications of subclavian catheter hemodialysis; a 5-year prospective study in 257 consecutive patients. *Int J Artif Organs* 5: 297-303, 1982.
3. Ratcliffe F, Oliver D: Massive thrombosis around subclavian cannulas used for hemodialysis. *Lancet* 1:1972-1973, 1982.
4. Spinowitz B, Galler M, Golden R, et al: subclavian vein stenosis as a complication of subclavian catheterization for hemodialysis. *Arc Intern Med* 147:305-307, 1987.
5. Aujla N, McCauley J, Sarkin M: Superior vena cava syndrome due to subclavian hemodialysis catheters. *Military Medicine* 155: 274-277, 1990
6. Kouchoukos NT, Blackstone EH, Doty DB,

et al. Acquired diseases of the systemic veins. NT Kouchoukos et al. eds. Kirklin/Barratt-Boyes. Cardiac Surgery. Philadelphia, Churchill Livingstone; 2003: 1919-1938.

7. Schwab SJ, Quarles LD, Middleton JP, et al: Hemodialysis-associated subclavian vein stenosis. *Kidney Int* 33: 1156-1159, 1988.

8. Bornak A, Wicky S, Ris HB, et al. Endovascular treatment of stenoses in the superior vena cava syndrome caused by non-tumoral lesions. *Eur Radiol.* 2003; 13(5): 950-956.

9. Kalra M, Gloviczki P, Andrews JC, et al. Open surgical and endovascular treatment of superior vena cava syndrome caused by non-malignant disease. *J Vasc Surg.* 2003; 38(2): 215-223.

10. Cimochoowski G, Sartain J, Worley E, et al: Clear superiority of internal jugular access route over the subclavian vein in 52 patients with 102 venogram. *Kidney Int* 31: 236, 1987

11. Hamer R, Tagboto S: Superior vena caval obstruction following central venous cannulation. *Nephrol Dial Transplant* 19: 258, 2004.