

# INTRAABDOMINAL BLEEDING DUE TO FEMORAL VEIN CATHETERIZATION

FARUK CİNGÖZ, MD,  
CELALETTİN GÜNAY, MD,  
ALPER UCAK, MD,\*  
M. ERİN TÜYSÜZ, MD,  
ERKAN KURALAY, MD,  
HARUN TATAR, MD

---

*A suitable venous line to establish hemodialysis for patients with chronic renal failure is very important issue in their late period. A veno-venous hemodialysis catheter was attempted to insert into the right femoral vein in a case with chronic renal failure. After that procedure, hypotension was occurred and venous blood was taken from peritoneal catheter. The case will be discussed regarding venous traumatic events in hemodialysis patients under the literatures.*

*Key words: Renal failure, Hemodialysis, bleeding.*

---

**From:**

Gulhane Military Medical Academy  
Department Of Cardiovascular Surgery,  
Ankara/ TURKEY

\*GATA Haydarpaşa Training Hospital,  
Department Of Cardiovascular Surgery,  
Istanbul/ TURKEY

A hemodialysis procedure is performed by arteriovenous fistula, veno-venous or intraperitoneal catheter in patient with chronic renal failure 1. The selection of technique is up to patient's condition, vessel structure, additional diseases, obesity and previous abdominal surgery 1-2. An adequate venous line for convenient blood flow for veno-venous hemodialysis is important issue for these patients. For this reason, central venous lines are used (Internal jugular vein, subclavian or femoral vein) 1-3. In this case report; we present a patient who had intraperitoneal bleeding after femoral vein catheterization.

## CASE REPORT

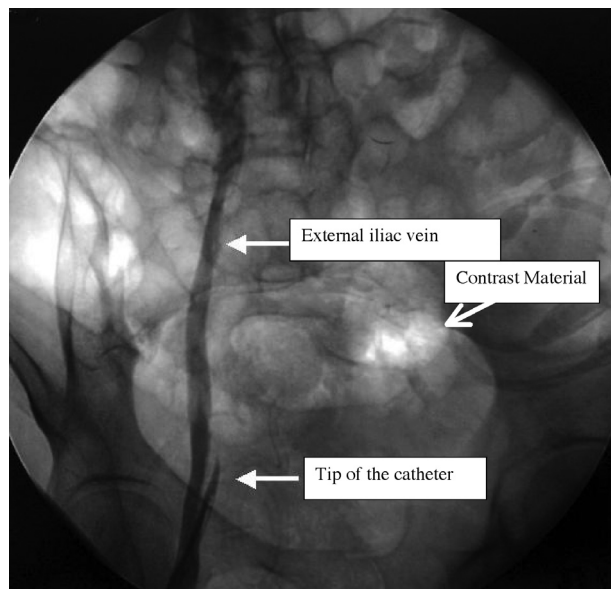
A 60 year old female patient (83 kg.-1.65 cm) who had undergone peritoneal dialysis for 4 years and hemodialysis for last 2 years, has been catheterized for hemodialysis via right femoral vein. She had taken hemodialysis via a venous catheter for 2 years because arterio-venous fistula could not be established due to absence of suitable veins. Bilateral jugular veins and upper limb veins had been used at previous catheterizations (bilateral subclavian vein thrombosis was detected). A double lumen Biometrix (Kiryat Moda 4, Jerusalem, Israel) venous catheter was inserted into the right femoral vein percutaneously. But intraabdominal bleeding has been thought due to absence of blood return from catheter, hypotension which was normalised by fluid support, decrease on hematocrit level, and costolomber pain increasing in one

**Address for**

**reprints:**

Dr. Faruk Cingöz  
GATA Subay Lojmanlari,  
Serter Apt. 2/9 06018 / ETLİK  
ANKARA / TURKEY  
Phone: +90 312 3046789  
E-mail: fcingoz@yahoo.com

hour. Venography was performed after hemorrhagic fluid has been seen into peritoneal dialysis catheter. It was very good sign because during catheterization the peritoneal catheter was into the peritoneal cavity. İliac vein's wall that had been drilled by catheter's tip and extravasation of contrast material was determined by venography (figure 1)



**Figure 1:** The Tip of the catheter was out of the vein and some contrast material was noticed in peritoneal cavity.

The patient was operated on and retroperitoneal approach was used to reach to external iliac vein. The catheter's tip was out from medio-lateral part of the vein, and rupture was repaired by lateral suture technique. Diffuse clots in the retroperitoneal area were cleaned. There was a small defect on peritoneum. It was thought that the catheter had passed from peritonea and the bleeding was spreading into the peritoneal cavity from that point. The incision was sutured after bleeding control and a silicon drain was placed.

## DISCUSSION

It is obvious that suitable venous line must be obtained for circulating blood outside of the body at required flow (200 – 400 cc/min) and amount on hemodialysis. For this reason; at

first arterio-venous fistula must be established 1,2. But absence of appropriate artery or vein prevent arterio venous fistula establishment. Furthermore peritoneal dialysis or veno-venous hemodialysis (VVH) is used. Internal jugular vein, subclavian or femoral veins are generally used for VVH 1 . At our case we aimed to use right femoral vein for VVH because of insufficiency of peritoneal dialysis.

We used a double lumen elastic (polyurethane), without baloon, blunt shaped and 15 cm long catheter for VVH. The catheter was advanced slidely into the femoral vein above the guidewire passed into 18 Gauge needle, after using dilatator twice. Catheter that can supply the necessary blood flow is ready for use after being fixated on the skin.

The most serious complication after femoral vein catheterization is bleeding. Naumovic et al. performed femoral vein catheterization on 41 patients at their 107 patient series. They informed that, at the early period of the process, there were bleeding and hematomas on the interference zone, and femoral artery damage<sup>4</sup> . Kannan et al. informed that there were bleeding into peritoneal cavity on patient had ascites and abdominal edema, among the early period complications<sup>5</sup> . We have performed peritoneal dialysis before femoral approach in our case. But hemodialysis was decided to perform due to insufficiency of peritoneal dialysis.

Tomlinson et al. has preferred to perform laparotomy at intraperitoneal bleeding cases developed after femoral access<sup>6</sup>. We decided to perform a surgical approach from retroperitoneal space according with venographic findings in our case.

In conclusion, an intraperitoneal bleeding may be seen especially in patients with ascites as a complication depend on the catheter placement after femoral vein access. Therefore if femoral venous catheterization is planned to a patient with ascites or abdominal wall stretch, intraperitoneal bleeding must be kept in mind. For certain diagnosis, beside hematocrit and hemoglobin follow-up, peritoneal punctum may be performed.

## REFERENCES

- 1.** Fan PY, Schwab SJ. Vascular access: Concepts for the 1990s. *J Am Soc Nephrol.* 1992; 3:1-11.
- 2.** Oliver MJ, Acute dialysis catheters. *Semin Dial.* 2001; 14:432-5.
- 3.** Butterly DW, Schwab SJ. Catheter access for hemodialysis: an overview. *Semin Dial.* 2001; 14:411-5.
- 4.** Naumovic RT, Jovanovic DB, Djukanovic LJ. Temporary vascular catheters for hemodialysis: a 3-year prospective study. *Int J Artif Organs.* 2004; 27:848-54.
- 5.** Kannan S, Hutchinson JD. Accidental intraperitoneal insertion of femoral haemodialysis catheter in tense ascites and anasarca. *Anaesthesia.* 2000; 55:399-400.
- 6.** Tomlinson S, Stannard L. Laparotomy following femoral venous line insertion. *Br J Anaesth.* 2000; 84:829.