

A Case Report: Isolated Calcification of the Pulmonary Valve and Bleeding of the Esophageal Varices

Fuat Büyükbayrak MD¹, Ahmet Şaşmaz MD¹, Onursal Buğra MD¹, Ayşe Baysal MD², Ali Fedakar MD¹, Orhan Tezcan MD¹, Hasan Sunar MD¹

¹ Kartal Koşuyolu Yüksek İhtisas Eğitim ve Araştırma Hastanesi, Kalp ve Damar Cerrahisi Kliniği

² Kartal Koşuyolu Yüksek İhtisas Eğitim ve Araştırma Hastanesi, Anesteziyoloji Kliniği

ABSTRACT

A 66 years-old man with a history of pulmonary valve stenosis was admitted with the complaints of respiratory insufficiency and sudden onset of dark brown bleeding from the mouth. The in-hospital investigation revealed he had esophageal varices and cirrhosis of the liver. Further studies demonstrated that isolated pulmonary valve stenosis was present and this was the only cause of the hepatic failure. This is a case report of an isolated calcification of a pulmonary valve causing development of severe hepatic failure with abrupt bleeding of the esophageal varices.

Key Words: Isolated, calcific pulmonary valve, hepatic failure, esophageal varices

ÖZET

66 yaşında İzole Kalsifik Pulmoner Stenozlu ve Esofagus Varis Kanamalı Erkek Hasta

Pulmoner kapak stenozu hikayesi olan 66 yaşındaki erkek hasta, solunum sıkıntısı ve ani başlayan ağızdan koyu kahverengi kanama şikayetlerinin başlaması ile hastaneye yatırıldı. Hastanedeki incelemelerinde özofagus varisleri ve karaciğer sirozu tanıları konuldu. Yapılan değerlendirmeler sonucunda izole pulmoner kapak stenozunun karaciğer yetmezliğine neden olduğuna karar verildi. Bu yazımızda pulmoner kapaktaki izole kalsifikasyonun şiddetli karaciğer yetmezliği klinik bulgularına ve özofagus varis kanamalarına yol açtığını bildiren olguyu sunmayı amaçladık.

Anahtar Kelimeler: İzole, kalsifik pulmoner kapak, karaciğer yetmezliği, özofagus varisleri

INTRODUCTION

Pulmonary valve stenosis may be presented secondary to previous surgical procedures or associated with other congenital heart diseases (1-3). The most frequently reported congenital diseases are tetralogy of Fallot, atrial septal defect, coronary arteriovenous fistulas. (1) On the historical aspect, the pulmonary valve stenosis was surgically treated with open and closed valvulotomy techniques by Brock and his colleagues. (4) This case report is unique as it presents in an elderly patient without any history of congenital heart diseases and manifests itself in a clinical presentation associated with bleeding of esophageal varices and hepatic failure.

CASE REPORT

A 66-year-old man was admitted to our emergency room with the complaint of respiratory insufficiency and sudden onset of dark brown bleeding from the mouth, was admitted to our emergency room with the complaint of respiratory insufficiency and sudden onset of dark brown bleeding from the mouth. Medical history showed no previous exposure to inflammatory or infectious diseases and no history of alcohol or drug abuse. On his physical examination, he was found to have pallor, sweating, tachypnea, tachycardia and leg swelling. He had a 4/6 systolic murmur on the left side of the sternum at the fifth intercostal space and wheezing at the basal areas of both lungs. He had an enlarged liver about four centimeters below the left costal margin. Severe ascites and mild-severe pretibial edema were observed. The electrocardiography (ECG) showed a right ventricular enlargement associated with atrial fibrillation. The echocardiographic evaluation revealed a pulmonary stenosis with a maximum gradient of 83 mmHg. There was also right atrial and ventricular dilatation with normal left ventricular systolic function. Transesophageal echocardiographic examination (TEE) could not be performed due to the esophageal varices. The patient was hospitalized for medical management of his esophageal varices for about a month. An angiographic study showed a normal coronary arterial pattern. After the esophageal varices bleeding was under con-

Address for Reprints

Ahmet Şaşmaz, MD

Department of Cardiac Surgery Kosuyolu Heart and Research Center, 34846 Kartal Istanbul, Turkey

Telefon: 90 216 459 44 40 Faks: 90 216 459 63 21 e-posta: sasmazel@yahoo.com

tol, further evaluation was performed to find out the etiology of the hepatic cirrhosis and all the parameters showed that the hepatic dysfunction is due to right heart failure. He was offered a valvular surgery for the correction of calcific pulmonary stenosis. During surgery, pulmonary valve was found to have a severe valvular calcification (Figure 1).

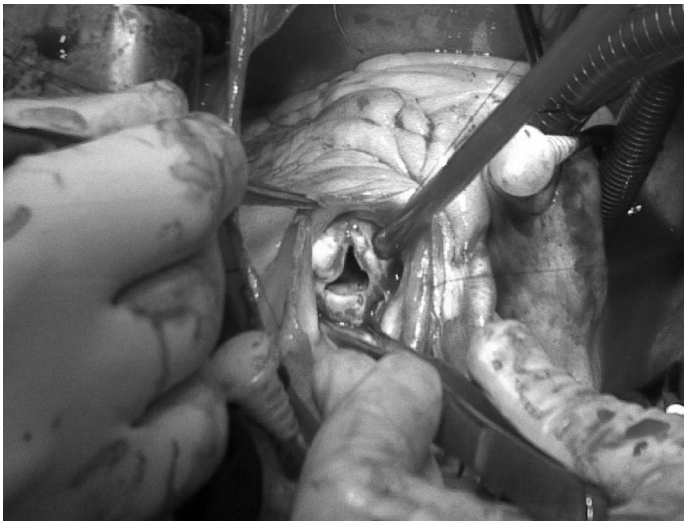


Figure 1: Intraoperative view of the calcific pulmonary valve

This calcification was localized to the valvular area and also it was found to be invading the subvalvular area. During surgery, we only resected the valve and reconstructed the right ventricular outflow tract with a glutaraldehyde treated pericardial patch (Figure 2).

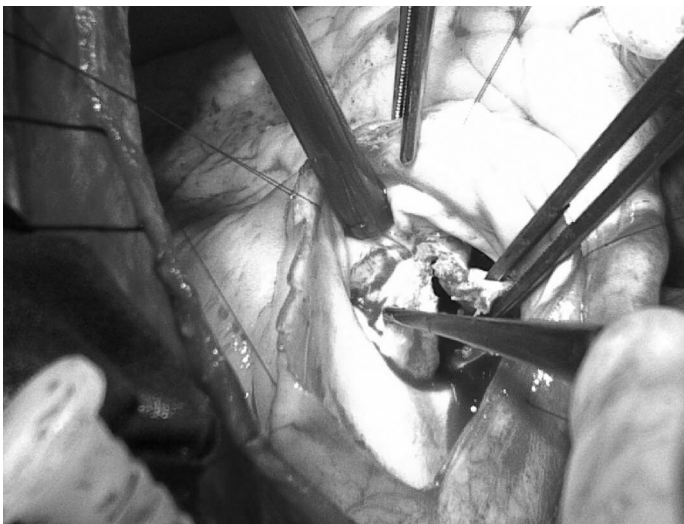

Figure 2: Removal of the calcific pulmonary valve

The patient recovered from surgery without postoperative complications. He remained in sinus rhythm after the surgery and was hemodynamically stable.

DISCUSSION

Isolated pulmonary stenosis is rarely observed in elderly patients. It is commonly identified in childhood and treated in the first and second decades of life. In isolated pulmonary stenosis, remission can occur even-

tually in 60% of the patients and slow progression of the stenosis is observed in the rest of the patients.(5) A child with a history of isolated pulmonary stenosis can grow and reach up to the adulthood without any intervention. Surgical valvulotomy can be performed in selected cases with good results. (1) In a recent study by Gielen and his colleagues,(5) patients with congenital pulmonary valve stenosis was investigated by echocardiography, in their study; an increase in pressure gradient and thickened leaflets were demonstrated in the follow-up periods.

The echocardiographic study showed us that a high pressure gradient was present between right ventricle and pulmonary artery. A thickening of the valvular leaflet is usually associated with high right ventricular pressure which eventually leads to right heart failure. This presentation has been reported to be observed in severe calcification of the pulmonary valve. (2,5).

The patient was presented to us with bleeding of the esophageal varices. After a differential diagnosis is performed with appropriate investigations, other etiological causes of hepatic failure were ruled out. This case is unique as there is no previous report of isolated pulmonary valve stenosis associated with hepatic failure and esophageal varices.

During surgical procedure, the calcification of the pulmonary valve was found to be intense on the annular side that the surgical intervention was limited to open valvotomy. Right ventricular outflow tract was enlarged with a glutaraldehyde treated pericardial patch as it was described by Brock and his colleagues (4). Implantation of a bioprosthetic valve might have increased our surgical interventional time and this might have negative effects on hepatic and end-organ functions of the patient. (5) In this case, postoperatively, the patient recovered without any complication.

In conclusion, as there is risk for potential development of right heart failure in the future, the bioprosthesis of pulmonary valve should be used for right ventricular outflow tract reconstruction. In selected cases where the time of the procedure is a major factor affecting the mortality and morbidity, open technique can be performed with a successful result.

REFERENCES

1. Earing MG, Connolly HM, Dearani JA, Ammash NM, Grogan M, Warnes CA. Long-term follow-up of patients after surgical treatment for isolated pulmonary valve stenosis. *Mayo Clin Proc* 2005;80(7):871-876.
2. Kopecky SL, Gersh BJ, McGoon MD, et al. Long-term outcome of patients undergoing surgical repair of isolated pulmonary valve stenosis: follow-up at 20-30 years. *Circulation*. 1988;78(5, pt 1):1150-1156.
3. Ota T, Okada K, Asano M, Nakagiri K, Okita Y. Isolated pulmonary stenosis in an elderly person: report of a case. *Surg Today* 2008; 38(12): 1117-9.
4. Brock RC. The surgical treatment of pulmonic stenosis. *Br Heart J*. 1961;23:337-343.
5. Gielen H, Daniëls O, van Lier H. Natural history of congenital pulmonary valvar stenosis: an echo and Doppler cardiographic study. *Cardiol Young*. 1999; 9(2):129-35.