

Bidirectional Cavopulmonary (Glenn) Anastomosis in Pulmonary Atresia with Intact Ventricular Septum and Right Ventricle Dependent Coronary Circulation

Ahmet Şaşmaz¹ MD, Ayşe Baysal² MD, Ali Fedakar¹ MD, Hasan Erdem¹ MD, Ahmet Çalışkan¹ MD, Rahmi Zeybek² MD

¹ Kartal Koşuyolu Yüksek İhtisas Eğitim ve Araştırma Hastanesi, Department of Cardiovascular Surgery, İstanbul, Türkiye

² Kartal Koşuyolu Yüksek İhtisas Eğitim ve Araştırma Hastanesi, Department of Anaesthesiology and Reanimation, İstanbul, Türkiye

ABSTRACT

This is a case report of an 8-month-old infant with congenital heart disease including; pulmonary atresia, intact ventricular septum, right ventricular hypoplasia, atrial septal defect, coronary sinusoids (fistulas between right ventricle and left anterior descending artery). The patient had a stent for patent ductus arteriosus at 3 months of age and after 4 months a bidirectional Glenn shunt operation was performed with successful haemodynamics postoperatively.

Key Words: Pulmonary atresia, intact ventricular septum, right ventricular dependent coronary circulation

ÖZET

Ventriküler Septumu İntakt Pulmoner Atrezili Olguda Sağ Ventriküle Bağımlı Koroner Sirkülasyonda Bidireksiyonel Kavopulmoner (Glenn) Şant Ameliyatı

8 aylık sağ ventrikül hipoplazili, pulmoner atrezili, intak ventriküler septumlu, koroner sinusoidlerin sol anterior desenden arteri beslediği olguda patent duktus arteriozusun 3 aylık iken stent ile açılmasından 4 ay sonra başarılı bidireksiyonel kavapulmoner (Glenn) şant ameliyatı, başarılı hemodinamik sonuçlarla yapıldı.

Anahtar Kelimeler: Pulmoner atrezi, intak ventriküler septum, sağ ventriküle bağımlı koroner sirkülasyon

INTRODUCTION

Pulmonary atresia with intact ventricular septum (PA/IVS) accounts for fewer than 1% of all congenital heart defects (1). PA/IVS and right ventricle dependent coronary circulation (RVDCC) is rarely observed and has been reported to be seen between 3% to 34% of all PA/IVS patients (2,3). PA/IVS is a morphologically heterogeneous lesion characterized by a variety of lesions and these include; hypoplasia of the right ventricle (RV) and tricuspid valve, abnormal coronary circulation, and pulmonary atresia itself (4). In PA/IVS-RVDCC, different anomalies of the coronary arteries are commonly observed such as; sinusoids, fistulae formations, stenosis or atresia. In this group of patients, the oxygen delivery to the myocardium depends on the oxygen saturation (SO₂) of the RV cavity. The surgical procedure of bidirectional Glenn shunt (BGS) with cardiopulmonary bypass (CPB) could cause a reduction of systemic venous return to the right atrium. During CPB, adequate RV filling and ejection of volume need to be maintained to prevent decompression of the RV in an effort to avoid myocardial ischemia (5).

CASE REPORT

An 8-month-old infant with a history of pulmonary atresia and patent ductus arteriosus (Figure 1), presented to our clinic with purple lips and difficulty in breathing. The patient had angiographic study which revealed an unrestrictive atrial septal defect, hypoplasia of the main pulmonary artery, RV-coronary artery fistulas between RV to coronary arteries and coronary sinusoids with stenotic or occluded proximal ends (Figure 2). The main supply to coronary arteries (left anterior descending) are from right ventricle dependent coronary sinusoids (Figure 3).

Address for reprints

Ahmet Şaşmaz, MD

Kartal Koşuyolu Yüksek İhtisas Eğitim ve Araştırma Hastanesi, Department of Cardiovascular Surgery, 34846 Kartal İstanbul, Turkey

Telephone: 90 216 459 44 40 Fax: 90 216 459 63 21 e-mail: sasmazel@yahoo.com

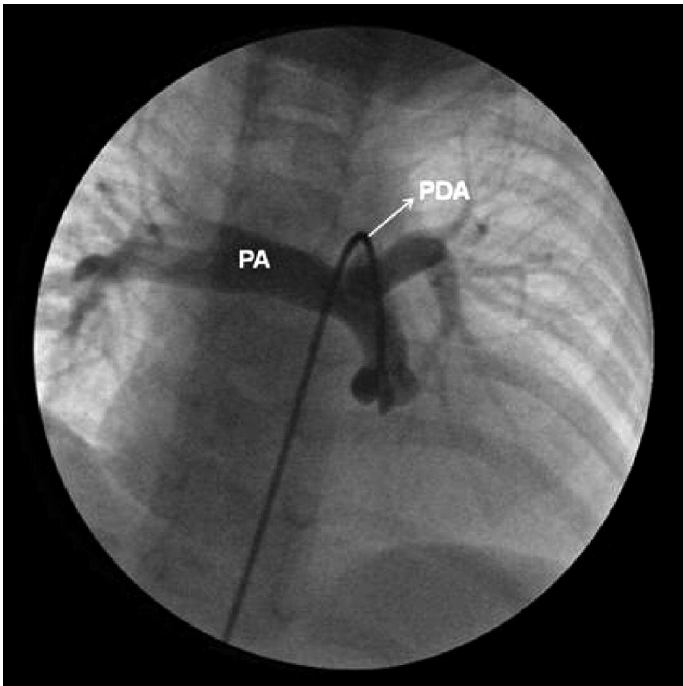


Figure 1: Pulmonary artery (PA), catheter passing through the patent ductus arteriosus (PDA).

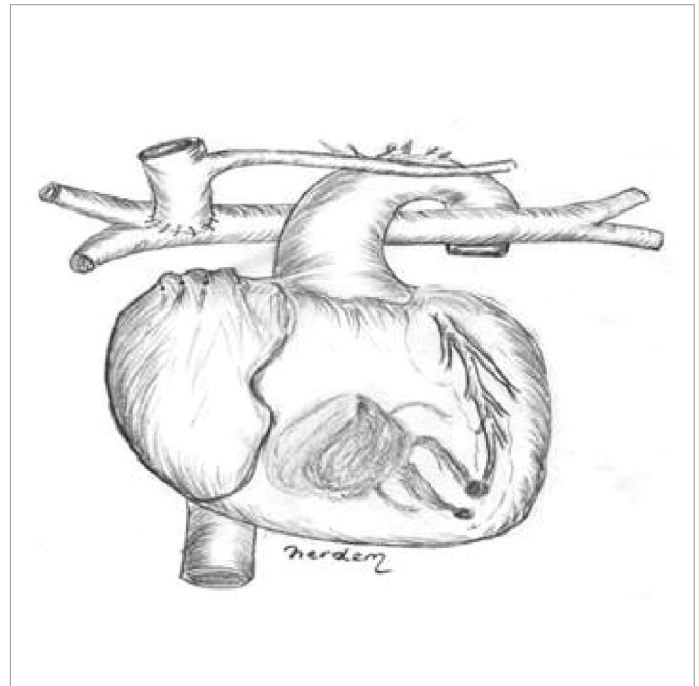


Figure 3: Schematic drawing of Glenn shunt surgical procedure and coronary sinusoids between RV and LAD.

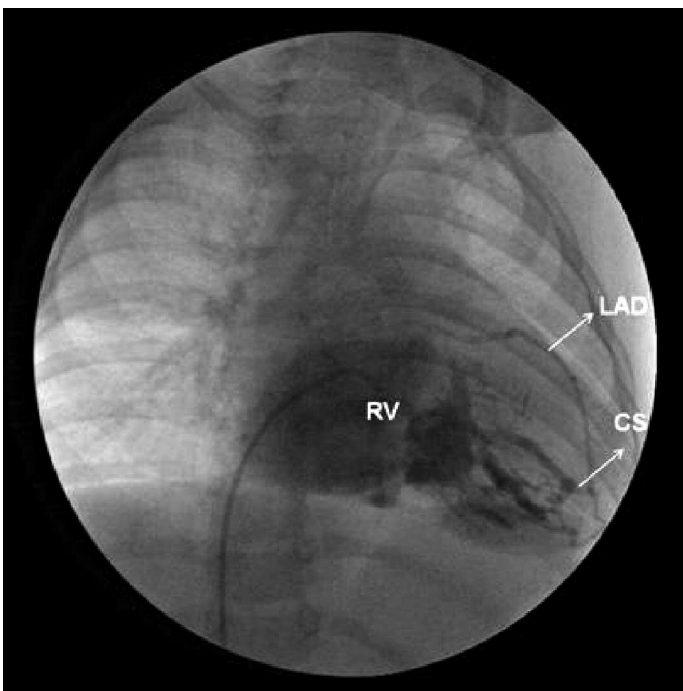


Figure 2: RV cavity injection and the RV-LAD (right ventricle-left anterior descending) connections via coronary sinusoids (CS)

At 3 months of age, she had a placement of a stent to patent ductus arteriosus (PDA) which is 6 mm in diameter. Her last transthoracic echocardiographic examination revealed that the right pulmonary artery diameter was 0.71 cm, the left one was 0.78 cm. Atrial septal defect of 0.98 cm was associated with right to left shunt. Before surgery, she had blood pressure of 96/64 mmHg, heart rate of 145/min, respiratory rate of 32/min, arterial oxygen saturation of 68 % on room air. General anesthesia was induced with midazolam,

fentanyl sulphate, and pancuronium bromide. The priming solution consisted of a crystalloid solution of isotonic sodium chloride (0.9 %) and mannitol (3 mL/kg). Packed red blood cells were used to obtain a haematocrit value of 25 % before initiation of CPB. After induction; patient had blood pressure of 106/68 mmHg, heart rate of 130/min, respiratory rate of 28/min, arterial oxygen saturation of 86 % on 100 % fraction of inspired oxygen (FiO₂). A median sternotomy was performed and thymus was totally resected. BGS procedure was established between superior vena cava to right pulmonary artery and the PDA was clipped under normothermic cardiopulmonary bypass (36 °C). During CPB, a perfusion index of 2.4 to 2.6 L/min/m² was used. The duration of cardiopulmonary bypass was 28 minutes. Neutralization of heparin was achieved with protamine sulphate in a 1:1.5 ratio.

The haemodynamic effects of these coexisting coronary anomalies in this particular congenital heart disease patients are commonly severe and increase the surgical risk. During the cardiopulmonary bypass, we were cautious to keep the heart filled and beating to provide oxygenated blood to the myocardium. During operation, the blood samples were taken from the RV cavity before and after the BGS. The oxygen saturation of the RV cavity before the BGS was 64.6 %, and after the BGS procedure it significantly increased up to 79%. ST depressions were found in leads V4 through V6 before BGS on the electrocardiogram. The ST changes improved after BGS. After weaning from cardiopulmonary bypass, our aim was to keep the mean arterial pressure above 60 mmHg. At the end of cardiopulmonary bypass, the patient received intravenous dopamine at a renal dose (3 mcg/kg/min), dobutamine (10 mcg/kg/min) as well as adrenaline (0.1 mcg/kg/min) and nitroglycerine 0.5 mcg/kg/min. The patient continued the same

inotropic agents at the same doses in the first six hours after surgery in the intensive care unit. Inotrope doses were weaned off afterwards. The patient was extubated sixteen hours postoperatively. The patient remained haemodynamically stable for a total of three days in the intensive care unit and was discharged home on the seventh day postoperatively.

DISCUSSION

PA/IVS shows variations in the size of tricuspid annulus and also in the size of RV cavity (3,5). This pathology is usually associated with coronary artery anomalies and an association with PA/IVS-RVDCC had been reported previously (6). The coronary sinusoids are the connections between the cavity of the right ventricle and coronary arterial bed and these are characterized as thick walled and distended intertrabecular myocardial spaces, which connect with the subepicardial coronary arteries (7). RVDCC is usually related to the smaller size of the RV and the tricuspid valve (8). Giglia and his colleagues (9), revealed that RV decompression is contraindicated in the presence of stenosis or occlusion of the coronary arteries. Death in patients with PA/IVS-RVDCC who undergo RV decompression is most probably related to the amount of the LV myocardium at risk for ischemia (8-10).

In our case, stent placement was done into the patent ductus arteriosus at 3 months of age and she had a successful BDG shunt operation four months later. The patent ductus arteriosus stent implantation in patients with cyanotic congenital heart disease and duct-dependent pulmonary blood flow is technically feasible and provides an effective alternative to surgical systemic-to-pulmonary artery shunts. In RV-dependent coronary circulation oxygen delivery to the myocardium more or less depends on the RV cavity oxygen saturation. During angiographic examination, injection of radioopaque contrast material to the right ventricle revealed that a proximal occlusion or stenosis is present in the LAD. For this reason, in coronary anomalies with RVDCC, a detailed angiography was needed to detect complete aortocoronary atresia or proximal coronary stenosis. However, as in our case, it is usually difficult to show the exact coronary anatomy.

In PA/IVS-RVDCC, the coronary circulation is mainly supplied by the desaturated RV blood. These coronary abnormalities have a potential to cause ischemic damages to the left ventricle myocardium. Before BGS procedure, unsaturated blood was the source of perfusion to the coronary arteries; this pathophysiological circulation has negative impacts on myocardium which may cause the development of varying degrees of ischemia as seen in our case. The exact mechanism of this coronary ischemia is unclear and can be related to the presence of either one of the following; ventriculocoronary fistulae, coronary perfusion with undersaturated RV blood and/or coronary steal from the patent ductus arteriosus (7,8,10).

BGS would improve the oxygenation of RVDCC relative to systemic-pulmonary artery shunt. Aortopulmonary shunt placement and stent in the PDA causes an increased volume load on the left ventricle and decreases the

systemic diastolic pressure. The workload on the heart is increased while coronary perfusion is diminished in infants with a vulnerable myocardium. The BGS reduces volume load and workload on the left ventricle and increases cardiac output, resulting in high mixed venous oxygen saturation (9,10). As in our case, after the BGS procedure the ischemic changes on the electrocardiogram disappeared. The pathophysiologic mechanism that was underlying this event is thought to be related to the increased saturation of the right ventricle, interruption of coronary steal from the closure of the patent ductus arteriosus.

In our opinion, in PA/IVS-RVDCC patients with ischemic changes on electrocardiogram, the operation time of BGS is important and an earlier scheduling of BGS operation would avoid the progression of an excessive workload on the left ventricle and also would prevent the development of myocardial ischemia. The operative approach in these patients should focus on the filling pressures of the right and left ventricle and to maintain a well perfusion of the coronary arteries by a well controlled mean arterial pressure during cardiopulmonary bypass.

REFERENCES

1. Lightfoot NE, Coles JG, Dasmahapatra HK, Williams WG, Chin K, Trusler GA, et al. Analysis of survival in patients with pulmonary atresia and intact ventricular septum treated surgically. *Int J Cardiol* 1989; 24:159-64.
2. Freedom RM, Anderson RH, Perrin D. The significance of ventriculo-coronary arterial connections in the setting of pulmonary atresia with an intact ventricular septum. *Cardiol in Young* 2005; 15(5):447-68.
3. Zuberbuhler JR, Anderson RH. Morphological variations in pulmonary atresia with intact ventricular septum. *Br Heart J* 1979; 41:281-8.
4. Ashburn DA, Blackstone EH, Wells WJ, Jonas RA, Pigula FA, Manning PB, et al. Determinants of mortality and type of repair in neonates with pulmonary atresia and intact ventricular septum. *J Thorac Cardiovasc Surg* 2004; 127:1000-7.
5. Jahangiri M, Zurakowski D, Bichell D, Mayer JE, del Nido PJ, Jonas RA. Improved results with selective management in pulmonary atresia with intact ventricular septum. *J Thorac Cardiovasc Surg* 1999; 118:1046-55.
6. Daubeney PE, Delany DJ, Anderson RH, Sandor GG, Slavik Z, Keeton BR, et al. Pulmonary atresia with intact ventricular septum. range of morphology in a population-based study. *J Am Coll Cardiol*. 2002; 39:1670-9.
7. Miyaji K, Murakami A, Takasaki T, Ohara K., Takamoto S, Yoshimura H. Does a bidirectional Glenn shunt improve the oxygenation of right ventricle-dependent coronary circulation in pulmonary atresia with intact ventricular septum? *J Thorac Cardiovasc Surg* 2005; 130:1050-3.
8. Mair DD, Julsrud PR, Puga FJ, Danielson GK. The Fontan procedure for pulmonary atresia with intact ventricular septum. operative and late results. *J Am Coll Cardiol* 1997; 29:1359-64.
9. Giglia TM, Mandell VS, Connor AR, Mayer JE, Lock JE. Diagnosis and management of right ventricle-dependent coronary circulation in pulmonary atresia with intact ventricular septum. *Circulation* 1999; 86:1516-28.
10. Reddy VM, McElhinney DB, Moore P, Haas GS, Hanley FL. Outcomes after bidirectional cavopulmonary shunt in infants less than 6 months old. *J Am Coll Cardiol* 1997; 29:1365-70.