

Surgical Catheterization of Inferior Vena Cava for Emergent Hemodialysis



Turan Ege¹, Özcan Gür¹, Selami Gürkan¹, Demet Özkaramanlı Gür²

¹Namik Kemal University Research and Training Hospital, Department of Cardiovascular Surgery, Tekirdağ, Turkey

²Tekirdağ State Hospital, Clinic of Cardiology, Tekirdağ, Turkey

ABSTRACT

Arteriovenous fistula or central venous catheterization carries vital importance for hemodialysis which is an important treatment option in patients with chronic renal failure. In patients without an arteriovenous fistula providing adequate flow, a central venous catheter is required for emergent hemodialysis. In case of terminal access problems due to arterial or venous occlusions, catheterization of the inferior vena cava or the heart may be performed. Here we present two cases with terminal access problems in whom we performed surgical catheterization of the inferior vena cava.

Key Words: Chronic renal failure; hemodialysis; catheter

Acil Hemodiyaliz için Vena Cava Inferior'un Cerrahi Kateterizasyonu

ÖZET

Kronik böbrek yetersizliği olgularında, önemli tedavi seçeneği olan hemodiyaliz için arteriyovenöz fistül veya santral venöz kateterizasyon hayati önem taşır. Yeterli debi sağlayan arteriyovenöz fistülü olmayan olgularda acil hemodiyaliz için santral venöz katetere ihtiyaç vardır. Arteriyel veya venöz oklüzyonlar nedeniyle yaşanan "terminal access" problemlerinde son seçenek olarak vena cava inferior'un veya kalbin kateterizasyonu yapılabilir. Bu yazımızda, "terminal acces" problemi yaşadığımız ve cerrahi olarak vena cava inferior'un kateterizasyonunu yaparak yaşam sürelerini uzattığımız iki olguyu sunmayı amaçladık.

Anahtar Kelimeler: Kronik renal yetersizlik; hemodiyaliz; kateter

INTRODUCTION

Vascular access problem is a major cause of morbidity in patients receiving long-term hemodialysis. As the number of patients with chronic renal failure (CRF) increases, the so called "terminal access problems" become more common. Central venous catheters are often necessary for dialysis, and easily accessed vessels like internal jugular vein, femoral vein or subclavian vein frequently occlude due to repeated cannulation⁽¹⁾. Central vein stenosis can also jeopardize the future of arteriovenous fistulas and arteriovenous grafts in the ipsilateral extremity⁽²⁾. When standard access sites occlude, unconventional access methods become necessary. Here we report an extreme vascular access problem, which was successfully treated with the surgical catheterization of the inferior vena cava (IVC).

CASE REPORT

Clinical Series

Case 1

A 51 years old male diabetic patient who suffered from CRF for 7 years and had history of repeated vascular cannulations on both arms, femoral veins and central venous catheters in the past, had finally resulted in central venous stenosis. Peritoneal dialysis was not available because of umbilical hernia and chronic obstructive pulmonary disease (COPD). For an attempt to provide vascular access for hemodialysis, a femoro-femoral arterio-venous politetrafluoroetilen (PTFE) graft was implemented on his left groin which also failed after 4 weeks because of thrombosis of the ipsilateral iliac vein.

At that stage the patient needed an adequate vascular access for immediate

Correspondence

Turan Ege

E-mail: turanege@hotmail.com

Submitted: 07.02.2013

Accepted : 01.07.2013

@Copyright 2014 by Koşuyolu Heart Journal - Available on-line at www.kosuyolukaldergisi.com

haemodialysis. Upper and lower extremity venography was done before the decision on the site of a new vascular access. Venography, however, revealed occluded bilateral subclavian and jugular veins as well as an occluded left iliac vein. Right iliac vein and IVC was visualised to be open (Figure 1). Patient then was taken to the operation theatre for the catheterization

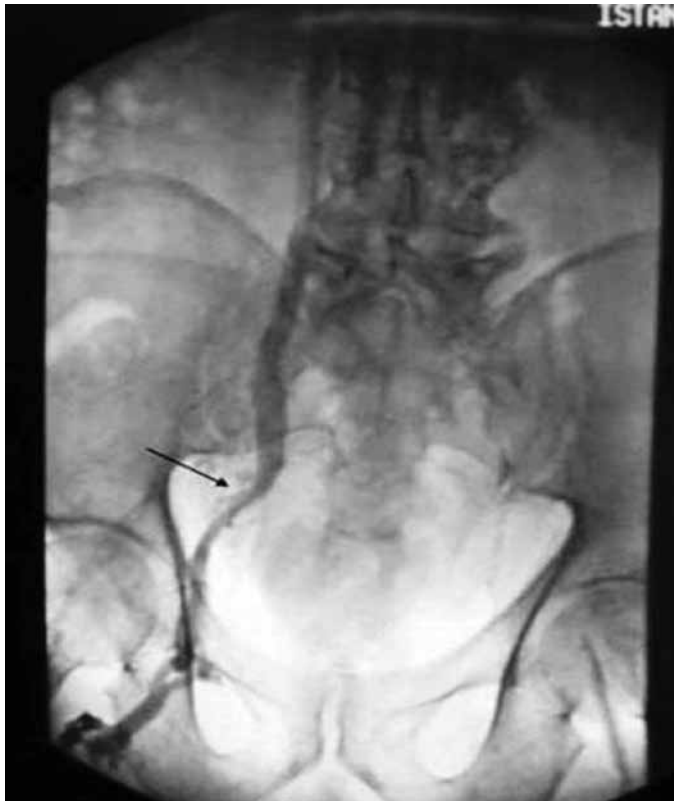

Figure 1. Magnetic resonance venography (Case 1), black arrow: iliac vein

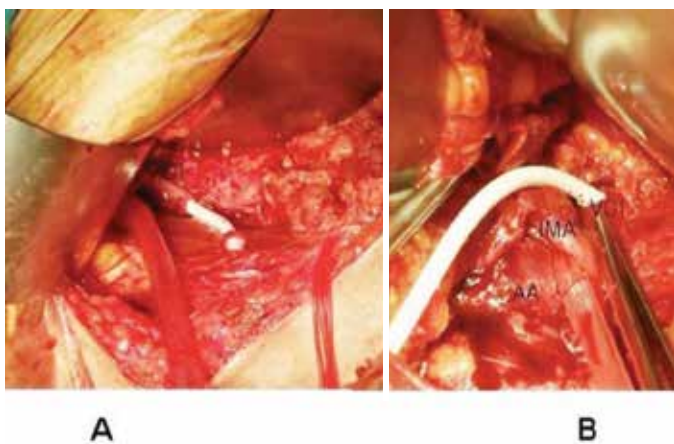


Figure 2. Vena cava inferior catheterization (Case 1),
 A : Right lateral abdominal incision
 B : Left lateral incision
 VCI : Vena cava inferior
 AA : Abdominal aorta
 IMA : Inferior mesenteric artery

of the right iliac vein. The exploration of the iliac vein through right lateral abdominal incision above the inguinal ligament revealed a scarred and thickened venous wall with organised thrombi within. Therefore the incision was enlarged to explore the IVC. A permanent double-lumen cuffed catheter (Cuffed Silicone Dual Lumen Catheter 13,5 F, Tyco, Switzerland) was inserted into the lower portion of the vein and its tip was advanced up to the hepatic veins (Figure 2A). A subcutaneous tunnel then was created so the catheter came out at the anterior axillary line superior to the inguinal ligament. No perioperative or postoperative complication occurred and hemodialysis could be done on the first postoperative day. The drainage tube was removed on the third postoperative day. At four months of follow up, however, the catheter was occluded.

Therefore patient was taken to another operation under general anesthesia. After removing the occluded right sided catheter, through a left lateral abdominal incision, the IVC was approached via an extraperitoneal route. A permanent double-lumen cuffed catheter (Cuffed Silicone Dual Lumen Catheter 13,5 F, Tyco, Switzerland) was placed into IVC using the same operative techniques (Figure 2B). Three days after the operation, hemodialysis could easily be achieved. At three months of follow up, the catheter worked excellently three times a week.

Case 2

A 66 years old male patient who was scheduled to have hemodialysis 3 times a week for 9 years was referred to our clinic for ineffective hemodialysis. The patient had a history of multiple upper extremity arteriovenous shunt operations and placement of a synthetic graft between right femoral vein and artery for the purpose of the hemodialysis, all of which had failed recently. Before an attempt to place central venous catheter, an ultrasonographic examination was carried out to evaluate the patency of the subclavian, jugular and femoral veins, all of which was revealed to be occluded. The magnetic resonance venography confirmed the diagnosis. Peritoneal dialysis was not an option for this patient for he had several

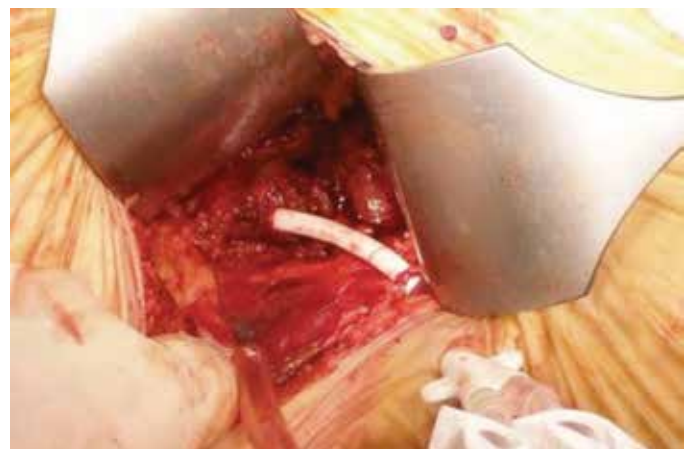

Figure 3. Vena cava inferior catheterization by right lateral abdominal incision. (Case 2), VCI: Vena cava inferior

abdominal operations in the past. Consequently, the decision of an IVC catheterization was made, and a double lumen hemodialysis catheter (Cuffed Silicone Dual Lumen Catheter 13.5 F, Tyco, Switzerland) was placed through right lateral abdominal incision with the method described. A successful hemodialysis was carried out on the first postoperative day. The catheter was still patent on the 5. postoperative month.

DISCUSSION

The management of CRF includes hemodialysis, peritoneal dialysis and renal transplantation. When peritoneal dialysis or renal transplantation is not available, the patient relies only on hemodialysis for survival. Hemodialysis, on the other hand, requires a vascular access like an arteriovenous fistula, central venous catheters or fistula constituted by synthetic grafts⁽³⁾. In our cases, who suffered from terminal access problems, placement of an IVC catheter were lifesaving.

In terminal access problems, where all possible vascular access solutions seem to be exhausted and the patient's life is threatened, every effort should be made to describe the arteriovenous anatomy of the patient and to choose appropriate vascular Access site. Several proposals have already been described with regard to the upper limbs and central veins^(3,4).

Vascular ultrasonography and venography are effective tools to evaluate the thrombotic occlusions or anatomic variations before the procedure⁽⁵⁾. It is specially beneficial in patients with a history of multiple arteriovenous fistula operations, or central venous catheter insertion. In both of our cases, the imaging modalities excluded all possible Access sites except IVC.

The literature provides a plethora of different percutaneous catheterization solutions for the dialysis patient in need of a chronic vascular access, such as parasternal, translumbar, transrenal, transhepatic or even intracardiac catheterization. There are some reports of direct translumbar catheterization of the IVC, but these methods require an experienced radiology team as well as an adequately equipped angiographic suite

and patient conformity^(6,7). Since interventional radiological procedures are not available in our clinic, we performed surgical catheterization of the IVC without any complications, and provided a vascular access to our patients on the first postoperative day. We can conclude that it is a safe and efficient method with low mortality and morbidity.

Surgical catheterization of IVC in emergency situations is rarely reported in the literature⁽⁸⁾. In one of our patients, the first catheter was occluded on the third month and had to be replaced. The replacement of the catheter was done through a left lumbar incision above the abdominal aorta. This proves that both right and left sided incisions are possible for placement of IVC catheter.

Surgical catheterization of IVC is a safe and efficient alternative method of vascular access for patients with terminal vascular access problem and in need of emergency hemodialysis.

CONFLICT of INTEREST

The authors reported no conflict of interest related to this article.

REFERENCES

1. Wellons ED, Matsuura J, Lai KM, Levitt A, Rosenthal D. Transthoracic cuffed hemodialysis catheters: a method for difficult hemodialysis access. *J Vasc Surg* 2005;42:286-9.
2. Agarwal AK, Patel BM, Haddad NJ. Central Vein Stenosis: A Nephrologist's Perspective. *Semin Dial* 2007;20:53-62.
3. Huber TS, Seeger JM. Approach to patients with 'complex' hemodialysis access problems. *Semin Dial* 2003;16:22-9.
4. Nicholson ML. Provision of long-term vascular access for haemodialysis in a patient with exhausted superficial arm veins. *Br J Surg* 2001;88:484-5.
5. Taal MW, Chesterton LJ, McIntyre CW. Venography at insertion of tunnelled internal jugular vein dialysis catheters reveals significant occult stenosis. *Nephrol Dial Transplant* 2004;19:1542-5.
6. Weeks SM. Unconventional venous access. *Tech Vasc Interv Radiol* 2002; 5:114-120.
7. Lund GB, Trerotola SO, Scheel PJ Jr. Percutaneous translumbar inferior vena cava cannulation for hemodialysis. *Am J Kidney Dis* 1995;25:732-7.
8. Matsagas MI, Gouva CD, Charissis C, Katopodis KP, Fatouros M, Kappas AM. Vascular Access for haemodialysis in extreme situations: surgically placed inferior vena cava catheter. *Nephrol Dial Transplant* 2004;19:752-3.