

Beware of an Intracranial Neoplasm during Exercise Electrocardiography Test

Egzersiz Elektrokardiyografi Testi Sırasında İntrakranial Neoplazmın Farkında Olun

Turhan Turan¹, Ahmet Çağrı Aykan¹, Ali Rıza Akyüz²

¹ Ahi Evren Chest Cardiovascular Surgery Education and Research Hospital, Clinic of Cardiology, Trabzon, Turkey

² Akçaabat State Hospital, Clinic of Cardiology, Trabzon, Turkey

A 58-year old man without history of previous chronic disease presented to urology outpatient clinic with benign prostate hyperplasia (BPH) symptoms. An elective surgery was scheduled and pre-operative cardiology consultation was requested. He reportedly had exercise intolerance, dyspnea and chest pain for the past two months. Physical examination, echocardiography, and electrocardiography (ECG) were normal. An exercise ECG test was performed for further evaluation. Exercise was terminated at 9 minutes due to fatigue. Pallor, cold sweating, confusion and vomiting developed soon after the termination of exercise. There were no ECG changes or hypotensive episodes during the exercise test (Figure 1). The post-exercise ECHO was normal. An elevation of blood pressure to 164/81 mmHg occurred after the exercise test from a basal reading of 120/80 mmHg. Fundoscopic examination suggested increased intracranial pressure. Thus, cranial computed tomography (CT) and magnetic resonance imaging (MR) were performed, which demonstrated a 63 x 41 mm mass located in the right fronto-basal area (Figure 2 and Figure 3 A, B respectively). The patient was referred to the neurosurgery. The mass was excised and histopathologic evaluation showed metastatic malign melanoma, which was subsequently treated by radiotherapy.

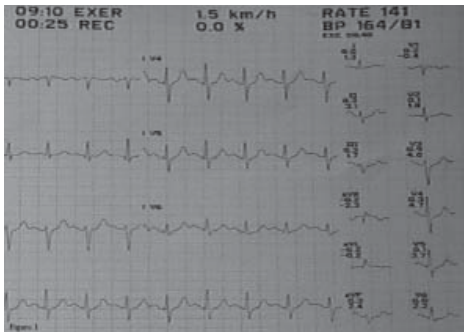


Figure 1. Unchanged electrocardiography and undiminished blood pressure at the end of exercise ECG.

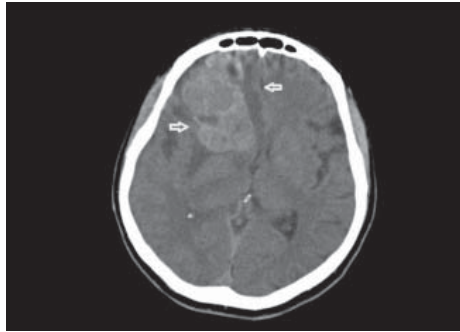


Figure 2. A mass in the right frontobasal region of cranial CT (between the arrows).

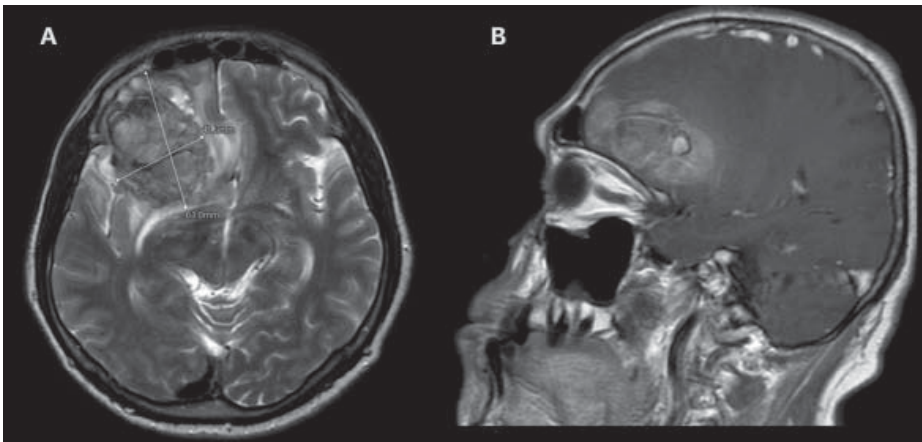


Figure 3. MR image of the 63 x 41 mm mass in the right frontobasal area.



Correspondence

Turhan Turan

E-mail: drtt61@gmail.com

Submitted: 12.05.2014

Accepted: 14.05.2014

© Copyright 2015 by Koşuyolu Heart Journal.
Available on-line at
www.kosuyoluheartjournal.com