



A Patient with Wolff-Parkinson-White Syndrome with No Delta Wave

Taylan Akgün¹, Yeliz Güler¹, Semi Öztürk¹, Seyfettin Gürbüz¹, Ahmet Güler¹

¹ Kartal Koşuyolu High Specialization Training and Research Hospital, Clinic of Cardiology, İstanbul, Turkey

ABSTRACT

We present a 16-year-old patient with Wolff-Parkinson-White syndrome admitted with syncope and aborted sudden cardiac death. Electrocardiography showed only a short PR interval without a delta wave. The QRS transition zone was on V2 in the precordial leads. Twenty-four-hour ambulatory cardiac rhythm monitoring showed an obvious delta wave only at night-time. Electrophysiologic testing was performed and a right antero-septal accessory pathway was ablated from the noncoronary aortic cusp. ECG after ablation showed sinus rhythm with right bundle branch block morphology, with no obvious change in the PR duration.

Key Words: Wolff-Parkinson-White syndrome; sudden cardiac arrest

Delta Dalgası Olmayan Wolf-Parkinson-White Sendromlu Bir Hasta

ÖZET

Bu yazıda senkop ve önlenmiş ani kardiyak ölüm ile yatırılan, Wolff-Parkinson-White sendromlu 16 yaşında bir hasta sunuldu. Elektrokardiyografide delta dalgası olmadan yalnızca kısa PR süresi izlendi. QRS geçiş zonu V2'de idi. Yirmi dört saatlik kalp ritim takibinde, yalnızca gece saatlerinde belirgin olan delta dalgası izlendi. Elektrofizyolojik test ile birlikte nonkoroner aortik kasp bölgesinden sağ antero-septal aksesuar yol ablasyonu yapıldı. Ablasyon sonrası EKG'de normal sinüs ritmi ve sağ dal bloku morfolojisi izlendi; PR süresinde belirgin bir değişiklik yoktu.

Anahtar Kelimeler: Wolff-Parkinson-White sendromu; ani kalp durması

INTRODUCTION

Sudden cardiac arrest and sudden cardiac death in children and adolescents are relatively rare. The causes of sudden cardiac arrest are broad, but the most common cause in patients between 13 and 24 years of age is primary arrhythmia⁽¹⁾. Wolff-Parkinson-White (WPW) syndrome is one of the rare causes of sudden cardiac death. The slurring of the QRS complex (delta wave) is actually the impulse making it through to the ventricles prematurely (across the accessory pathway) without the usual delay seen in the AV node. But this delta wave may be "hidden" in the normal QRS complex in patients with very fast AV node conduction or small cardiac chambers⁽²⁾. We described a patient with WPW syndrome without a delta wave.

CASE REPORT

A 16 year old male patient was admitted with palpitations and syncope. A 12-lead electrocardiogram (ECG) showed a short PR interval (Figure 1). There was no slurred upstroke in the QRS complex that is associated with WPW syndrome. PR and QRS durations were 90 msec and 110 msec, respectively. Although only a short PR interval was evident in day-time, there were brief episodes of the delta wave at night (Figure 2). Electrophysiological testing was planned. Two 7F sheaths were inserted into the femoral vein and a coronary sinus catheter and a diagnostic catheter were placed into the coronary sinus and HRA, respectively. The earliest ventricular activation was seen on the CS proximal electrode. Atrial pacing at 500/200 msec and 500/180 msec showed an accessory pathway and atrioventricular node block, respectively. Mapping was performed by an ablation catheter to find out the accessory pathway localization. The earliest ventricular activation was observed at the right ventricular antero-septal region, but radiofrequency catheter (RF) ablation was not performed due to the close proximity to the His

Correspondence

Ahmet Güler

E-mail: ahmetguler01@yahoo.com.tr

Submitted: 25.10.2013

Accepted: 29.10.2013

@ Copyright 2015 by Koşuyolu Heart Journal.
Available on-line at
www.kosuyoluheartjournal.com

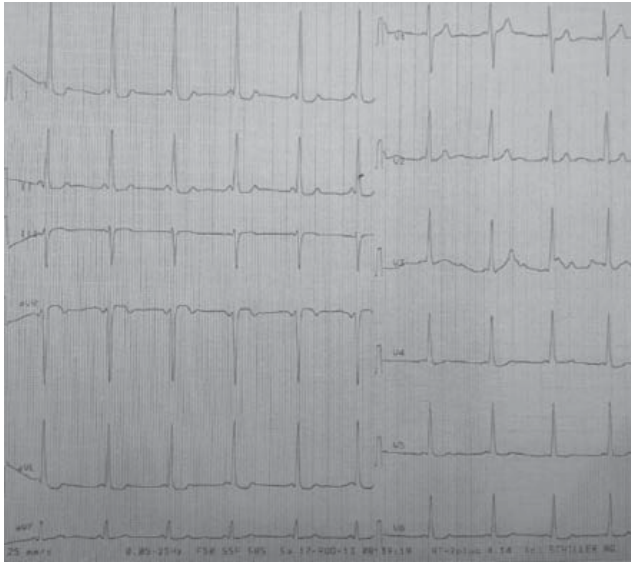


Figure 1. 12-lead ECG shows a short PR (90 msec) and a normal QRS duration (110 msec).

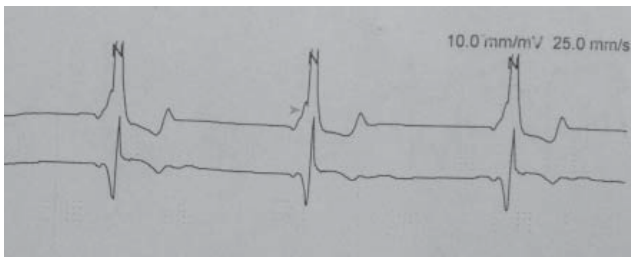


Figure 2. 24-hour ambulatory ECG monitoring shows the delta wave (red arrowhead) and a widened QRS at sleeping time.

region. Aortic sinuses were searched with the RF catheter for the accessory pathway and successful ablation of the accessory pathway was achieved in the noncoronary aortic cusp and preexcitation disappeared at 10 seconds of ablation. ECG obtained after ablation showed sinus rhythm with right bundle branch block morphology, with no obvious change in the PR duration (Figure 3).

DISCUSSION

Wolff-Parkinson-White Syndrome is commonly diagnosed on the basis of the electrocardiogram in an asymptomatic individual. The short PR interval and slurring of the QRS complex are the main findings. However, the normal PR interval duration is shorter in children and increases with age. This

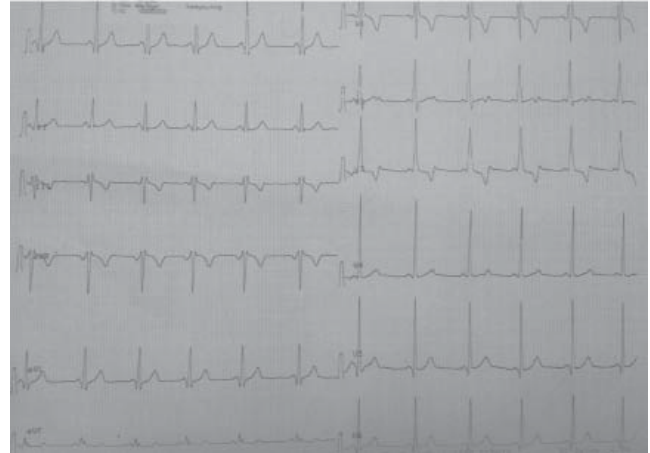


Figure 3. Electrocardiogram after ablation of the accessory pathway.

finding may be the result of smaller cardiac muscle mass or rapid AV conduction. The normal PR interval duration can be as short as 80 msec in neonates. Because of this rapid conduction, it may be difficult to see the delta wave in children while it is hidden in the QRS complex. The accessory pathway does not share the rate-slowing properties of the AV node, and may conduct electrical activity at a significantly higher rate than the AV node. Extremely rapid atrial rates may be conducted to the ventricles over the accessory pathway and may result in hemodynamic instability. The conduction velocity is decreased in the AV node by the augmented vagal activity at night. This results in early activation of “more” of the ventricle over the accessory pathway, making the delta wave more obvious. Finally, in these cases, careful examination of the ambulatory cardiac rhythm monitoring is helpful to detect the obscured delta wave.

In conclusion, in cases with fast AV and accessory pathway conduction, WPW syndrome can be misdiagnosed as a short PR interval. In this particular situation, ambulatory ECG monitoring may help us spot the delta wave at night-time when the vagal tone is increased. Ablation therapies may be a curative option.

REFERENCES

1. Meyer L, Stubbs B, Fahrenbruch C, Maeda C, Harmon K, Eisenberg M, et al. Incidence, causes, and survival trends from cardiovascular-related sudden cardiac arrest in children and young adults 0 to 35 years of age: a 30-year review. *Circulation* 2012;126:1363-72.
2. Pahlajani DB, Miller RA, Serratto M. Patterns of atrioventricular conduction in children. *Am Heart J* 1975;90:165-71.