



## Hiatal Hernia Repair during Coronary Artery Bypass Surgery

### Koroner Baypas Cerrahisi ile Beraber Hiatus Hernisi Onarımı

Hasan Reyhanoğlu<sup>1</sup>, Kaan Özcan<sup>1</sup>, Hidayet Çatal<sup>2</sup>, Suna Güzeldoğan<sup>2</sup>, Ümit İlker Tekin<sup>3</sup>

<sup>1</sup> Tinaztepe Hospital, Clinic of Cardiovascular Surgery, İzmir, Turkey

<sup>2</sup> Tinaztepe Hospital, Clinic of General Surgery, İzmir, Turkey

<sup>3</sup> Tinaztepe Hospital, Clinic of Cardiology, İzmir, Turkey

Hiatal hernia is defined as the displacement of a portion of the stomach through the diaphragmatic esophageal hiatus to the thorax, resulting in various symptoms. A 61-year-old male patient was admitted with chest pain and occasional progressive shortness of breath. Following a chest CT scan and coronary angiography, a decision for surgery was made (Figure 1). After a median sternotomy, a hiatal hernia was seen (Figure 2 and 3). The sternotomy incision was extended by the general surgeon, and the defect was repaired with a 15 x 15 cm dual mesh. After hernia repair, coronary bypass surgery (LIMA-LAD, Ao-D1, Ao-RCA bypasses) was performed with cardiopulmonary bypass. The patient was discharged on the fifth postoperative day without any problems. It is important to consider hiatal hernia among extra-cardiac factors in patients presenting with chest pain.

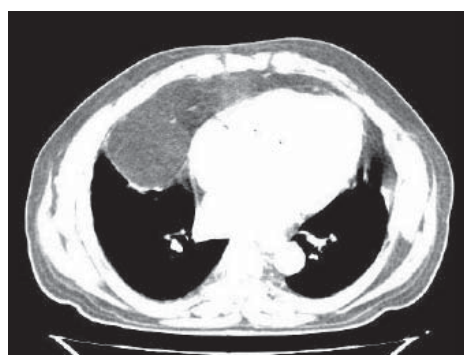

Figure 1. A preoperative thorax CT image.

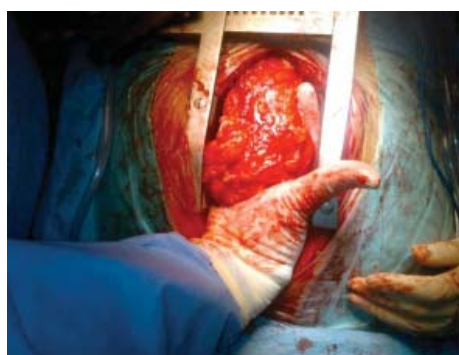

Figure 2. A perioperative view of the mediastinum.

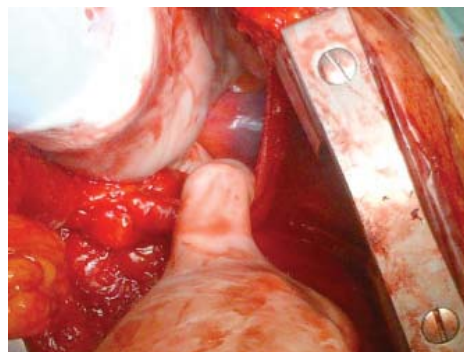


Figure 3. A perioperative view of the intra-abdominal organs from the mediastinum.

#### Correspondence

Hasan Reyhanoğlu

E-mail: hreyhanoglu@hotmail.com

Submitted: 12.09.2015

Accepted: 05.10.2015

© Copyright 2015 by Koşuyolu Heart Journal.  
Available on-line at  
www.kosuyoluheartjournal.com