

Extraction of a Proximal Portion of a Fractured Lead Using a Bulldog Lead Extender in a Patient with Recurrent Septicaemia Following Incomplete Removal of Pacemaker Leads



Mehmet Ali Astarcioglu, Taner Şen, Halil İbrahim Durmuş, Muhammed Oylumlu, Celal Kilit, Basri Amasyalı

Dumlupınar University Faculty of Medicine, Department of Cardiology, Kütahya, Turkey

ABSTRACT

Pacemaker lead infection is a rare but serious complication of permanent transvenous pacing, and the prognosis is serious if all the implanted materials are not completely removed. In this case report, we aim to describe the management of a fractured pacemaker lead caused by the extraction procedure using a bulldog lead extender.

Key Words: Endocarditis; pacing; pacemakers

Proksimal Kısmı Kırık Kalp Pili Telinin Eksik Çıkarılmasını Takiben Tekrarlayan Septisemisi Olan Bir Hastada Bulldog Tel Genişleticinin Kullanılması

ÖZET

Kalp pili teli enfeksiyonu ven aracılı kalıcı pil implantasyonunun nadir fakat ciddi bir komplikasyondur ve implante edilen malzeme tamamen kaldırılmazsa prognoz oldukça kötüdür. Biz burada bulldog tel genişletici kullanarak kırık bir kalp pili telinin çıkarılma prosedürünü tanımlamayı amaçladık.

Anahtar Kelimeler: Endokardit; pacing; kalp pilleri

INTRODUCTION

Pacemaker (PM) lead infection is a rare but serious complication of permanent transvenous pacing and may be associated with infective endocarditis if all implanted materials are not completely removed. The transvenous extraction of endocardial leads may be challenging and may cause complications. In this case report, we aim to describe the management of a fractured PM lead caused by the extraction procedure using a bulldog lead extender.

CASE REPORT

A 73-year-old patient who had a history of DDD-ICD PM implantation with a bipolar active fixation lead 7 years ago was admitted to the hospital with persisting high fever (39.6°C), chills and increased white blood cell counts and sedimentation rates.

His medical history revealed that he suffered several episodes of *Staphylococcus epidermidis* and *Staphylococcus aureus* septicaemia without concomitant infective endocarditis and infection of the generator pocket 3 years ago, after the incomplete removal of the pacing system (Figure 1). The atrial lead and generator were then successfully removed; however, the ventricular lead could not be retracted because of severe adhesions. Meanwhile, the blood cultures were negative, and the battery was sterilised and re-implanted, but local infection persisted. TTE and TEE studies did not reveal any vegetation or mass.

On current admission, the patient was positive for methicillin-sensitive *S. aureus*. He was initially treated with high-dose intravenous antibiotics. Manual traction was attempted at this point using the normal stylet; however, the lead could not be pulled through adhesions in the brachiocephalic vein. The bulldog lead extender (Cook Medical, Bloomington, IN) was used to extract the right ventricular ICD lead because the proximal tip of the lead was broken (Figure 2). Permanent cure was finally obtained after the complete removal of the PM material (Figure 3). After 2 weeks of antibiotic treatment, a new transvenous DDD-ICD PM was implanted via the right subclavian vein. A follow-up of 1 year was uneventful.

Correspondence

Mehmet Ali Astarcioglu

E-mail: maliastarcioğlu@hotmail.com

Submitted: 23.04.2014

Accepted: 06.05.2014

@ Copyright 2016 by Koşuyolu Heart Journal.
Available on-line at
www.kosuyoluheartjournal.com

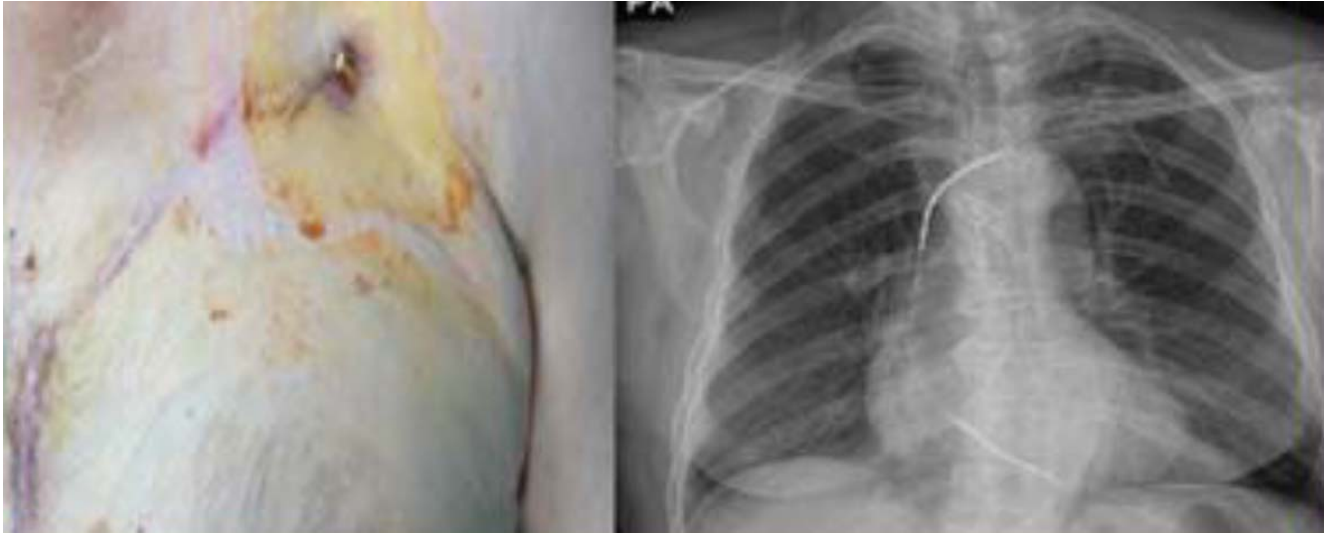


Figure 1. Chronic severe local infection and ICD pacing lead.

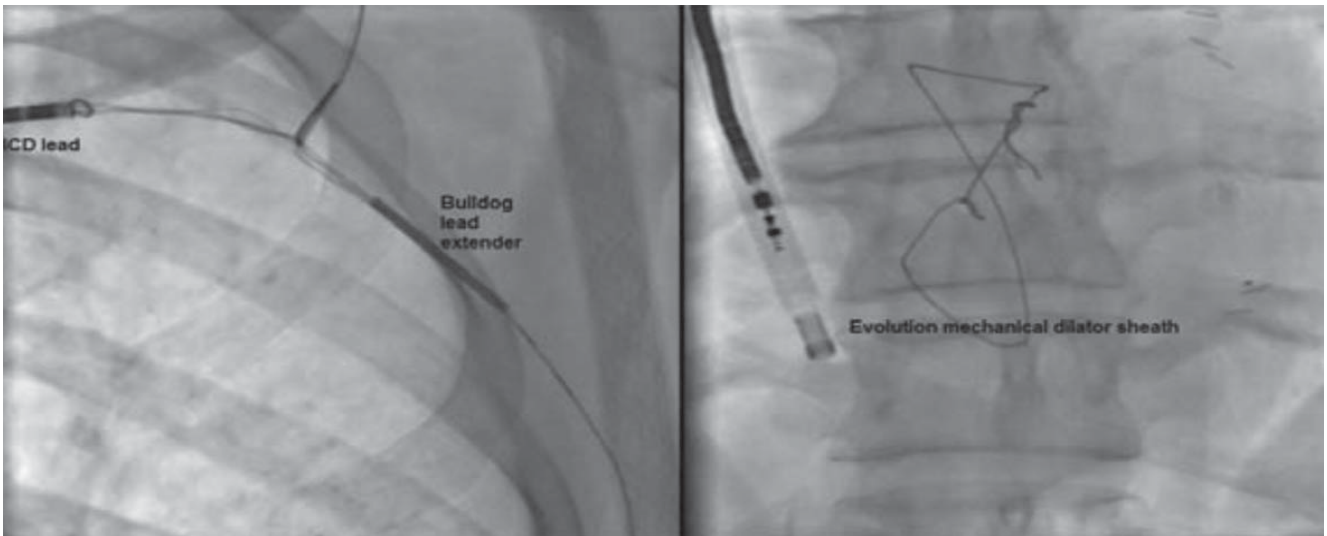


Figure 2. Extraction of the ICD lead via mechanical dilator sheath and bulldog lead extender.

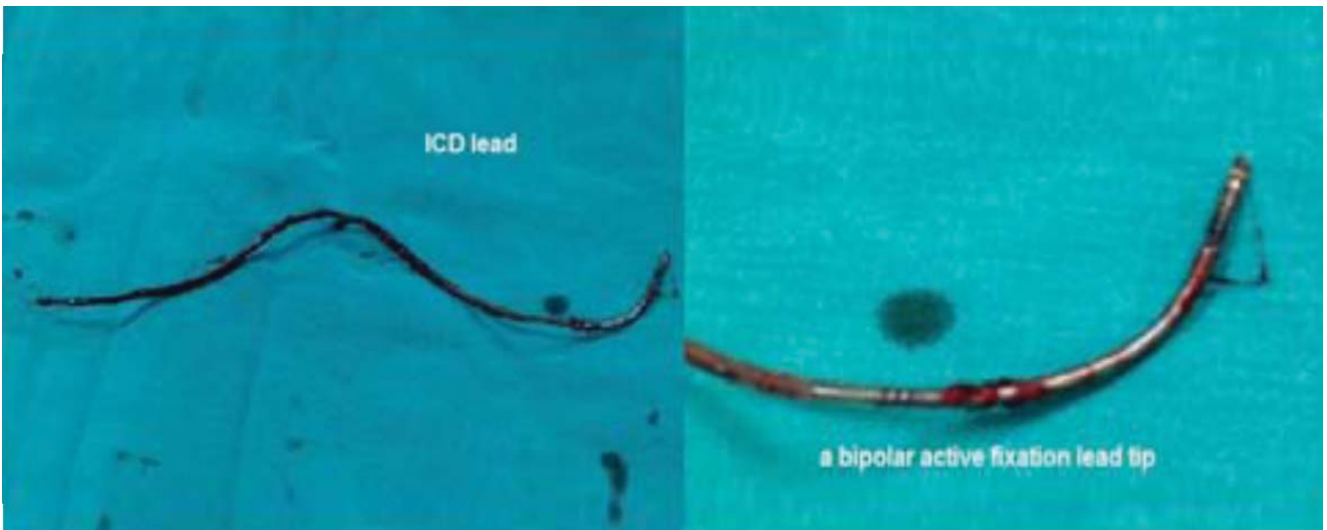


Figure 3. The extracted ICD lead.

DISCUSSION

The incidence of infection of the permanent PM system is between 0.3% and 12.6%. This may include an infection of the battery pocket or an infection of the electrodes and can possibly be related with bacteraemia, with or without accompanying infective endocarditis. Documented septicaemia is rare (1%-3%)⁽¹⁾. PM lead infection is a life-threatening situation. Haematogenous dissemination can produce relapsing septic episodes, pulmonary symptoms from emboli and involvement of the tricuspid valve leading to regurgitation or rarely stenosis. Most PM lead infections are caused by *Staphylococci*; other micro-organisms may also be responsible. Early infections after an implantation may be caused by *S. aureus*, whereas late infections are caused by *S. epidermidis*⁽²⁾.

In conclusion, septicaemia because of endocardial PM leads is uncommon, but the presentation is insidious and prognosis is serious if all the implanted materials are not completely removed.

REFERENCES

1. Vilacosta I, Zamorano J, Camino A, San Roman JA, Rollan MJ, Pinto A, et al. Infected transvenous permanent pacemakers: role of transoesophageal echocardiography. *Am Heart J* 1993;125:904-6.
2. Klug D, Lacroix D, Savoye C, Goullard L, Grandmougin D, Hennequin JL, et al. Systemic infection related to endocarditis on pacemaker leads. *Circulation* 1997;95:2098-107.