



## Mitral Valve Neurofibroma in A Patient with Neurofibromatosis Type 1: A Rare

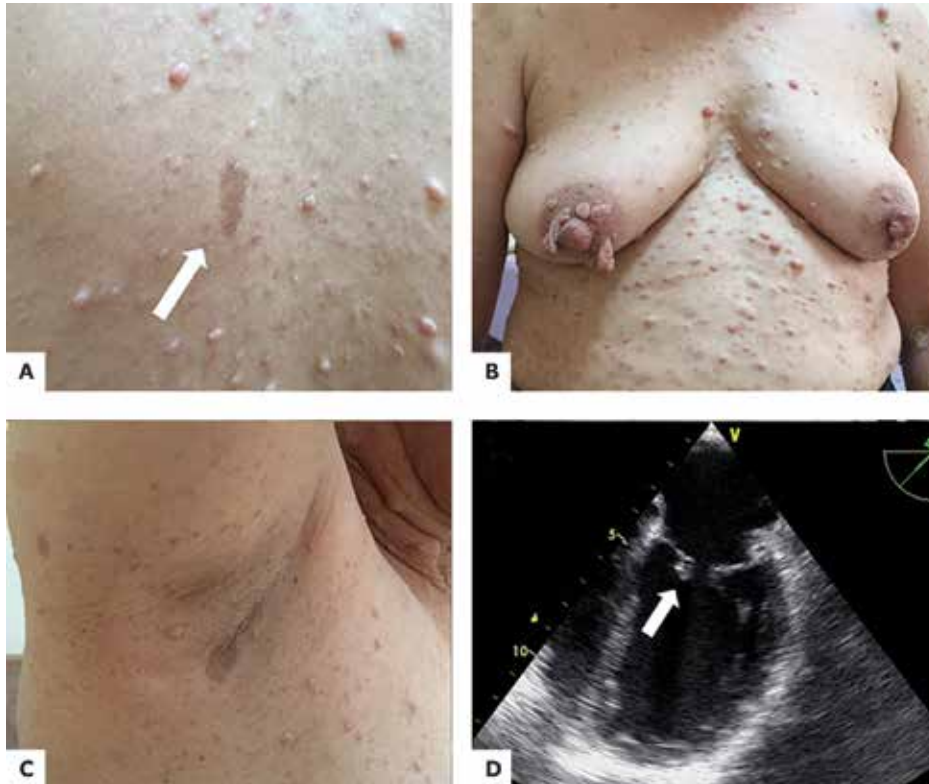### Nadir Bir Durum: Nörofibromatozis Tip 1'li Bir Olguda Mitral Kapakta Nörofibrom

Ali Rıza Akyüz<sup>1</sup>, Levent Korkmaz<sup>1</sup>, Turhan Turan<sup>1</sup>, Burak Akşan<sup>2</sup>

<sup>1</sup> University of Health Sciences, Ahi Evren Chest Cardiovascular Surgery Training and Research Hospital, Clinic of Cardiology, Trabzon, Turkey

<sup>2</sup> Akçaabat Haçkalı Baba State Hospital, Clinic of Dermatology, Trabzon, Turkey

A 53-year-old female with neurofibromatosis type 1 (NF-1) was evaluated because of shortness of breath. Her physical examination revealed numerous cafe-au-lait macules (Figure 1A), cutaneous neurofibromas over her whole body (Figure 1B) and axillary freckles (Figure 1C). During her cardiac examination, a grade 3/6 systolic murmur was detected on mitral focus. Echocardiography revealed moderate mitral regurgitation. To conduct a detailed examination, transoesophageal echocardiography was performed. It showed moderate mitral regurgitation (Figure 2) and a 6 × 8 mm anterior mitral valve nodule (Figure 1D). Taking into account the patient's cutaneous neurofibromas, we assumed that the nodule on the mitral valve was a neurofibroma. Further examination with CT or MRI was suggested, but the patient refused it.



**Figure 1.** Numerous cafe-au-lait macules (A), cutaneous neurofibromas (B), and axillary freckles (C), transoesophageal echocardiography demonstrated an anterior mitral neurofibroma (D).

#### Correspondence

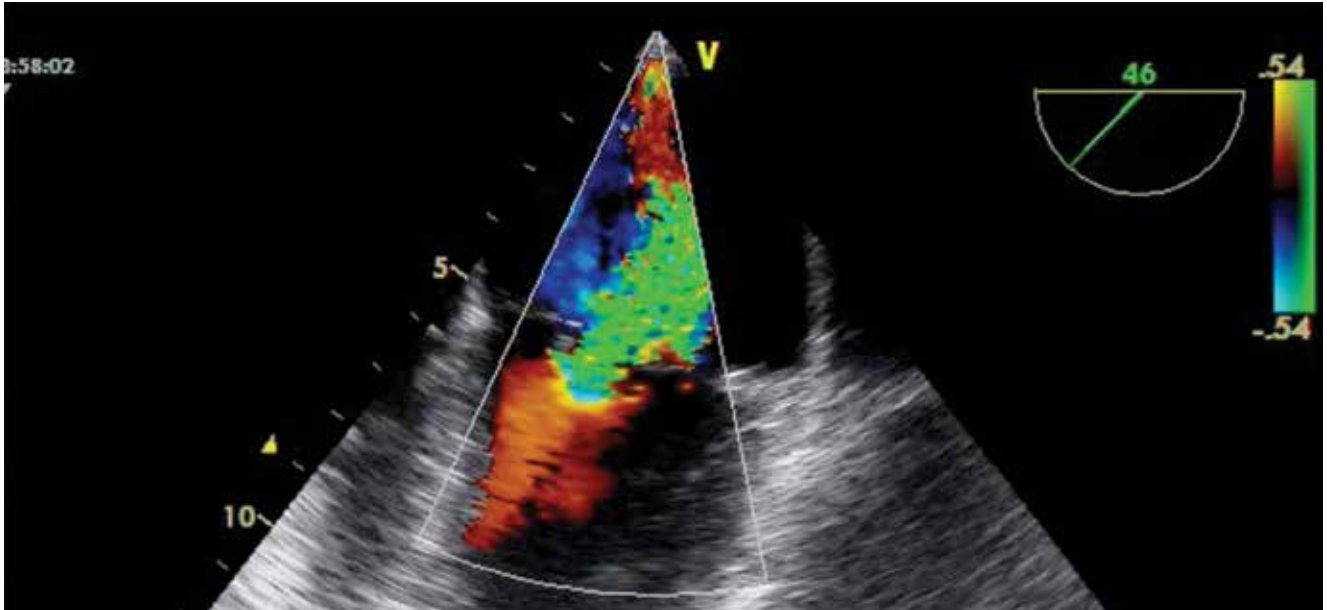
Ali Rıza Akyüz

E-mail: dralirizaakyuz@gmail.com

Submitted: 24.03.2016

Accepted: 12.04.2016

@ Copyright 2016 by Koşuyolu Heart Journal.  
Available on-line at  
www.kosuyoluheartjournal.com



**Figure 2.** Transoesophageal echocardiography demonstrated mitral regurgitation.