



Serial Fluoroscopy Guided Fibrinolytic Therapy in a Patient with Obstructive Mechanical Aortic Valve Thrombosis

Macit Kalçık¹, Mahmut Yesin¹, Mustafa Ozan Gürsoy¹, Mustafa Yıldız², Mehmet Özkan³

¹ Kartal Koşuyolu High Specialization Training and Research Hospital, Clinic of Cardiology, Istanbul, Turkey

² Istanbul University Faculty of Medicine, Department of Cardiology, Istanbul, Turkey

³ Kafkas University Faculty of Medicine, Department of Cardiology, Kars, Turkey

ABSTRACT

Prosthetic valve thrombosis is a life-threatening complication, which is most commonly seen in patients with poor anticoagulation. Although two-dimensional and real-time three-dimensional transesophageal echocardiography are the gold standard imaging modalities for the diagnosis of prosthetic valve thrombosis, prosthetic valves in aortic position may not be evaluated precisely. This is a serious problem during the follow-up of the patients who receive thrombolytic therapy for aortic valve thrombosis. Fluoroscopy is an alternative noninvasive imaging method, which provides valuable information about leaflet motion and may be used for such cases with restricted leaflets. Here, we report a case of aortic valve thrombosis that was managed with low-dose (25 mg) and ultra-slow (25 hours) infusion of tissue-type plasminogen activator under the guidance of serial fluoroscopy.

Key Words: Fluoroscopy; prosthetic valve thrombosis; aortic valve; thrombolytic therapy; tissue-type plasminogen activator

Tıkayıcı Mekanik Aort Kapak Trombozu Olan Bir Hastanın Seri Floroskopi Kılavuzluğunda Pıhtı Eritici İlaç ile Tedavisi

ÖZET

Protez kapak trombozu genellikle yetersiz antikoagüle edilmiş hastalarda rastlanan hayatı tehdit edici bir komplikasyondur. Protez kapak trombozu tanısında 2-boyutlu ve gerçek zamanlı 3-boyutlu transözafajal ekokardiyografi altın standart görüntüleme yöntemleri olmasına rağmen, bu yöntemlerle aort konumundaki protez kapaklar çok net değerlendirilemeyebilir. Bu durum protez aort kapak trombozu nedeniyle trombolitik tedavi alan hastaların takibinde önemli bir problem oluşturur. Floroskopi bu şekilde kapak hareketlerinde kısıtlılık olan hastaların takibinde kapak hareketleri hakkında değerli bilgiler sunan alternatif noninvaziv görüntüleme yöntemidir. Burada bir protez aort kapak trombozu tanılı olguda seri floroskopi kılavuzluğunda düşük doz (25 mg) doku plazminojen aktivatörünün çok yavaş infüzyonu (25 saat) ile yapılan trombolitik tedaviyi sunmaktayız.

Anahtar Kelimeler: Floroskopi; protez kapak trombozu; aort kapak; trombolitik tedavi; doku plazminojen aktivatörü

INTRODUCTION

Prosthetic valve thrombosis is a rare but life-threatening complication, which is most commonly seen in patients with poor anticoagulation. Thrombolytic therapy (TT) and surgery are the first choice of treatments in obstructive prosthetic valve thrombosis. A low-dose (25 mg) and slow infusion (6 hours) of tPA can be successfully performed as an alternative treatment regimen to surgery for prosthetic heart valve thrombosis^(1,2). Two-dimensional (2D) and real-time three-dimensional (RT-3D) transesophageal echocardiography (TEE) are the gold standard imaging modalities for the diagnosis of prosthetic valve thrombosis. However, delineation of leaflet motions and thrombotic mass by TEE may not be satisfactory in all patients with prosthetic valves in aortic position leading to a noteworthy issue during the follow-up of the patients who receive TT for aortic valve thrombosis⁽³⁾. Fluoroscopy provides valuable information about leaflet motion and may be used in a serial manner for cases with restricted leaflets who receive TT⁽⁴⁾. Here, we present a case of aortic valve thrombosis that underwent thrombolysis by further prolonging the duration (25 hours) of the TT regimen with low-dose (25 mg) of tissue-type plasminogen activator (tPA) under the guidance of serial fluoroscopy.

Correspondence

Macit Kalçık

E-mail: macitkalcik@yahoo.com

Submitted: 28.05.2014

Accepted: 09.06.2014

@ Copyright 2016 by Koşuyolu Heart Journal.
Available on-line at
www.kosuyoluheartjournal.com

CASE REPORT

A 57-year-old woman was admitted to an outpatient clinic with a New York Heart Association functional class 2 dyspnea and palpitation existing for the past 3 weeks. She had undergone aortic valve replacement with a 21 no St. Jude Medical bileaflet mechanical valve 3 years earlier. Her chest radiogram was normal and electrocardiogram revealed sinus tachycardia. Laboratory findings were unremarkable except for subtherapeutic international normalised ratio (INR) under 7.5 mg/day warfarin therapy^(1,3). Transthoracic echocardiography (TTE) showed increased transvalvular gradients (81/51 mmHg) and decreased prosthetic valve area (0.41 cm²) obtained by continuous wave Doppler analysis (Figure 1A). Although 2D TEE and RT-3D TEE revealed a thrombus on the aortic mechanical prosthesis, the motion of mechanical bileaflets was not clearly assessed (Figure 2A, 2B). Left anterior oblique cranial fluoroscopy provided a side (pivot) view with the disks parallel to the X-Ray beams showing one leaflet fixed in closed position and mild motion restriction of the other leaflet (Figure 2C). TT with low-dose (25 mg) and ultra-slow infusion (25 hours) of tPA was performed. After 25 mg tPA infusion, 2D TEE and RT-3D TEE could not reveal any progression of thrombolysis or resolution of leaflet restriction (Figure 2D and 2E) but, fluoroscopy revealed slight movement of the stuck leaflet with normal motion of the other (Figure 2F). Doppler parameters were the same, so we performed another session of TT (25 mg/25 hours) after a 6-hour unfractionated heparin infusion. After totally 50 mg of tPA infusion, restriction of leaflets was nearly completely resolved on fluoroscopy (Figure 2I). TTE showed normally functioning prosthesis with decreased transvalvular gradients (42/25 mmHg) and increased valve area (0.95 cm²) (Figure 1B). 2D TEE and RT-3D TEE showed normally functioning mechanical aortic valve with the resolution of the thrombus burden (Figure 2G, 2H).

DISCUSSION

Despite the recent improvements in prosthetic valve technology and surgical procedures, valve replacement does not provide a definitive cure to the patient; instead, it gives rise to development of a new disease-prosthetic heart valve disease. One of the most life-threatening complications of mechanical prostheses is valvular obstruction by pannus, thrombus or both. The treatment of choice for mechanical valve obstruction was surgery until 1990s. Over the last decade, TT has been increasingly used and has become an alternative to surgery as the first line of therapy in patients with thrombosed mechanical valves. Low-dose and prolonged infusion time of tPA has recently contributed to the success of TT with decreased complication rates^(1,2). We hypothesised that further prolongation of the TT regimen could be associated with lower complication rates based on our experience in the TROIA trial⁽²⁾.

The role of transthoracic echocardiography is limited in the evaluation of valve obstruction and usually provides little information concerning the aetiology of the obstruction. TEE has become the procedure of choice for evaluating mechanical valve obstruction and is sometimes useful in distinguishing pannus from thrombus. However, TEE may not be sufficient for evaluation of leaflet motion and the cause of obstruction in patients with aortic valve obstruction.

Fluoroscopy is a noninvasive, readily available method for detecting prosthetic valve obstruction, especially in patients with bileaflet prosthetic valves⁽⁴⁾. In the case of bileaflet valves, the disks can be directly visualised, and opening and closing angles measured using a tangential view^(5,6). Fluoroscopy is the most widely used method for making the diagnosis of stuck valves⁽⁷⁾. Fluoroscopy is not useful in distinguishing pannus from thrombus since neither of them can be identified fluoroscopically. Moreover, fluoroscopy may be particularly

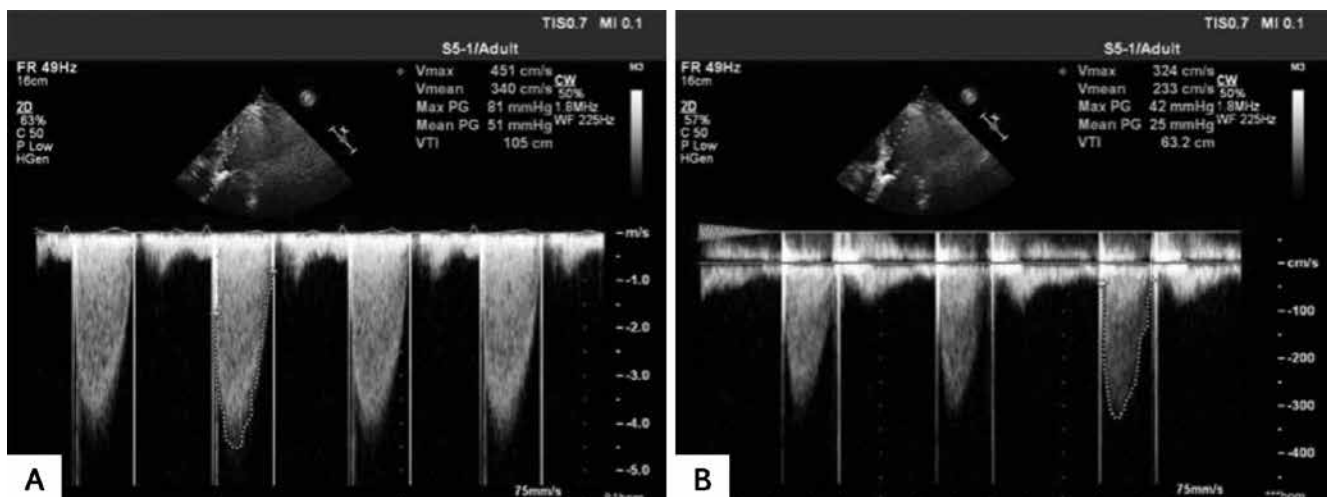


Figure 1. (A) Transthoracic echocardiography (TTE) continuous wave Doppler analysis showed increased maximal and mean aortic transvalvular gradients before thrombolytic therapy (TT) on admission. (B) TTE continuous wave Doppler analysis showed normal maximal and mean aortic transvalvular gradients after TT.

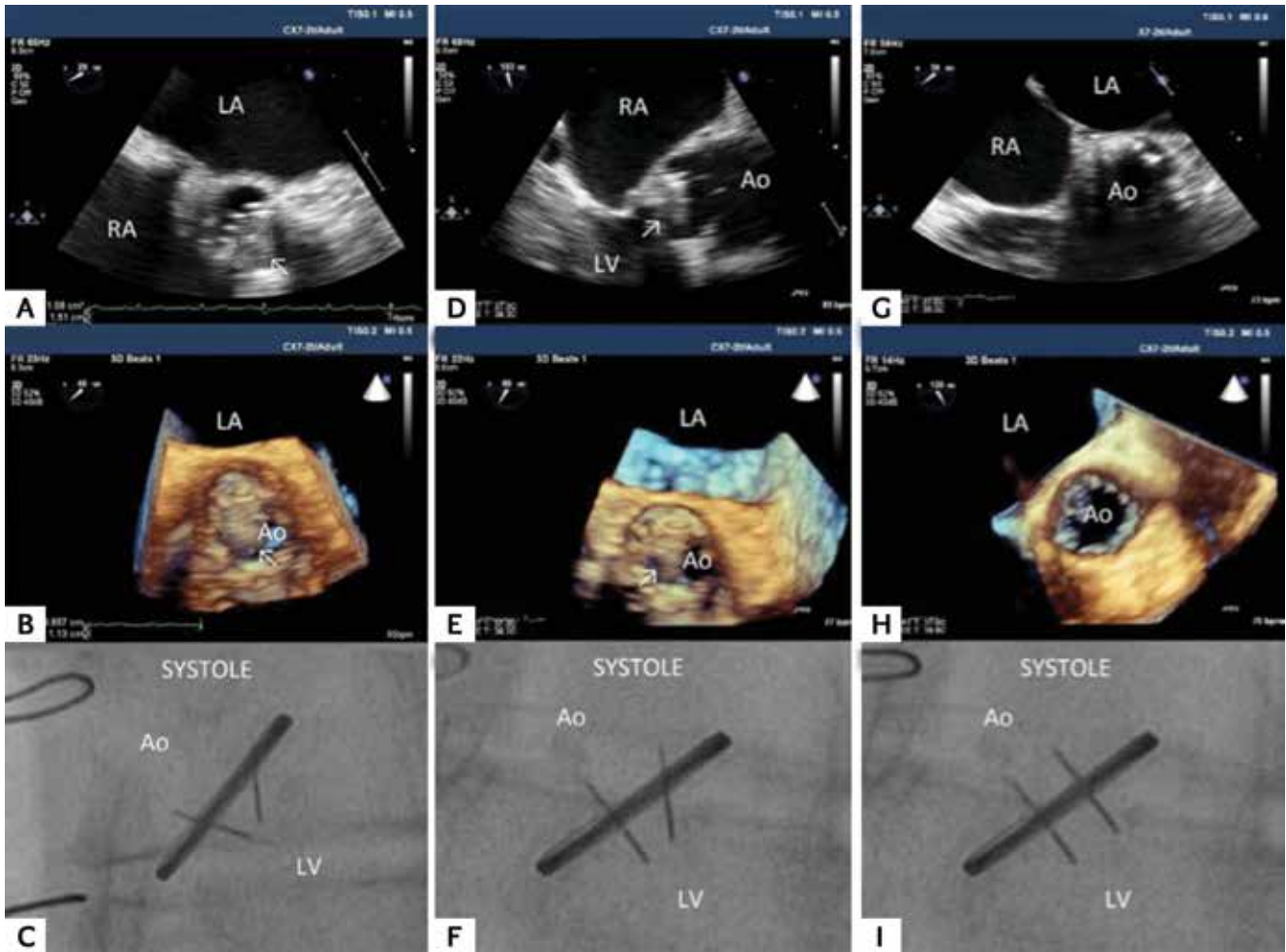


Figure 2. (A) Two-dimensional transesophageal echocardiography (2D TEE) and (B) real-time 3-dimensional transesophageal echocardiography (RT-3D TEE) showing an obstructive thrombus on the aortic mechanical prosthesis. (C) Left anterior oblique cranial fluoroscopy provided a tangential view showing one leaflet fixed in closed position and the other semiopen during systole. (D) 2D TEE and (E) RT-3D TEE could not reveal any progression of thrombolysis or resolution of leaflet restriction; however, (F) fluoroscopy revealed one leaflet normally opened and the other semiopen during systole after 25 mg tPA infusion. (G) 2D TEE and (H) RT-3D TEE showed normally functioning mechanical aortic valve with resolution of the thrombus burden and (I) restriction of leaflets was nearly completely resolved on fluoroscopy after totally 50 mg of tPA infusion. RA: Right Atrium, LV: Left Ventricle, LA: Left Atrium, Ao: Aorta, arrows show thrombus on the mechanical aortic prosthetic valve.

utilised as an easily repeatable modality to follow-up stable patients for evaluation of valve motions during TT⁽⁶⁾, as in the present case. TEE has been frequently used for monitoring TT. However, the use of TT for PVT demands the verification of therapeutic efficacy by a noninvasive method that can be performed on repeated occasions over time. Fluoroscopy, as a noninvasive tool, has an essential role in guiding TT.

Fluoroscopy has some other limitations. X-Ray exposure limits its use in pregnancy. Due to individual variability in the location of the prosthesis, optimal fluoroscopy angle in each individual should be recorded, as it could be time-saving in following studies. Although fluoroscopy is a very useful tool in the functional evaluation of prostheses with radiopaque discs, it provides no functional information in several prostheses with radiolucent discs manufactured in Brazil (Tri-technologies and HP-Biplus) or in valves that are only slightly radiopaque, made in Russia (Jyros)⁽⁸⁾.

CONCLUSION

Low-dose (25 mg) and ultra-slow (25 hours) infusion of tPA may be a valuable alternative treatment regimen for prosthetic heart valve thrombosis. Since mechanical prosthetic valves in the aortic position may not be viewed satisfactorily by TTE and TEE, serial fluoroscopy may be a reliable, easy, noninvasive and readily available technique to follow-up patients with obstructive aortic valve thrombosis during TT.

REFERENCES

1. Özkan M, Çakal B, Karakoyun S, Gürsoy OM, Çevik C, Kalçık M, et al. Thrombolytic therapy for the treatment of prosthetic heart valve thrombosis in pregnancy with low-dose, slow infusion of tissue-type plasminogen activator. *Circulation* 2013;128:532-40.
2. Özkan M, Gündüz S, Biteker M, Astarcioğlu MA, Çevik C, Kaynak E, et al. Comparison of different TEE-guided thrombolytic regimens for prosthetic valve thrombosis: the TROIA trial. *JACC Cardiovasc Imaging* 2013;6:206-16.

3. Montorsi P, De Bernardi F, Muratori M, Cavoretto D, Pepi M. Role of cine-fluoroscopy, transthoracic, and transesophageal echocardiography in patients with suspected prosthetic heart valve thrombosis. *Am J Cardiol* 2000;85:58-64.
4. Licata A, Matthai WH Jr. Evaluating the etiology of mechanical valve obstruction: use of clinical parameters, fluoroscopy, and echocardiography. *Catheter Cardiovasc Interv* 2002;55:495-500.
5. Muratori M, Montorsi P, Maffessanti F, Teruzzi G, Zoghbi WA, Gripari P, et al. Dysfunction of bileaflet aortic prosthesis: accuracy of echocardiography versus fluoroscopy. *JACC Cardiovasc Imaging* 2013;6:196-205.
6. Montorsi P, Cavoretto D, Alimento M, Muratori M, Pepi M. Prosthetic mitral valve thrombosis: can fluoroscopy predict the efficacy of thrombolytic treatment? *Circulation* 2003;108(Suppl 1):II79-84.
7. Montorsi P, Cavoretto D, Ballerini G. Thrombosis of mechanical heart valve prostheses: revisiting the role of fluoroscopy. *Br J Radiol* 2000;73:76-9.
8. Cianciulli TF, Lax JA, Saccheri MC, Guidoin R, Salvado CM, Fernández AJ, et al. Retrieval of a leaflet escaped in a Tri-technologies bileaflet mechanical prosthetic valve. *Eur J Echocardiogr* 2008;9:65-8.