



A Rare Complication of Stent Implantation: Aortocoronary Dissection

Okay Abacı, Cüneyt Kocaş, Gökhan Çetinkal, Betül Kocaş, Şükrü Arslan, Ahmet Yıldız

Istanbul University Faculty of Medicine, Institute of Cardiology, Istanbul, Turkey

ABSTRACT

We report a case of aortocoronary dissection during percutaneous transluminal coronary stent implantation, which resulted from a progressively retrograde extension of the coronary dissection into the sinus of Valsalva. It was successfully treated with stenting without an operation, resulting in optimal coronary blood flow and diminution of the aortic dissection.

Key Words: Coronary stenting; retrograde coronary dissection

Stent İmplantasyonunun Nadir Bir Komplikasyonu: Aortokoroner Diseksiyon

ÖZET

Koroner stent implantasyonu sırasında sinüs valsolvaya ilerleyen retrograde koroner diseksiyon olgusunu sunduk. Olgu stent implantasyonu ile operasyon ihtiyacı olmadan optimal koroner kan akımı ve aortik diseksiyonun tedavisi ile sonuçlandırıldı.

Anahtar Kelimeler: Koroner stentleme; retrograd koroner diseksiyon

INTRODUCTION

Coronary artery dissection is a well-recognised complication of percutaneous transluminal coronary angioplasty, which occurs 20%-40% angiographically, and most small intimal dissections have a benign course⁽¹⁾. Rarely, dissection involving the aortic root may also develop, and these large coronary artery dissections may cause acute coronary artery occlusion, resulting in myocardial infarction and even death^(2,3). Although it is relatively more common during balloon angioplasty of calcified plaques at high inflation pressures, in the literature, there are only two cases of pin hole rupture during stent implantation of heavily calcified lesions^(4,5). Here we present the case of a 51-year-old male who experienced stent balloon rupture at normal inflation pressure, causing retrograde coronary and aortic dissection, in addition to stent underexpansion at non-calcified thrombotic total occlusion of the proximal segment of the right coronary artery (RCA).

CASE REPORT

A 51-year-old man with a medical history of myocardial infarction and percutaneous transluminal coronary stenting presented with retrosternal chest pain for 36 h.

On admission to our emergency department, he was afebrile, with a blood pressure of 115/88 mmHg and respiratory rate of 13 bets/min. Oxygen saturation was 98% on inhaled room air. Her lung sounds were clear bilaterally, and cardiovascular examination findings were normal, without murmurs, rubs or gallops. Further, 12-lead electrocardiography (ECG) revealed sinus rhythm with Q waves in leads D2-D3-aVF. Acute coronary syndrome was initially suspected, and 600 mg clopidogrel and 300 mg acetylsalicylic acid were given as the initial treatment in our emergency department. Diagnostic catheterisation through the right radial artery was performed using a 6 French (6-Fr) arterial sheath. As a result, a thrombotic totally occluded lesion of the proximal segment of RCA just before the proximal stent was observed (Figure 1). We decided to perform primary percutaneous coronary intervention because of ongoing chest pain. The thrombotic totally occluded lesion of RCA was crossed using a floppy (0.014-inch) guidewire. TIMI-3 flow was restored after dilatation using a 2.0 × 12 mm balloon (Simpass, Simeks, Turkey). While a bare metal stent (3.5 × 33 mm Simchrome CoCr, Simeks, Turkey) was being deployed, balloon rupture occurred at 10 atm. Coronary angiography revealed distal

Correspondence

Okay Abacı

E-mail: drokayabaci@hotmail.com

Submitted: 29.10.2014

Accepted: 25.12.2014

@ Copyright 2017 by Koşuyolu Heart Journal.
Available on-line at
www.kosuyoluheartjournal.com

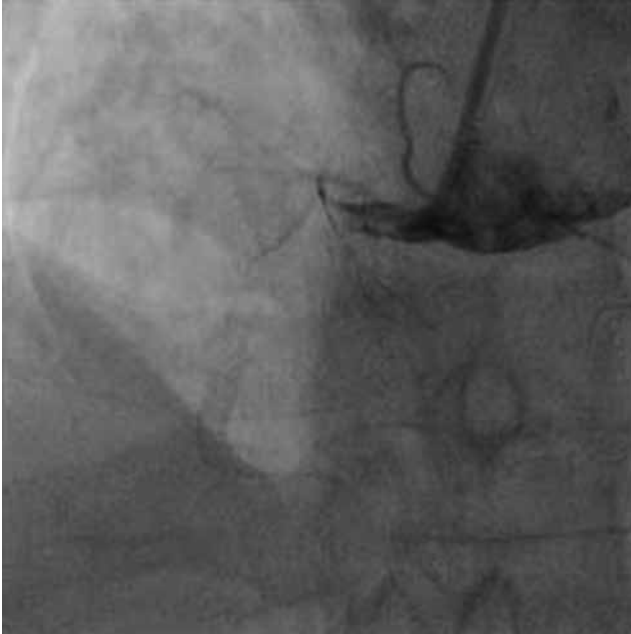

Figure 1. Total occlusion of proximal right coronary artery.

TIMI-1 flow and retrograde dissection involving both proximal RCA and the focal region of the aortic root near the RCA ostium. Immediately, BMS (4.0×15 Simchrome stent, Simeks, Turkey) was deployed with a minimal overlap. After successful implantation of the second stent and after dilatation, TIMI-3 flow was settled again (Figure 2). The coronary dissection line disappeared (Figure 3). Focal aortic dissection close to the RCA ostium was not advanced.

DISCUSSION

Aortocoronary dissection is a rare but potentially life-threatening complication of coronary angiography and percutaneous coronary intervention (PCI). The incidence of

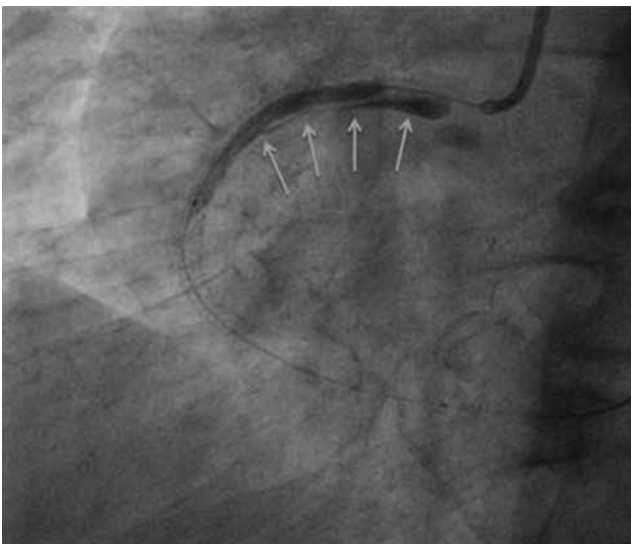


Figure 2. Arrows indicate retrograde dissection line during stent implantation.

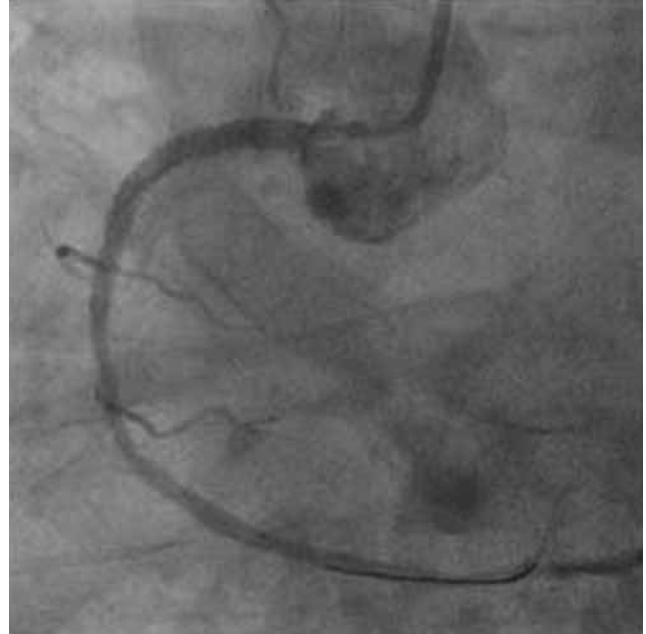

Figure 3. Disappearance of coronary dissection after stent implantation.

iatrogenic aortic dissection due to PCI is reported to be 0.02%, although the frequency of coronary dissection is not well known. Aortocoronary dissection is more common in PCI performed for acute myocardial infarction than in elective PCI⁽⁶⁾. Coronary dissection is associated with some risk factors related to the lesion type and technical procedure. Factors making the artery more prone to dissection are being calcified, egzantric, ostial, long or kinky as well as being morphologically complex in nature. Deep seating the catheter during engagement of the coronary ostium, exceeding the ratio of 1:2 between the balloon and artery or reaching high inflation pressures also facilitates the dissection probability technically⁽⁷⁾. Whenever there is a sudden onset of chest pain, rapid fall in blood pressure or stagnation of contrast material within the aortic root, especially following LAD or RCA ostial lesion interventions, retrograde aortic dissection must be kept in mind. Aortocoronary dissection has been reported to be more visible in RCA lesions in some series^(8,9).

To better classify the combination of coronary artery–ascending aorta dissections, they are divided into three classes by Dunning et al.: class 1 is defined as a focal dissection restricted to the ipsilateral coronary cusp; class 2 extends from the coronary cusp up to the ascending aorta < 40 mm and class 3 extends from the coronary cusp up to the ascending aorta > 40 mm (Table 1)⁽⁶⁾. It is a potentially lethal event despite its rarity. Immediate recognition and appropriate therapy are essential to prevent the retrograde propagation of the dissection line. Stenting of coronary dissection is a reasonable strategy in class 1 and 2 lesions to limit the dissection line, and the aorta can then be managed conservatively. The surgical approach should be considered for class 3 lesions⁽⁶⁾. In our case, the dissection line was extended up to the aorta retrogradely involving the aortic cusp. Thus, stenting of the RCA ostium was performed

Table 1. Proposed classification for coronary dissection with retrograde extension into the aortic root

Proposed classification	Patients with cor pulmonale (n= 4)
Class I	Involving the ipsilateral cusp
Class II	Involving the cusp and extending up the aorta < 40 mm
Class III	Involving the cusp and extending up the aorta > 40 mm

for limiting the progression of the retrograde aortic dissection line that already involved coronary cusps. Our case was different because an intervention was performed for a non-calcified RCA lesion but dissection occurred through a pin hole rupture during stent implantation without high inflation pressure (10 atm) and advanced up to the aortic cusps retrogradely. To the best of our knowledge, there have been no other similar case published in the literature.

In conclusion, although aortocoronary dissection generally occurs during balloon angioplasty of calcified plaques at high inflation pressures, this rare complication may be seen during coronary stent implantation in non-calcified lesions without high inflation pressure, as in our case.

REFERENCES

- Hermans WR, Foley DP, Rensing BJ, Rutsch W. Usefulness of quantitative and qualitative angiographic lesion morphology, and clinical characteristics in predicting major adverse cardiac events during and after native coronary balloon angioplasty. *Am J Cardiol* 1993;72:14-20.
- Carter AJ, Brinker JA. Dissection of the ascending aorta with coronary angiography. *Am J Cardiol* 1994;73:922-3.
- Freed M, Grines C, Safian RD. The new manual of interventional cardiology. 2nd Ed. Michigan: Physicians' Press, 1996:366-7.
- Tsunoda F, Shirota K, Inoue Y, Ishii H, Sugihara S, Mimura A. Pinhole balloon rupture and stuck stent: case report of a new and simple bailout technique for incomplete stent dilatation caused by rupture from a highly calcified lesion. *Cardiovasc Interv Ther* 2014;29:376-80.
- Dittel M, Prachar H, Mlczoch J. [Dissection of the left coronary main branch by balloon rupture during stent implantation. A case report]. *Z Kardiol* 1994;83:161-4.
- Dunning DW, Kahn JK, Hawkins ET, O'Neill WW. Iatrogenic coronary artery dissections extending into and involving the aortic root. *Catheter Cardiovasc Interv* 2000;51:387-93.
- Ellis SG, Roubin GS, King SB 3rd, Douglas JS Jr, Weintraub WS, Thomas RG, et al. Angiographic and clinical predictors of acute closure after native vessel coronary angioplasty. *Circulation* 1988;77:372-9.
- Shorrock D, Michael TT, Patel V, Kotsia A, Rangan BV, Abdullah SA, et al. Frequency and outcomes of aortocoronary dissection during percutaneous coronary intervention of chronic total occlusions: A case series and systematic review of the literature. *Catheter Cardiovasc Interv* 2014;84:670-5.
- Bae JH, Kim KB, Kim KS, Kim YN. A case of aortocoronary dissection as a complication during a percutaneous transluminal coronary angioplasty. *Int J Cardiol* 1998;66:237-40.