



# Surgical Treatment of Cor Triatriatum in a Geriatric Patient: a Rare Reason for Atrial Fibrillation and Stroke

Burçin Abud<sup>1</sup>, Süreyya Talay<sup>2</sup>

<sup>1</sup> İzmir Tepecik Training and Research Hospital, Clinic of Cardiovascular Surgery, İzmir, Turkey

<sup>2</sup> Çanakkale State Hospital, Clinic of Cardiovascular Surgery, Çanakkale, Turkey

## ABSTRACT

The incidence of cor triatriatum among neonates with congenital heart disease is only 0.1% to 0.4%. The diagnosis in adults is extremely rare. A 68-year-old patient was referred to our cardiothoracic surgery department following two-dimensional transthoracic echocardiography and a diagnosis of cor triatriatum. Echocardiography was performed due to stroke and atrial fibrillation. Echocardiography revealed a membrane in the left atrium, with the typical presentation of cor triatriatum type 1A. We operated the patient and excised the membrane. The operation was completed conventionally with sinus rhythm. Cor triatriatum in geriatric patients is a rare congenital cardiac abnormality and can be a reason for atrial fibrillation and stroke. The treatment of choice is surgery.

**Key Words:** Geriatric; atrial fibrillation; stroke; cor triatriatum

## Cor Triatriatumlu Geriatrik Bir Hastanın Cerrahi Tedavisi: Atriyal Fibrilasyon ve İnmenin Nadir Bir Sebebi

### ÖZET

Konjenital kalp hastalığı olan yenidoğanlarda cor triatriatum görülme sıklığı %0.1-0.4 olup, erişkinlerde ise görülme olasılığı çok nadirdir. Altmış sekiz yaşında bir hasta ekokardiyografi ile cor triatriatum tanısı konmuş olarak kliniğimize başvurdu. Ekokardiyografik değerlendirme mevcut atriyal fibrilasyon ve meydana gelmiş inme etyolojisini araştırmak için yapılmış olup, değerlendirme sonucunda sol atriyum içinde membran olduğu saptanmış. Değerlendirme sonucunda hastaya tip 1 A cor triatriatum tanısı konmuş. Hasta tarafımızdan opere edilerek mevcut membran çıkartıldı. Operasyon sonrası hastanın ritmi sinüs seyretti. Cor triatriatum geriatriklerde çok nadir görülmekte olup, atriyal fibrilasyon ve inmeye neden olabilmektedir. Bu tip hastalarda tedavi seçeneği cerrahidir.

**Anahtar Kelimeler:** Geriatrik; atriyal fibrilasyon; inme; cor triatriatum

## INTRODUCTION

The incidence of cor triatriatum among the neonates with congenital heart disease is only 0.1% to 0.4%. The diagnosis in adults is extremely rare. Several classifications have been described in the medical literature<sup>(1)</sup>. Our case was 68 years old and had cor triatriatum type 1A.

## CASE REPORT

A 68-year-old patient who had visited the department of neurology of our institution due to sudden-onset, left-sided haemiparesis and dysarthria was referred to our cardiothoracic surgery department following two-dimensional transthoracic echocardiography and a diagnosis of cor triatriatum. Transthoracic echocardiography was performed because of ischaemic stroke and atrial fibrillation (AF). He was a retired teacher and had a history of smoking for 44 years. There was no previous history of stroke or heart disease. His exercise capacity was NYHA Class 2. On physical examination, S1 was austere without any murmur, and neurologically, a left-sided haemiparesis and lisping were present. Electrocardiography (ECG) at administration revealed 110 pulses/min with AF. Chest radiography showed a normal cardiovascular silhouette, and the lungs were bilaterally natural. Computed tomography imaging of the brain revealed acute-subacute ischaemic infarction of the right cerebral hemisphere (Figure 1). Findings of carotid Doppler ultrasound were normal. Arterial blood gas analysis revealed the following: pH 7.429, PO<sub>2</sub> 82.7 mmHg, PCO<sub>2</sub> 47.1 mmHg and O<sub>2</sub> saturation 96.2%. Pulmonary tests showed the following: FVC 61% and FEV<sub>1</sub> 73%. Findings of preoperative blood tests were normal.

## Correspondence

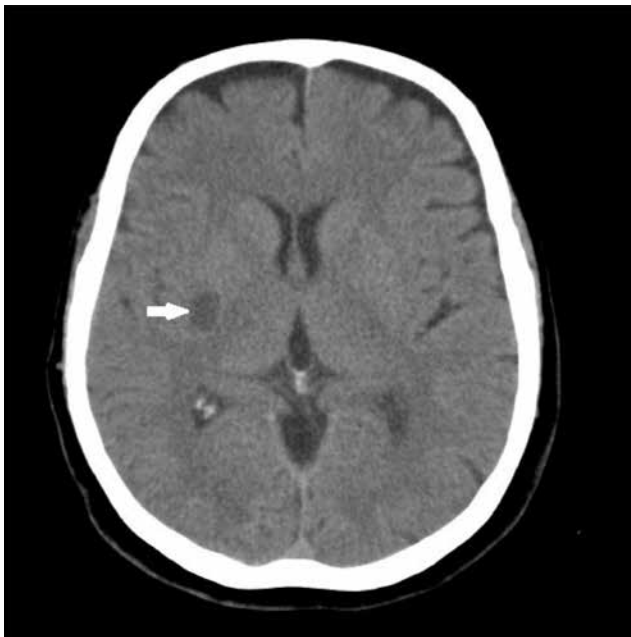Burçin Abud

E-mail: burcinabud@hotmail.com

Submitted: 19.12.2014

Accepted: 11.02.2015

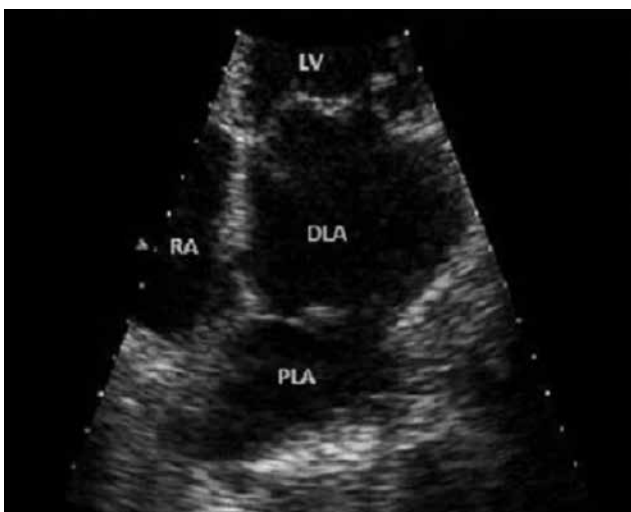@ Copyright 2017 by Kosuyolu Heart Journal.  
Available on-line at  
www.kosuyoluheartjournal.com



**Figure 1.** Non-contrast computed tomography imaging of the brain performed 2 days after the onset of left-sided haemiparesis and dysarthria showing a hypodense lesion (arrow) corresponding to acute-subacute ischaemic infarction of the right cerebral hemisphere in the area adjacent to the basal ganglia.

On two-dimensional transthoracic echocardiography, the left ventricular ejection fraction was 66%, diameter of the aortic root was 27 mm, diameter of the left atrium was 48 mm, left ventricular end-diastolic volume was 44 mm, left ventricular end-systolic volume was 28 mm and mitral peak gradient was 4 mmHg. Valvular morphologies were natural, with an abnormality of superposed to left atrium with a pathological colour Doppler flow “cor triatriatum” (Figure 2).

On cardiac catheterisation and pulmonary angiography, the pressure measurements were as follows: left ventricle 95/6 mmHg, aorta 96/60 mmHg, right ventricle 27/4 mmHg,



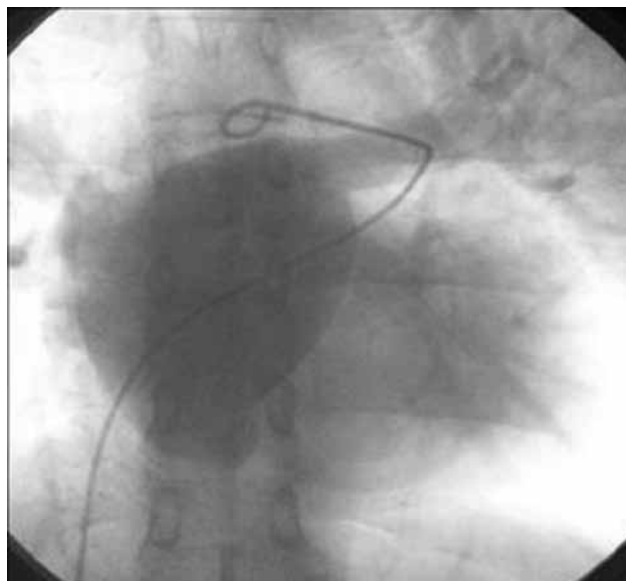
**Figure 2.** Preoperative echocardiography showing a membrane in the left atrium PLA: Proximal left atrium, DLA: Distal left atrium, RA: Right atrium, LV: Left ventricle.

pulmonary artery 27/13 mmHg, pulmonary capillary (wedge pressure) 15 mmHg and right artery pressure 4 mmHg. Late pulmonary angiography showed a membrane in the left atrium, with a typical presentation of cor triatriatum (Figure 3). A pressure gradient of 9-10 mmHg was measured, which was caused by the membrane between the left atrium and left ventricle. The coronary arteries were normal.

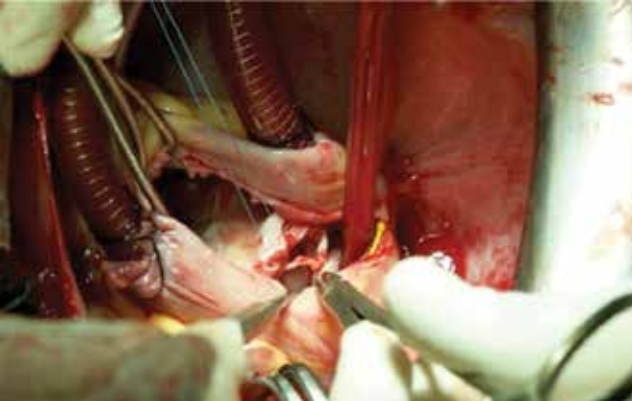
**Surgical technique:** Under general anaesthesia, median sternotomy and pericardiectomy was performed, and the cardiovascular anatomy was observed. Following the aorto-bicaval cannulation and aortic cross-clamping, cardiac arrest was observed with moderate hypothermic cardioplegia. We reached the interatrial septum with right atriotomy and incised the septum. Then, we observed and excised the fenestrated membrane that divided the left atrium into two chambers (Figure 4). We controlled the pulmonary vein orifices interiorly and primarily repaired the septal incision and atriotomy with propylene 4/0 sutures. The operation was completed conventionally with sinus rhythm. Postoperative two-dimensional transthoracic echocardiography proved the success of the operation. Without any complications, the patient was discharged on the fifth day postoperatively.

## DISCUSSION

Cor triatriatum is a congenital cardiac abnormality with a fibromuscular membrane that divides the left atrium into two chambers<sup>(2)</sup>. The incidence of cor triatriatum among neonates with congenital heart disease is only 0.1% to 0.4%, and the diagnosis in adults is much less<sup>(1)</sup>. The embryological basis of this anomaly remains controversial. The three main theories are malseptation involving the septum primum, malincorporation of the common pulmonary vein and entrapment of the common pulmonary vein<sup>(3)</sup>.



**Figure 3.** Pulmonary angiogram.



**Figure 4.** Intraoperative excision of cor triatriatum.

Cor triatriatum most commonly presents during infancy or early childhood with respiratory symptoms caused by functional pulmonary vein obstruction, but in some cases, it does not appear until later stages<sup>(2)</sup>. The most common symptoms observed in adults are similar to those of mitral stenosis: dyspnoea, orthopnoea and haemoptysis. Diagnosis of the abnormality has also been reported in asymptomatic patients as an incidental finding<sup>(3)</sup>. Asymptomatic adults can become symptomatic with time, and the development of mitral regurgitation or AF can be the reason<sup>(2,3)</sup>. The diagnosis of this abnormality has also been reported in adults presenting with stroke<sup>(4)</sup>. This was also the case in our patient.

Cor triatriatum is isolated or present in association with other cardiac abnormalities. In adults, the most frequently associated abnormalities are mitral regurgitation, secundum atrial septal

defect and the presence of left superior vena cava<sup>(3,5)</sup>. Cor triatriatum was isolated in our patient, who none of the associated cardiac abnormalities.

The choice of treatment for patients with cor triatriatum and associated symptoms is surgery. Surgery to correct isolated cor triatriatum is very safe, and the long-term results are excellent<sup>(5)</sup>. In our patient, the operation was completed with sinus rhythm. The follow-up was normal, and his neurological manifestation gradually improved, without any recurrence of AF and stroke.

## CONCLUSION

Cor triatriatum in geriatric patients is a rare congenital cardiac abnormality and can be a reason for AF and stroke. The treatment of choice is surgery.

## REFERENCES

1. Alphonso N, Norgaard MA, Newcomb A, d'Udekem Y, Brizard CP, Cochrane A. Cor triatriatum: presentation, diagnosis and long-term surgical results. *Ann Thorac Surg* 2005;80:1666-71.
2. Sen T, Guray Y, Demirkan BM, Alioglu H, Korkmaz S. Cor triatriatum sinister in a 67-year-old man with atrial fibrillation. *Tex Heart Inst J* 2010;37:246-7.
3. Chen Q, Guhathakurta S, Vadalapili G, Nalladaru Z, Easthope RN, Sharma AK. Cor triatriatum in adults: three new cases and a brief review. *Tex Heart Inst J* 1999;26:106-10.
4. Park KJ, Park IK, Sir JJ, Kim HT, Park YI, Tsung PC, et al. Adult cor triatriatum presenting as cardioembolic stroke. *Intern Med* 2009;48:1149-52.
5. van Son JA, Danielson GK, Schaff HV, Puga FJ, Seward JB, Hagler DJ, et al. Cor triatriatum: diagnosis, operative approach, and late results. *Mayo Clin Proc* 1993;68:854-9.