

## Pericardial Cyst: An Anesthetist Perspective



### Perikardiyal Kist: Anestezi Bakışı

Hülya Yılmaz Ak

Istanbul University Cardiology Institute, Department of Anesthesiology and Reanimation, İstanbul, Turkey

A 32-year-old male was investigated owing to chest pain and palpitation since 2 years. A pericardial cyst was suspected at the right side of the heart based on transthoracic echocardiography and chest radiography. A thorax computed tomography confirmed a mass (approximately 36-mm length) adjacent to the right side of the heart (Figure 1). In this case, we used conservative therapies because the possible complication risk was low. Pericardial cysts are very rare, benign, and developmental anomalies. They are commonly congenital, but other causes including inflammatory, traumatic, and postcardiac surgery have been described<sup>(1)</sup>. Usually they do not produce any symptoms, and the diagnosis is an incidental finding in chest radiographs or other imaging modalities such as echocardiography. The most common presenting symptoms are chest pain, chronic cough, dyspnea, and palpitation. Computed tomography and magnetic resonance imaging are considered as best modality techniques for diagnosis. Conservative approach and follow up may be considered if the cyst is small and possible complication risk is low. Video assisted thoracotomy or surgical removal of the cysts should be considered in cases like symptomatic patients, large cysts, and presence of high complications risk due to compression of surrounding structure such as heart and lung, inflammation, hemorrhage or rupture. In an anesthetist perspective, although most pericardial cysts are successfully removed, induction and maintenance of anesthesia period can be potentially hazardous in case of cardiac compression of surrounding structure and presence of extensive cardiac manipulation or prolonged surgery.

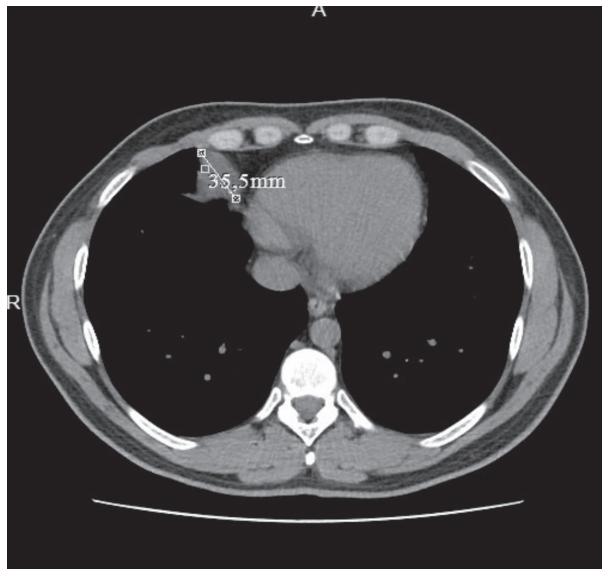


Figure 1. A mass adjacent to the right side of the heart.

#### REFERENCE

1. Verhaert D, Gabriel RS, Johnston D, Lytle BW, Desai MY, Klein AL. The role of multimodality imaging in the management of pericardial disease. *Circ Cardiovasc Imaging* 2010;3:333-43.

#### Correspondence

Hülya Yılmaz Ak

E-mail: hlyyilmazz@hotmail.com

Submitted: 01.07.2017

Accepted: 03.07.2017

© Copyright 2017 by Koşuyolu Heart Journal. Available on-line at [www.kosuyoluheartjournal.com](http://www.kosuyoluheartjournal.com)