

Iloprost is a Useful Therapy for Adams-Oliver Syndrome with Eisenmenger Syndrome



Erkan Baysal¹, Bernas Altıntaş¹, Barış Yaylak¹, Rojhat Altındağ¹, Önder Bilge¹, Utkan Sevük²

¹ Diyarbakır Area Training and Research Hospital, Clinic of Cardiology, Diyarbakır, Turkey

² Diyarbakır Area Training and Research Hospital, Clinic of Cardiovascular Surgery, Diyarbakır, Turkey

ABSTRACT

Adams-Oliver syndrome is characterized by scalp defects with terminal transverse limb anomalies. Most reports on this syndrome demonstrate autosomal dominant pedigrees. Cutis marmorata telangiectasia congenita accompanies the syndrome in many cases. Here, we describe a case of Adams-Oliver syndrome with cardiac malformation and Eisenmenger syndrome. Because this is a rare case, the detailed case and literature data are presented.

Key Words: Adams-Oliver syndrome; iloprost therapy; Eisenmenger syndrome

Eisenmenger Sendromunun Eşlik Ettiği Adams-Oliver Sendromlu Hastalar İçin İloprost Tedavisi

ÖZET

Adams-Oliver sendromu (AOS) skalp defekti ve uç uzuv anomalisi ile karakterizedir. Birçok rapor bu sendromun otozomal dominant kalıtımını kanıtlamıştır. Birçok olguda kutis marmorata telangiectasia konjenita eşlik etmektedir. Bu olguda biz AOS'a eşlik eden Eisenmenger sendromu ve kardiyak malformasyon tanımladık. Literatürümüzde bulunan çok nadir bir olgu olduğu için detaylı olgu ve literatür bilgisi hazırlandı.

Anahtar Kelimeler: Adams-Oliver sendromu; iloprost tedavisi; Eisenmenger sendromu

INTRODUCTION

Adams-Oliver syndrome (AOS) was first characterized in 1945 by Adams and Oliver who described eight members from three generations of a family who had defects of limbs, the scalp, and the skull⁽¹⁾.

AOS is a rare congenital disorder including congenital scalp and skull defects, extremity anomalies, occasional mental retardation, and congenital heart disease⁽²⁻⁵⁾. The association of cutis marmorata telangiectatica congenita with this syndrome has been described^(3,4,6). The expression of scalp defects sometimes includes bone deformities, and limb defects can vary from nail dystrophy to complete absence of distal extremities. Some cases of AOS occur randomly due to a spontaneous genetic change (i.e., new mutation), but AOS is mostly inherited as an autosomal dominant trait; however, a suggestive autosomal recessive mode of inheritance has also been described^(7,8).

CASE REPORT

A 24-year-old girl was admitted to the cardiology care unit for dyspnea etiology six years after the establishment of an atrial-septal defect. In the physical examination, facial dismorphism was seen. In addition, other bone structural defects emerged after X-Ray examination. Electrocardiography revealed RBBB with an average heart rate of 75 beats/min. ECG revealed right axis deviation and right ventricular hypertrophy. The two-dimensional echocardiography showed ASD (secundum) with severe pulmonary hypertension and a bi-directional shunt. In addition, a grade III tricuspid valve insufficiency was observed (Figure 1). Biochemical analysis were normal.

Correspondence

Erkan Baysal

E-mail: dr.erkans.baysal@hotmail.com

Submitted: 22.10.2015

Accepted: 12.11.2015

© Copyright 2017 by Koşuyolu Heart Journal.
Available on-line at
www.kosuyoluheartjournal.com

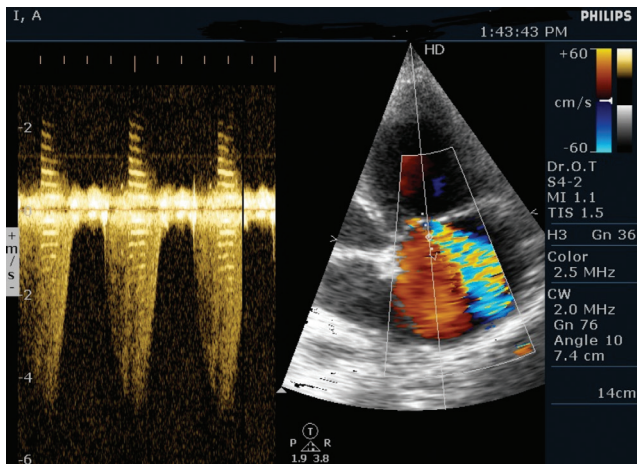


Figure 1. Echocardiography showed severe tricuspid valve insufficiency.

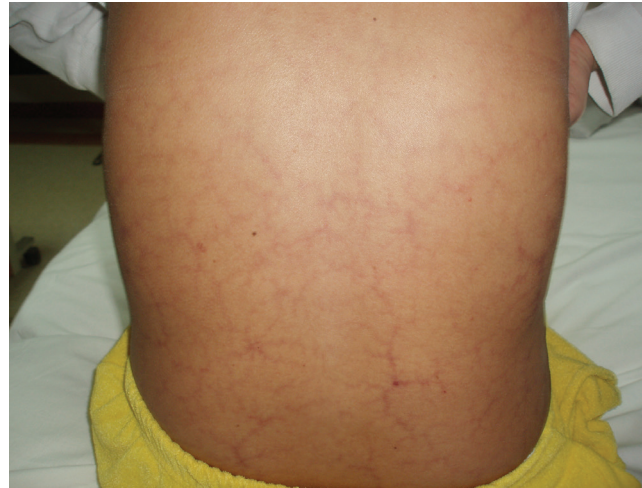

Figure 4. Abnormally dilated blood vessels.

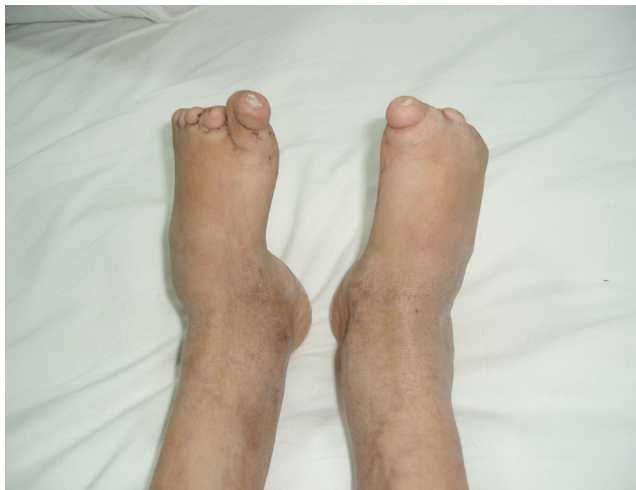

Figure 2. Asymmetric transverse limb reduction defect.

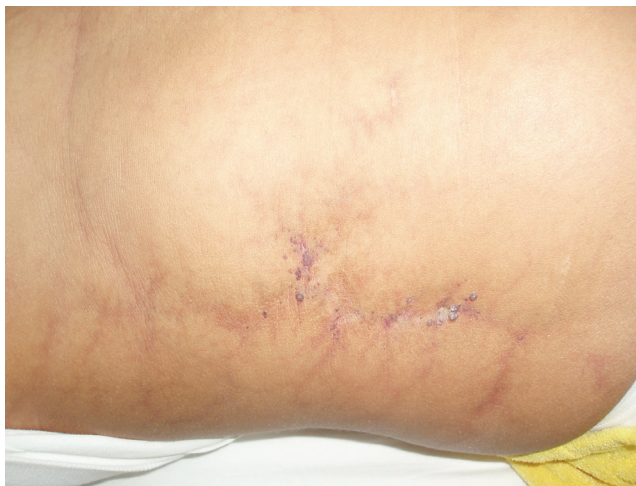

Figure 3. Abdominal skin defect.

Clinically, the patient had cyanosis, clubbing, cardiomegaly, left parasternal heave, and epigastric pulsations. The first heart sound was normal, whereas the second heart sound was wide and fixed split with accentuation of the pulmonary component. Tricuspid murmurs and pulmonary regurgitation were also present. The chest examination was clear.

Asymmetric transverse limb reduction defect of the right foot and absence of the second, third, fourth, and fifth phalanx were observed. Hypoplasia of the distal phalanx of the left foot toes and partial to complete dystrophy of all nails of both feet were also observed (Figure 2).

The patient had an abdominal skin defect with abnormally dilated blood vessels visible directly under the affected skin, which is defined as cutis marmorata telangiectetica congenita (Figure 3,4). There was no family history of scalp or limb defects.

We followed the patient for five years and treated her with iloprost, warfarin, diuretic, and digoxin. Despite receiving iloprost for three years, she showed no decrease in pulmonary arterial pressure. Although there was no decrease in pulmonary arterial pressure, NYHA functional capacity decreased from NYHA 3 to NYHA 2.

DISCUSSION

AOS is a congenital condition comprising congenital scalp defects and distal limb abnormalities. A variety of associated symptoms have been reported, including cutis marmorata telangiectatica, central nervous system abnormalities, and cardiac malformations. Variable expressions of this syndrome have been reported in the literature⁽¹⁻⁵⁾.

Limb defects are typically asymmetric and can be more severe in one arm or leg. The full spectrum of observed defects ranges from hypoplastic nails, cutaneous syndactyly, transverse reduction defects, polydactyly, and brachydactyly⁽⁹⁾. More severe defects include absence of the complete hand or foot or

virtual limb^(2,3). Our patient showed right and left lower limb involvement.

Our patient had congenital heart malformation, namely, atrial septal defect and Eisenmenger syndrome. Zapata et al. analyzed the literature and found that 15 of 112 cases of AOS (13.4%) had congenital cardiac malformations⁽¹⁰⁾.

The range of observed defects included the following: ventricular septal defect, atrial septal defect, tetralogy of Fallot, coarctation of the aorta, bicuspid aortic valve, pulmonary venous stenosis, and pulmonary hypertension.

The pathophysiological mechanism underlying AOS has been a focus of discussion in recent publications. Although a clear pathogenesis has not yet been established, vascular impairments have mainly been assumed. Schwartz et al. hypothesized that a congenital vascular abnormality is the underlying pathogenesis⁽¹¹⁾. They suggest that AOS should not be considered a syndrome but rather a constellation of clinical findings resulting from an early embryonic vascular abnormality. With the genetic cause of AOS remaining unknown, Verdyck et al. selected several candidate genes implicated in craniofacial and limb development in order to identify the AOS gene⁽¹²⁾.

CONCLUSION

AOS may include cardiac anomalies, and pulmonary hypertension may rapidly develop in patients with AOS. Iloprost administration can be initiated in these patients for decreased NYHA functional capacity and mortality.

REFERENCES

1. Adams FH, Oliver CP. Hereditary deformities in man due to arrested development. *J Hered* 1945;36:3-7.
2. Whitley CB, Gorlin RJ. Adams-Oliver syndrome revisited. *Am J Med Genet* 1991;40:319-26.
3. Toriello HV, Graff RG, Florentine MF, Lacina S, Moore WD. Scalp and limb defects with cutis marmorata telangiectatica congenita: Adams-Oliver syndrome? *Am J Med Genet* 1988;9:269-76.
4. Frank RA, Frosch PS. Adams-Oliver syndrome. *Dermatology* 1993;187:205-8.
5. Orstavik KH, Stromme P, Spetalen S, Flage T, Westvik P, Vesterhus P, et al. Aplasia cutis congenita associated with limb, eye, and brain anomalies. *Am J Med Genet* 1995;59:92-5.
6. Dyll-Smith D, Ramsden A, Laurie S. Adams-Oliver syndrome: aplasia cutis congenita, terminal transverse limb defects and cutis marmorata telangiectatica congenita. *Australas J Dermatol* 1994;35:19-22.
7. Koiffmann CP, Wajntal A, Huyke BJ, Castro RM. Congenital scalp skull defects with distal limb anomalies (Adams-Oliver syndrome McKusick 10030): further suggestion of autosomal recessive inheritance. *Am J Med Genet* 1988;29:263-8.
8. Kuster W, Lenz W, Kaariainen H, Majewski F. Congenital scalp defects with distal limb anomalies (Adams-Oliver syndrome): report of ten cases and review of the literature. *Am J Med Genet* 1988; 31:99-115.
9. Sybert VP. Congenital scalp defects with distal limb anomalies: further suggestion of autosomal recessive inheritance. *Am J Med Genet* 1989;32: 266-7.
10. Zapata HH, Sletten LJ, Pierpont ME. Congenital cardiac malformations in Adams-Oliver syndrome. *Clin Genet* 1995;47:80-4.
11. Swartz EN, Sanatani S, Sandor GG, Schreiber RA. Vascular abnormalities in Adams-Oliver syndrome. *Am J Med Genet* 1999;82:49-52.
12. Verdyck P, Blaumeiser B, Holder-Espinasse M, Van Hul W, Wuyts W. Adams-Oliver syndrome: clinical description of a four-generation family and exclusion of five candidate genes. *Clin Genet* 2006;69:86-92.