



Sandwich Stenting Technique Successfully Performed for Acute Carotid Artery Stent Thrombosis: A Case Report

Abdullah İçli, Ahmet Lütfü Sertdemir, Kurtuluş Özdemir

University of Necmettin Erbakan, Faculty of Medicine, Department of Cardiology, Konya, Turkey

ABSTRACT

Even though acute carotid stent thrombosis is a rare complication of carotid artery stenting (CAS), it can cause fatal thromboembolic events. There are limited numbers of techniques that can be applied during such emergencies. In this study, we report a case in which the sandwich technique was successfully performed in the acute in-stent thrombosis. Conclusively, in-procedural in-stent thrombosis following CAS must be rapidly evaluated and treated, allowing the efficient prevention of catastrophic events. Thus, sandwich stent technique is a rapid and efficient method for treating acute in-stent thrombosis.

Key Words: Carotid stenting; in-stent thrombosis; complications; sandwich technique

Akut Karotis Stent Trombozunda Başarılı Sandviç Tekniği Olgusu

ÖZET

Akut karotis arter stent (KAS) trombozu nadir bir komplikasyon olmasına rağmen fatal tromboembolik olaylara neden olabilir. Akut olaylarda uygulanabilecek sınırlı sayıda teknik olmakla birlikte bu olgu bildirimizde akut KAS trombozunda başarılı bir şekilde uygulanan “sandviç stent tekniğini” sunmaktayız. Prosedürel akut KAS trombozu hızlı ve etkin bir şekilde değerlendirilerek tedavi edilmesi gereken bir durumdur. Bu olgumuzda kullandığımız teknik böyle katastrofik durumlara başatmede hızlı ve güvenli alternatif bir yöntem olarak kullanılabilir.

Anahtar Kelimeler: Karotis stentleme; instent tromboz; komplikasyon; sandviç tekniği

INTRODUCTION

Even though acute carotid artery stent thrombosis is a rare complication of carotid artery stenting (CAS), it can lead to fatal thromboembolic events⁽¹⁾. In such cases, rapid intervention should be performed to limit cell death following cerebral ischemia. Herein, we present a case of percutaneous mechanical thrombectomy that was successfully performed using the sandwich technique for treating acute carotid stent thrombosis.

CASE REPORT

A 65-year-old diabetic male patient was admitted to our hospital with a complaint of recent transient ischemic attack (TIA) involving the left internal carotid artery (LICA). He was diagnosed with the bilateral internal carotid stenosis (90% on the left and 75% on the right) (Figure 1A). The patient was under Acetylsalicylic acid (100 mg) + Clopidogrel (75 mg) treatment that was initiated 30 days ago and he was examined in the laboratory. The patient was evaluated in the laboratory on day 32 of the TIA for CAS. Extracranial lesions were observed and intracranial carotid angiography was performed. The patient was administered unfractionated heparin and his ACT was measured between 250 and 350. We implanted an 8/6/30-mm self-expanding closed-cell nitinol stent [TheProtégé/SpiderFx (ev3 Endovascular Inc., Plymouth, Minnesota)] under Angio Guard (Cordis Corp., Miami, FL) protection. Furthermore, post-dilation was performed with the stent together with Omnipass 5/20-mm balloon (Cordis Corporation, Warren, NJ). In the control angiogram, instant massive thrombus image was observed (Figure 1B-E; instent massive thrombus can be seen in the control angiogram). The patient was decompensated and became rapidly unconscious and hemodynamically

Correspondence

Abdullah İçli

E-mail: abdullahicli@yahoo.com

Submitted: 09.06.2016

Accepted: 18.08.2016

© Copyright 2018 by Koşuyolu Heart Journal.
Available on-line at
www.kosuyoluheartjournal.com

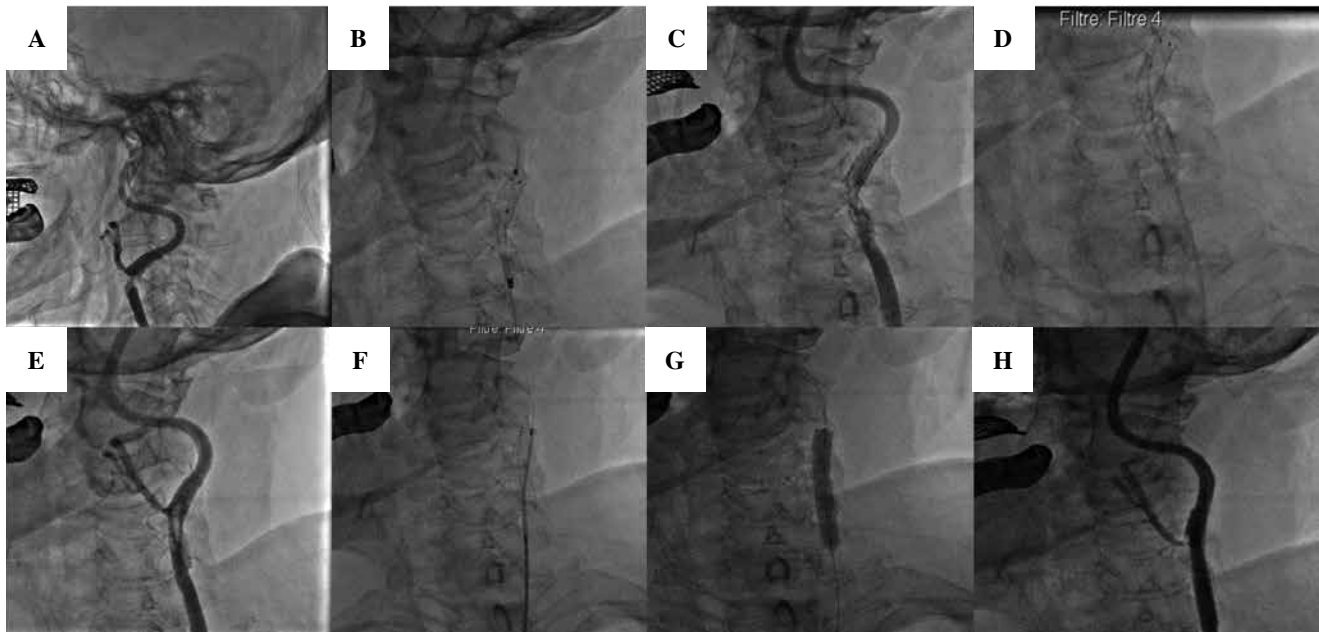


Figure 1. Angiographic images of procedures which were performed to solve the left carotid artery stenosis can be seen. (A) The left carotid internal artery stenosis can be observed prior to intervention. (B) The first closed-cell self-expandable stenting. (C) In-stent acute massive thrombus after stent implantation. (D) Aspiration catheter application to in-stent intensive thrombosis. (E) Persistent intense thrombus was observed upon thrombus aspiration. (F) Placing a second closed-cell self-expandable stent in-stent “sandwich technique.” (G) Post-dilation. (H) Patency and flow were observed upon a successfully performed sandwich technique.

unstable. He was immediately intubated and hemodynamic support was initiated. The ACT was measured again and was noted to be 265. Next, additional 5000 U unfractionated heparin was intravenously administered to the patient. Shortly after, postdilatation was performed using a 4×20 mm balloon (Guidant Corp., Indianapolis, IN). However, in-stent thrombus was persistent. Thus, we primarily performed a percutaneous aspiration of thrombus (Export; Medtronic, Minneapolis, MN, USA) but it was observed that the thrombus was not dissolved. The desired flow and patency were not ensured. Upon this, additional in-stent implantation was performed using the sandwich technique to limit the thrombus between two stents (F;G). Post-procedural control angiogram showed that there was a recanalization of the LICA. In addition, complete clot dissolution, desired flow, and patency were observed in the end of the procedure (H). Meanwhile, the distal vessel patency was shown by performing intracranial angiography. Furthermore, intense yellow debris and fresh thrombus were observed in the filter basket in the distal protection device. The patient was consulted in Neurology clinics after the intervention. There was no neurological deficit upon intervention even though small bright lesions were observed in the left cerebellar hemisphere on diffusion-weighted MRI. We discharged the patient seven days later. The dual antiplatelet treatment of the patients was planned for 6 months. A patency was observed in the stent on carotid CT angiography, which was performed after 6 months (Figure 2).

DISCUSSION

In this study, we reported the 6-month follow-up recordings of the 65-year-old male patient who had an acute carotid stent thrombosis. The following conditions can increase the risk of thrombogenicity while performing CAS procedures: antiplatelet monotherapy, antiplatelet resistance, early discontinuation of treatment, thrombocytopenia, diabetes mellitus, heparin resistance, vessel dissection, severe plaque protrusion, stent under expansion, and stent fracture^(2,3). The aspirin/clopidogrel resistance was not included for study in this case report because the rapid clinical and hemodynamic recovery was considered to be achieved by placing the thrombus/plaque/tissue prolapse or protrusion between two stents using the sandwich technique. Furthermore, no new clinical event was noted in the follow-ups of the patient during the 6 months of dual antiplatelet treatment. Meanwhile, stent patency was observed via CT imaging after 6 months. Furthermore, there is also the presence of procedural risks, such as the guiding catheter which cannot be frequently rinsed with flushing due to heparin production. Furthermore, expiry date issues and thus thrombus can also be formed⁽⁴⁾. According to the literature, emergent treatment procedures of the acute carotid thrombosis after CAS can be as follows: removing the thrombus by open surgery and performing thromboendarterectomy, thrombolysis or facilitated thrombolysis can be ensured with the rescue use of glycoprotein IIb/IIIa receptor inhibitors (GPIs), postdilatation can be performed using distal in-stent protection

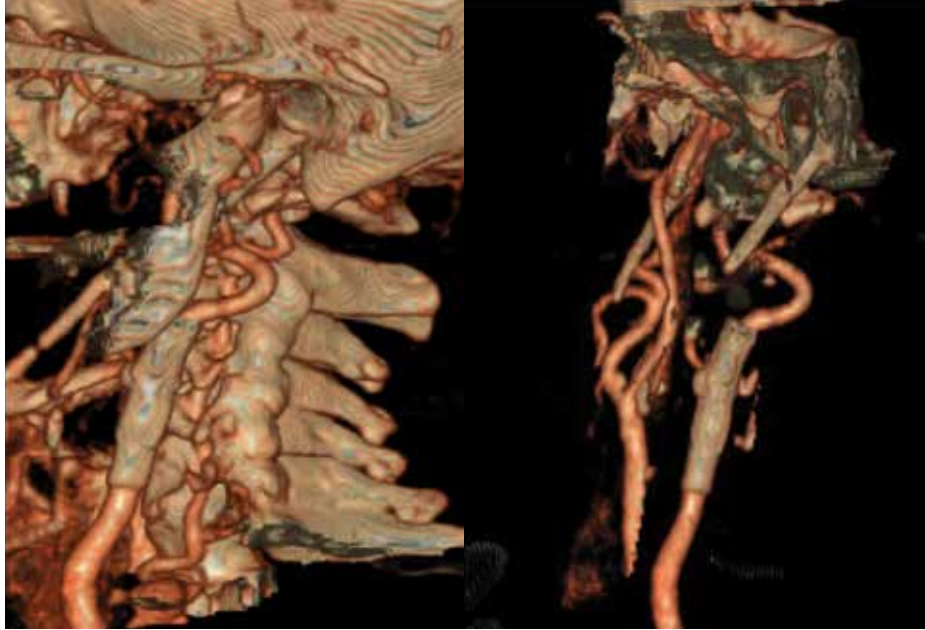

Figure 2. After 6 months, stent patency was still present according to the control CT angiogram.

filter during the percutaneous transluminal angioplasty or additional stent can be implanted together with the intravenous administration of recombinant tissue plasminogen activator^(2,5-7). The tPA was not preferred because of the low body weight (54 kg) and HASBLED score was 4. In this case, stent-filling defect is referred to as “image” and we believe that the thrombus occurs together with plaque/tissue prolapsed or protrusion because the clinical outcome of the patient was prominently improved and there was no thrombus in the intracranial angiogram. It has already been reported that the stent used in the intervention can lead to such complications. Upon implantation, the stent can increase the protrusion risk due to the “free cell area”⁽⁸⁾. This risk is lower when closed-cell stents are used compared with the use of open cell stents. Upon this catastrophic event, we primarily performed thrombus aspiration using a catheter and thrombus retrieval was partially achieved. However, we could not achieve thrombus dissolution. Therefore, we aimed to limit the thrombus between the two stents using a secondary closed-cell stent instead of an emergency surgery or thrombolytic therapy. The sandwich technique can be successfully used in the deployment of consecutive closed-cell self-expandable stents. The sandwich technique is reportedly being used in peripheral artery interventions and in coping with carotid artery stent thrombosis^(7,9). The procedure was successfully performed as an alternative treatment without causing complications.

In conclusion, in-procedural in-stent thrombosis following CAS must be rapidly evaluated and treated for the efficient prevention of catastrophic events. Percutaneous mechanical

thrombectomy which can be performed using the sandwich technique is a useful tool in the treatment of acute in-stent thrombosis after CAS.

REFERENCES

1. Markatis F, Petrosyan A, Abdulamit T, Bergeron P. Acute carotid stent thrombosis: a case of surgical revascularization and review of treatment options. *Vascular* 2012;20:217-20.
2. Setacci C, de Donato G, Setacci F, Chisci E, Cappelli A, Pieraccini M, et al. Surgical management of acute carotid thrombosis after carotid stenting: a report of three cases. *A J Vasc Surg* 2005;42:993-6.
3. Okazaki T, Satomi J, Satoh K, Hirasawa M, Nagahiro S. Rescuerevascularization therapy with a stent-in-stent technique for acute intracranial internal carotid artery occlusion. *Neurol Med Chir* 2005;45:253-8.
4. Iancu A, Grosz C, Lazar A. Acute carotid stent thrombosis: review of the literature and long-term follow-up. *Cardiovasc Revasc Med* 2010;11:110-3.
5. Steiner-Boker S, Cejna M, Nasel C, Minar E, Kopp CW. Successful revascularization of acute carotid stent thrombosis by facilitated thrombolysis. *AJNR Am J Neuroradiol* 2004;25:1411-3.
6. Masuo O, Terada T, Matsuda Y, Ogura M, Tsumoto T, Yamaga H, et al. T. Successful recanalization by in-stent percutaneous transluminal angioplasty with distal protection for acute carotid stent thrombosis. *Neurol Med Chir* 2006;46:495-9.
7. Kurisu K, Manabe H, Ihara T. Case of symptomatic subacute in-stent thrombosis after carotid angioplasty and stenting for severe carotid stenosis. *No Shinkei Geka* 2007;35:1001-5.
8. Desai SS, Codreanu M, Charlton-Ouw KM, Safi H, Azizzadeh A. Impact of stent design on the outcome of intervention for carotid bifurcation stenosis. *J Cardiovasc Surg* 2010;51:799-806.
9. Hart JP, Bosiers M, Deloose K, Uflacker R, Schönholz CJ. Endovascular repair of a ruptured subclavian artery aneurysm in a patient with Ehlers-Danlos syndrome using a sandwich technique. *Vascular* 2014;22:371-4.