



Unusually Located Pseudoaneurysms: Superficial Palmar Arc and Superficial Temporal Artery

Ahmet Ünlü¹, Ahmet Barış Durukan¹

¹ Medical Park Uşak Hospital, Clinic of Cardiovascular Surgery, Uşak, Turkey

ABSTRACT

Peripheral pseudoaneurysms mostly occur owing to diagnostic catheterization but rarely owing to blunt or penetrating trauma, infection, or recurrent microtrauma. They appear as a soft pulsatile mass. Complications may occur owing to rupture or distal embolization. Doppler ultrasound and computed tomography are the imaging techniques used in diagnosis. Endovascular interventions and surgery are among the treatment options. In this report, we present two unusually located pseudoaneurysms, one in the superficial palmar arch following penetrating trauma and another in the superficial temporal artery following blunt trauma.

Key Words: Pseudoaneurysm; temporal artery; superficial palmar arch

Olağan Dışı Yerleşimli Yalancı Anevrizmalar: Yüzeysel Palmar Ark ve Yüzeysel Temporal Arter

ÖZET

Periferik psödoanevrizmalar sıklıkla diyagnostik kateterizasyona bağlı oluşsalar da, nadiren künt ya da penetran travma, enfeksiyon ya da tekrarlayan mikrotravmaya bağlı da oluşabilirler. Yumuşak, pulsatil kitle olarak gözükürler. Rüptür ya da distal embolizasyona bağlı komplikasyonlar oluşabilir. Doppler ultrasonografi ve bilgisayarlı tomografi tamda kullanılan görüntüleme yöntemleridir. Endovasküler girişimler ve cerrahi tedavi seçeneklerdir. Biz burada, olağan dışı lokalizasyonlu, biri penetran travma sonrası yüzeysel palmar arkta, diğeri künt travma sonrası yüzeysel temporal arterde oluşmuş iki psödoanevrizmayı sunuyoruz.

Anahtar Kelimeler: Anevrizma; yalancı; temporal arterler; yüzeysel palmar ark

INTRODUCTION

Pseudoaneurysms are pulsatile hematomas caused by localized arterial deterioration. They usually occur because of arterial interventions but may also occur because of macro or microtrauma or infections. Therefore, they are mostly localized in peripheral intervention sites, namely femoral or radial arteries. Pathologically, the artery wall is damaged, and the outer wall of the aneurysm sac is composed of the outer layers of the artery, perivascular tissue, blood clot, and reactive fibrous tissue. Pulsatile mass, thrill, and murmur on the mass are characteristic findings⁽¹⁾.

Traumatic arterial pseudoaneurysms are rare lesions usually caused by blunt or penetrating injuries. The thrombus, which may develop in the pseudoaneurysm, may be a source of embolism, leaving the distal tissue at risk of ischemia or necrosis⁽²⁾. Although pseudoaneurysms in the extremities can easily be diagnosed by Doppler ultrasound, computed tomography or magnetic resonance imaging is required for intraabdominal or intrathoracic pseudoaneurysms. Aneurysms < 2-3 cm in diameter may spontaneously undergo thrombosis. However, large aneurysms should be treated for complications such as rupture, infection, erosion of surrounding tissues, vascular thrombosis, or distal embolization. In the treatment, compression, thrombin or collagen injection, coil embolization, stent-graft implantation, and surgical repair are the preferred therapeutic options⁽³⁾.

Here we report two unusually located posttraumatic pseudoaneurysms, one in the superficial palmar arch following penetrating trauma and another in the superficial temporal artery following blunt trauma.

Cite this article as: Ünlü A, Durukan AB. Unusually located pseudoaneurysms: superficial palmar arc and superficial temporal artery. Koşuyolu Heart J 2019;22(1):63-5.

Correspondence

Ahmet Barış Durukan

E-mail: barisdurukan@yahoo.com

Submitted: 31.10.2018

Accepted: 22.11.2018

© Copyright 2019 by Koşuyolu Heart Journal.
Available on-line at
www.kosyoluheartjournal.com

CASE REPORT

Case 1

A 57-year-old male patient presented with severe pain following glass incision on the radial side of the palmar area that occurred 15 days ago. Pulsatile swelling was observed in the thenar region. There was no thrill or murmur on the swelling. Doppler ultrasound revealed a pseudoaneurysm with a diameter of 12 × 15 mm.

Intraoperatively, a pseudoaneurysm sac was seen and was extracted by an incision in the thenar region under local anesthesia (Figure 1). Primary repair was performed with a 7/0 prolene suture.

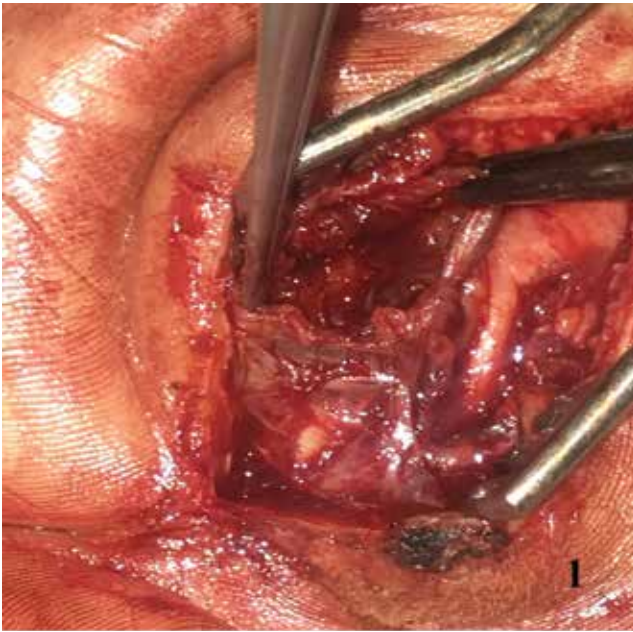


Figure 1. Intraoperative view of superficial palmar arc pseudoaneurysm in the thenar region.

Case 2

A 14-year-old male patient presented with a 5-month history of swelling in the left temporal region following blunt trauma. Physical examination revealed a minimally painful pulsatile mass in the left temporal region (Figure 2A). Doppler USG revealed a mass mimicking arteriovenous malformation with a diameter of 15 × 15 mm. A vascular lesion, which was consistent with a pseudoaneurysm originating from the frontal branch of the superficial temporal artery, was seen after the incision was made in the left temporal region under local anesthesia (Figure 2B). Unlike in classical pseudoaneurysms, it was observed that a thicker fibrotic tissue surrounded the sac, probably owing to a long history. The sac was removed and the defected arterial segment was repaired with a 7/0 prolene suture.

DISCUSSION

Pseudoaneurysms of the hand are rare lesions usually associated with blunt or penetrating trauma and iatrogenic injury. Clinically, localized tenderness, neurological symptoms owing to neural compression, arterial insufficiency, and ischemia findings owing to arterial thrombosis or aneurysmal dilatation are present. Early treatment is recommended to prevent possible embolization, rupture, or loss of function⁽⁴⁾.

Superficial temporal artery pseudoaneurysm was first described by Bartholin in 1740. It usually occurs a few weeks or months after blunt trauma. The superficial temporal artery is the terminal branch of the external carotid artery and is divided into two branches, frontal and parietal. Although facial, internal maxillary, and internal carotid artery pseudoaneurysms have been reported, superficial temporal artery is affected the most because it has a superficial course directly under the skin and is vulnerable to trauma. Differential diagnosis includes lipoma, hematoma, enlarged lymph node, neuroma, abscess, soft tissue tumor, epidermal inclusion cyst, arteriovenous fistula, intracranial lesions, subdural hematoma, middle meningeal artery aneurysm with temporal bone erosion, and angiofibroma⁽⁵⁾.

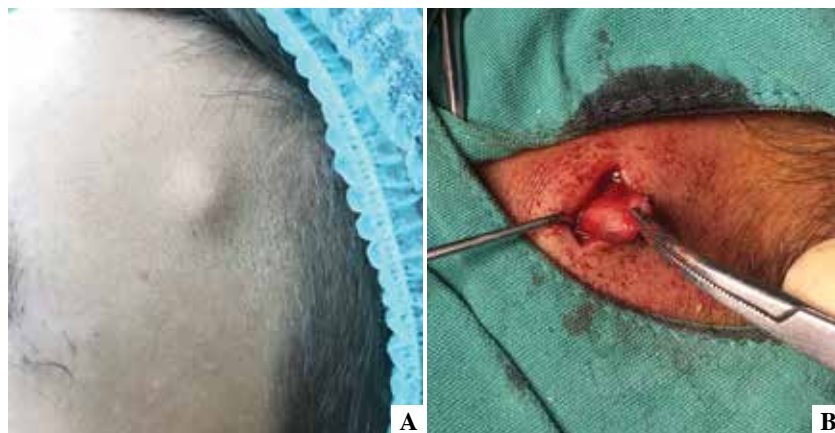

Figure 2. A) Preoperative view of the pulsatile mass in the left temporal region, (B) Intraoperative view of superficial temporal artery pseudoaneurysm prior to resection.

Presence of superficial palmar arc and superficial temporal artery pseudoaneurysms owing to blunt or penetrating trauma is very rare. Only a few cases have been reported in the literature and therefore, the incidence is not well known owing to the lack of sufficient data. However, in principle, the diagnostic methods, therapeutic indications, and choice of interventions do not differ from the above-mentioned pseudoaneurysms.

The main indications of surgical repair are cases that are symptomatic, those with tendency to expand accompanied by a large hematoma and persistence for at least 6 weeks. Pseudoaneurysms are not clinically relevant and involve the ulnar, radial, tibial, and perineal arteries in which the bloodstreamed areas have sufficient collateral circulation and can be treated simply by ligation of the artery. However, maintenance of arterial continuity should be preferred⁽⁶⁾. Both cases reported here were symptomatic; therefore, aneurysmectomy and primary repair was performed to maintain arterial continuity. The postoperative course and 3-month follow-up were uneventful for both.

CONCLUSION

The superficial palmar arch and the superficial temporal artery pseudoaneurysms are unusually located, and there are often limited data in the literature as case reports. Treatment strategies for superficial palmar arch and the superficial temporal artery pseudoaneurysms do not differ from that for other pseudoaneurysms. However, owing to unusual location and occasional exposure of these locations, a thorough review of the anatomy should be done prior to intervention.

REFERENCES

1. Luther A, Kumar A, Negi KNR. Peripheral arterial pseudoaneurysms-a 10-year clinical study. *Indian J Surg* 2015;77:S603-7.
2. Woodley-Cook J, Konieczny M, Simons M. The ulnar artery pseudoaneurysm. *BMJ Case Rep* 2015;2015.
3. Yasım A, Erođlu E. Periferik psödoanevrizmaların tedavisinde endovasküler stent greft uygulamaları: Bir kalp ve damar cerrahisi merkezinin altı yıllık sonuçları. *Damar Cer Derg* 2017;26:45-9.
4. Kitamura A, Mukohara N. Spontaneous pseudoaneurysm of the hand. *Ann Vasc Surg* 2014;28:739.e1-739.e3.
5. Rubio-Palau J, Ferrer-Fuertes A, García-Díez E, Garcia-Linares J, Martí-Pagès C, Sieira-Gil R. Traumatic pseudoaneurysm of the superficial temporal artery: case report and review of the literature. *Oral Surg Oral Med Oral Pathol Oral Radiol* 2014;117:112-4.
6. Kırılı K, Güler M, Mansurođlu D, Ömerođlu SN, Eren E, Özen Y ve ark. Ekstremitelerinin psödoanevrizmaları ve tedavisi. *Türk Göğüs Kalp Damar Cer Derg* 2000;8:802-4.