

Coronary Sinus: An Approach for Left Ventricular Pacing in a Patient Undergoing Tricuspid Valve Replacement



İbrahim Etem Çelik¹, Mustafa Duran¹, Sani Namık Murat¹

¹ Ankara Training and Research Hospital, Clinic of Cardiology, Ankara, Turkey

ABSTRACT

Permanent pacemaker implantation by the transvenous route in patients with a mechanical tricuspid valve has rarely been reported because of the difficulties in determining the appropriate pacing location. Herein, we present the case of a patient undergoing tricuspid valve replacement who required a permanent pacemaker using the coronary sinus.

Key Words: Mechanical valve; pacemaker; coronary sinus

Koroner Sinüs; Triküspit Replasmanı Olan Bir Hastada Sol Ventriküler Pacing Yolu

ÖZET

Pacing lokalizasyonunda zorluklar nedeniyle mekanik triküspit kapağı olan hastalarda transvenöz yol ile kalıcı pacemaker implantasyonu nadiren bildirilmiştir. Bu olguda, triküspit kapak replasmanı yapılan bir hastada koroner sinüs yoluyla sol ventriküler pacing sunuldu.

Anahtar Kelimeler: Mekanik kapak; kalıcı kalp pili; koroner sinüs

INTRODUCTION

One of the complications of tricuspid valve replacement (TVR) is bradyarrhythmia that frequently requires permanent pacing using epicardial or endocardial implantation. Transvenous endocardial pacemaker implantation is contraindicated in patients after prosthetic TVR. In these patients, a permanent epicardial pacemaker is frequently applied through anterolateral thoracotomy or sternotomy, but there are concerns regarding higher thresholds and limited lead survival. The other significant problems include tissue adherence and ventricular injury during dissection^(1,2). We describe an unusual approach for permanent pacemaker implantation using the coronary sinus (CS) after prosthetic TVR.

CASE REPORT

A 56-year-old woman with presyncope and exertional dyspnea (NYHA class 2) for 3 days was admitted to our emergency department. She had a history of rheumatic heart disease, and she underwent TVR (St. Jude valve) because of severe tricuspid valve regurgitation 28 days before presentation. After cardiac surgery, she was discharged without any complication. On physical examination, her blood pressure was 100/60 mmHg and heart rate was 42 beats/min. An electrocardiogram (ECG) showed idioventricular rhythm (Figure 1). Therefore, we considered permanent transvenous endocardial pacemaker implantation. She underwent CS catheterization via the left subclavian vein. After accessing the left subclavian vein, a guiding catheter was placed into the CS ostium, and CS angiography was performed (Figure 2A). An endocardial pacing lead was positioned into the anterolateral coronary vein for left ventricular (LV) pacing (Figure 2B). After implantation, ECG showed pace rhythm, and there was no lead dislodgement on chest X-Ray. The patient was discharged with an LV pacing threshold of 1.3 V at 0.4 ms and R-wave sensing of 7.8 mV.

Cite this article as: Çelik İE, Duran M, Murat SN. Coronary sinus: An approach for left ventricular pacing in a patient undergoing tricuspid valve replacement. Koşuyolu Heart J 2019;22(2):126-7.

Correspondence

İbrahim Etem Çelik

E-mail: etem84@gmail.com

Submitted: 26.02.2019

Accepted: 14.03.2019

© Copyright 2019 by Koşuyolu Heart Journal. Available on-line at www.kosuyoluheartjournal.com

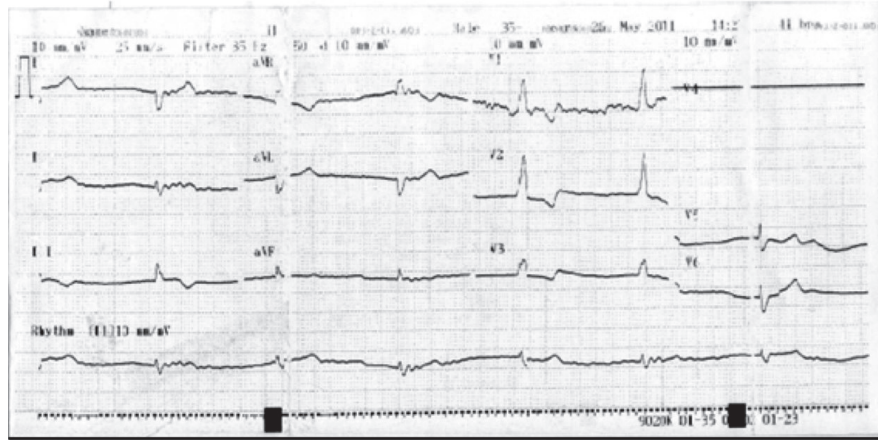


Figure 1. The 12-lead electrocardiogram showing idioventricular rhythm (Heart rate: 42 beats/min).

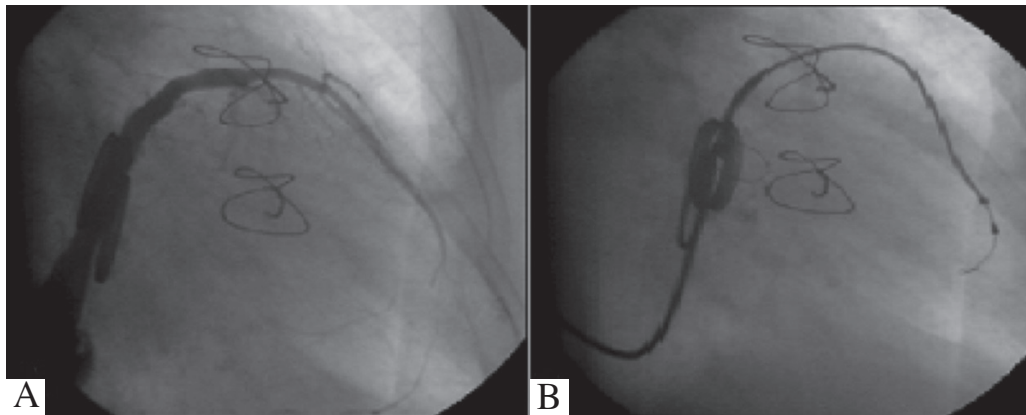


Figure 2. Anteroposterior view on coronary sinus angiography (A). Position of the lead in the anterolateral branch of the coronary sinus (B).

DISCUSSION

The need for ventricular pacing after TVR is common⁽¹⁾. However, there is no ideal method for permanent pacing in patients with a mechanical tricuspid valve. In these patients, permanent epicardial pacemaker is frequently used, but this method requires subxiphoid or anterolateral thoracotomy and general anesthesia, which are associated with higher morbidity and mortality as well as longer hospital stay⁽²⁾. Furthermore, tissue adherence and ventricular injury during dissection may be significant problems. Bai et al. first reported the use of LV pacing using the coronary vein in patients with tricuspid valve prostheses, and several reports have confirmed this procedure's long-term benefits^(3,4). Transvenous endocardial pacemaker implantation requires a minimally invasive procedure and improves cardiac function. Auricchio et al. reported that LV pacing increased the peak oxygen consumption, anaerobic threshold, distance walked in 6 min, and quality-of-life score of patients with congestive heart failure⁽⁵⁾. In addition, the development of LV pacing leads decreased the rate of lead dislodgement. On the other hand, there are some disadvantages of this method. The most encountered complications of LV pacing through the CS are CS dissection, diaphragmatic stimulation, and lead dislodgement⁽⁶⁾. Another rare complication is CS thrombosis.

In conclusion, ventricular pacing through the coronary vein is safe and a minimally invasive procedure for patients with a mechanical tricuspid valve. Therefore, LV pacing using the coronary vein in patients with a mechanical tricuspid valve requiring permanent ventricular pacing should be considered the first choice.

REFERENCES

1. Perenkil R, Wright JS. Endocardial pacing through a prosthetic tricuspid valve. *Pacing Clin Electrophysiol* 1990;13:1365-6.
2. Cooper JP, Jayawickreme SR, Swanton RH. Permanent pacing in patients with tricuspid valve replacements. *Br Heart J* 1995;73:169-72.
3. Bai Y, Strathmore N, Mond H, Grigg L, Hunt D. Permanent ventricular pacing via the great cardiac vein. *Pacing Clin Electrophysiol* 1994;17:678-83.
4. Winter J, Gramsch-Zabel H, Furst G, Koch JA, Zimmermann N, Gams E. Long-term follow-up of left ventricular pacing via a posterior cardiac vein after mechanical tricuspid valve replacement. *Pacing Clin Electrophysiol* 2001;24:125-6.
5. Auricchio A, Steelbrink C, Butter C, Sack S, Vogt J, Misier AR, et al. Pacing Therapies in Congestive Heart Failure II Study Group, Guidant Heart Failure Research Group. Clinically efficacy of cardiac resynchronization therapy using left ventricular pacing in heart failure patients stratified by severity of ventricular conduction delay. *J Am Coll Cardiol* 2003;42:2109-16.
6. Alonso C, Leclercq C, d'Alonnes FR, Pavin D, Victor F, Mobo P, et al. Six year experience of transvenous left ventricular lead implantation for permanent biventricular pacing in patients with advanced heart failure: technical aspects. *Heart* 2001;86:405-10.