

Pseudocoarctation of the Aorta Secondary to Paravertebral Paraganglioma



Paravertebral Paragangliomaya Sekonder Aort Psödokoarktasyonu

Muhammet Akyüz¹(iD), Onur Işık¹(iD), Ali Rahmi Bakiler²(iD)

¹ Department of Pediatric Cardiovascular Surgery, Izmir Tepecik Training and Research Hospital, Izmir, Turkey

² Department of Pediatric Cardiology, Izmir Tepecik Training and Research Hospital, Izmir, Turkey

A 14-year-old female patient was admitted due to elevated blood pressure with intermittent palpitation and headaches for 2 months without any significant family history. She had labile hypertension, first noted 1 month ago. She was started on a regimen of several antihypertensive medications. Over a span of a few months, the hypertension progressed, with her systolic blood pressure exceeding 200 mmHg. The highest blood pressure during the onset of symptoms was 210/120 mmHg. The pulse in all four extremities was similar, as was the blood pressure. On physical examination, vital signs were found to be within normal limits, with the exception of hypertension, and there were no palpable lymph nodes. Serum and urine catecholamine levels showed marked elevation.

Chest X-ray studies revealed a normal-sized heart. There was no evidence of rib notching or mediastinal widening. Electrocardiogram showed no abnormal findings. Transthoracic echocardiographic examination showed suspicious coarctation of the aorta with a 15 mmHg gradient. There was no left ventricular hypertrophy, aortic stenosis/regurgitation or bicuspid aortic valve. Chest X-ray revealed a paravertebral mass behind the heart (Figure 1). Computed tomography and magnetic resonance imaging revealed pseudocoarctation with limited poststenotic dilatation of the descending thoracic aorta and a 7 × 4 cm left paravertebral mass centred at T4-T7 without vertebral destruction that was pushing the descending aorta through the right hemithorax without intravascular extension (Figure 2,3). Complete resection of the mass was performed through posterolateral thoracotomy. Because of the absence of a significant gradient, surgical treatment of the pseudocoarctation was not considered. After complete resection of the tumour, the patient's blood pressure was stabilised. Histological examination revealed a paraganglioma. The patient recovered uneventfully and decreased using antihypertensive drugs postoperatively. She was discharged home on postoperative day 6, and she stopped using antihypertensive drugs at 6-month follow-up.

The most common aetiologies in children, in whom 70%-85% cases of hypertension have a secondary cause⁽¹⁾. Coarctation of the aorta is the second most common cause of hypertension in children. Pheochromocytomas are rare tumours responsible for approximately 0.5% cases of secondary hypertension⁽¹⁾.

Pseudocoarctation of the aorta is an uncommon anomaly that comprises kinking or buckling of the aortic arch and narrowing of the aortic isthmus^(2,3). Pseudocoarctation is usually asymptomatic, but it may be symptomatic depending on association with other pathologies^(2,4). All paragangliomas contain neurosecretory granules but few actually secrete catecholamines⁽⁵⁾. Most paragangliomas are relatively slow growing, non-functional and benign; however, some may be malignant or functional, potentially causing symptoms such as hypertension, tachycardia and diaphoresis⁽⁵⁾. Thoracic spine epidural paragangliomas are particularly rare, but they should be considered in the differential diagnosis of a well-circumscribed, enhancing epidural mass with or without extra-spinal paravertebral involvement^(4,5).

The incidence of other cardiovascular anomalies in association with pseudocoarctation has been increasing^(2,4). There have rarely been previous reports of pseudocoarctation of the aorta associated with mass compression. In our patient, there was a rare association of

Cite this article as: Akyüz M, Işık O, Bakiler AR. Pseudocoarctation of the aorta secondary to paravertebral paraganglioma. Koşuyolu Heart J 2019;22(3):216-7.

Correspondence

Muhammet Akyüz

E-mail: drmak100@gmail.com

Submitted: 12.04.2019

Accepted: 02.07.2019

© Copyright 2019 by Koşuyolu Heart Journal. Available on-line at www.kosuyoluheartjournal.com

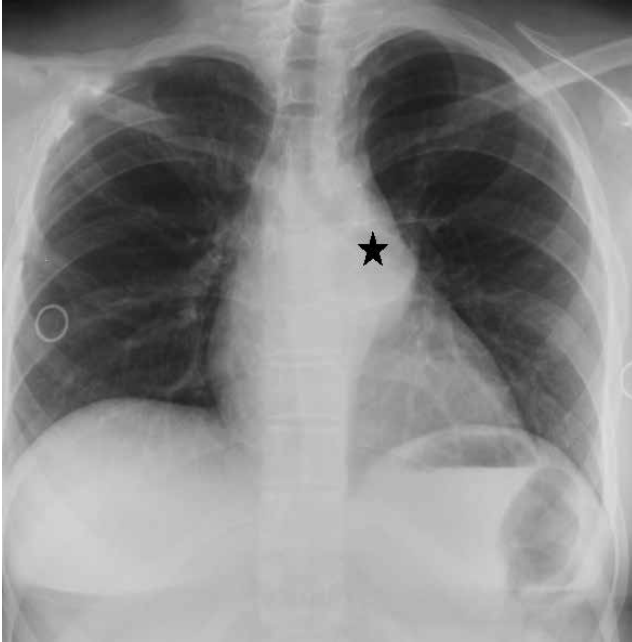


Figure 1. Chest X-ray demonstrated a paravertebral mass behind the heart (star).

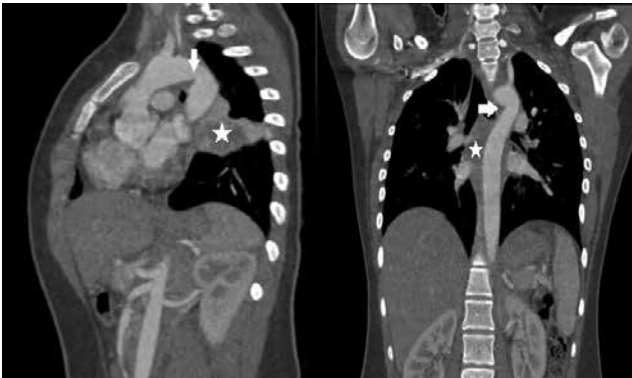

Figure 2. Computed tomography image revealed a pseudocoarctation with limited poststenotic dilatation of the descending thoracic aorta and the descending aorta pushed through the right hemithorax without intravascular extension.

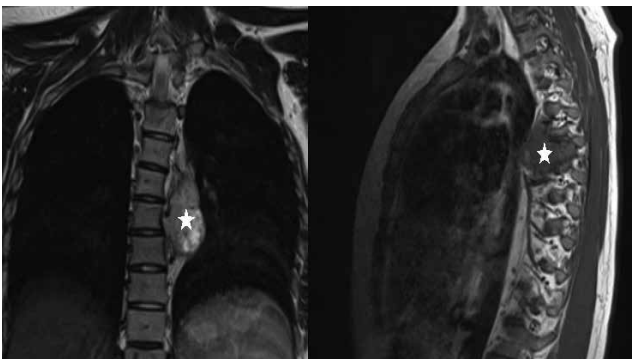


Figure 3. Magnetic resonance imaging revealed that the paravertebral mass was located between the descending aorta and T4-T7 vertebrae without vertebral destruction.

a pseudocoarctation due to the compression of a paravertebral paraganglioma.

Surgical treatment should be recommended for all symptomatic patients and for the cases of pseudocoarctation of the aorta associated with aneurysm formation. Surgical treatment is not necessary in patients who do not present with a significant pressure gradient across the lesion. Removal of the mass in patients with pseudocoarctation of the aorta secondary to any surrounding mass may provide benefits or reduce the risk of progression. Even so, patients with pseudocoarctation should be followed up using echocardiography.

REFERENCES

1. Chobanian AV, Bakris GL, Black HR, et al.; Joint National Committee on Prevention, Detection, Evaluation, and Treatment of High Blood Pressure; National Heart, Lung, and Blood Institute; National High Blood Pressure Education Program Coordinating Committee. Seventh report of the Joint National Committee on Prevention, Detection, Evaluation, and Treatment of High Blood Pressure. *Hypertension* 2003;42:1206-52.
2. Bluemke DA. Pseudocoarctation of the aorta. *Cardiol J* 2007;14:205-6.
3. Adaletli I, Kurugoglu S, Davutoglu V, Ozer H, Besirli K, Sayin AG. Pseudocoarctation. *Can J Cardiol* 2007;23:675-6.
4. Yang BZ. Pseudocoarctation of the aorta with aneurysm formation: case report. *Chin Med J* 2005;118:1230-2.
5. Simpson L, Hughes B, Karikari I, Mehta A, Hodges T, Cummings T, et al. Catecholamine-secreting paraganglioma of the thoracic spinal column. *Neurosurgery* 2012;70:1049-52.