

Internal Carotid Artery Aneurysm



İnternal Karotis Arter Anevrizması

Rezan Aksoy¹, Ekrem Yılmaz¹, Murat Bülent Rabuş¹

¹ University of Health Sciences, Istanbul Kartal Kosuyolu High Speciality Training and Research Hospital, Department of Cardiovascular Surgery, Istanbul, Turkey

A 65-year-old woman presented with dizziness and a mass causing pain in the left side of the neck. Physical examination revealed the presence of a pulsatile mass in the painful region. A computerized tomography angiogram identified a saccular aneurysm measuring 5.4 x 3.2 cm in the left internal carotid artery (ICA) without thrombus (Figure 1). Extracranial internal carotid artery aneurysm is defined as the dilatation of the ICA covering over 50% of its diameter and has a rare occurrence⁽¹⁾. Carotid artery aneurysms account for less than 1% of all the peripheral arterial aneurysms⁽²⁾. Although carotid artery aneurysms are rarely observed, their possibility should be considered in addition to glomus tumors in patients presenting with swelling in the neck.

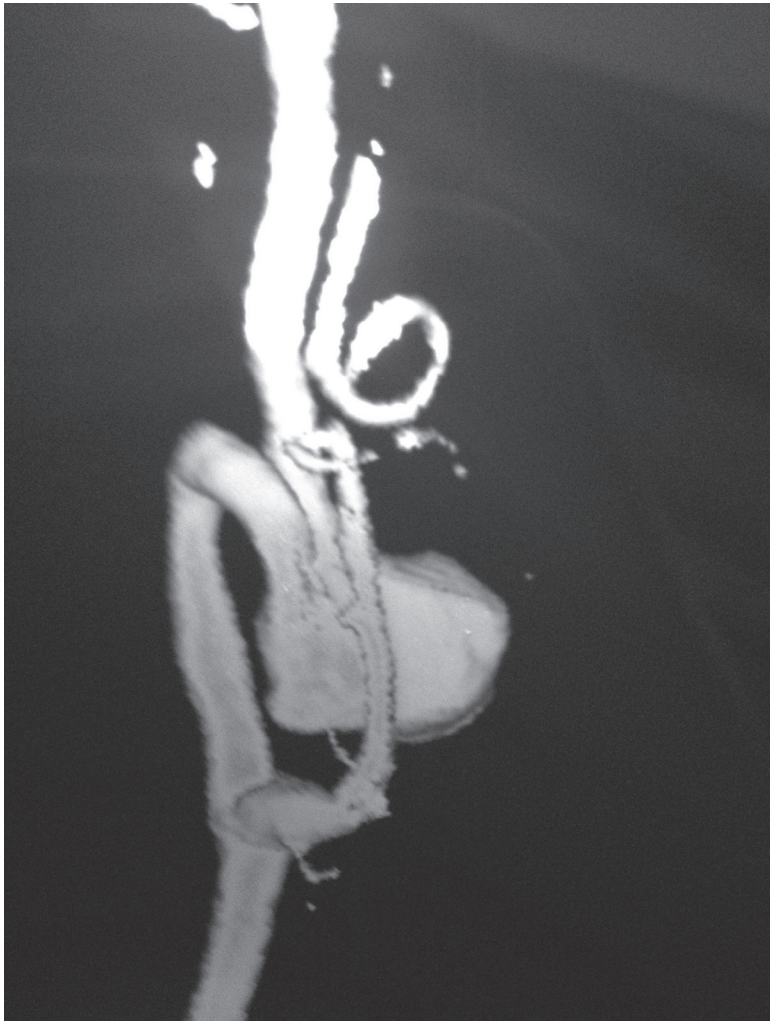


Figure 1.

Cite this article as: Aksoy R, Yılmaz E, Rabuş MB. Internal carotid artery aneurysm. Koşuyolu Heart J 2020;23(2):155-6.

Correspondence

Rezan Aksoy

E-mail: rezanaksoy@gmail.com

Submitted: 22.07.2020

Accepted: 23.07.2020

Available Online Date: 25.08.2020

© Copyright 2020 by Koşuyolu Heart Journal.

Available on-line at

www.kosuyoluheartjournal.com

Informed Consent: Written informed consent was obtained from patient who participated.

Peer-review: Externally peer-reviewed.

Author Contributions: Concept/Design – MR; Analysis/Interpretation – EY; Data Collection – RA; Writing – RA; Critical Revision – RA; Overall Responsibility – RA; Overall Responsibility - RA, EY, MR.

Conflict of Interest: The authors have no conflict of interest to declare.

Financial Disclosure: The authors declared that this study has received no financial support.

REFERENCES

1. Bardakçı H, Akgül A, Babaroğlu S, Kaplan S, Beyazıt M. Ekstrakraniyal internal karotis arter anevrizması; olgu sunumu. Damar Cer Derg 2006;15:49-52.
2. Longo GM, Kibbe MR. Aneurysms of the carotid artery. Semin Vasc Surg 2005;18:178-83.