

Early Detection of Ascending Aorta Dissection by Using the Right Parasternal Echocardiographic Window

Cem Bostan¹, Murat Başkurt², Nihan Turhan Çağlar³, Serdar Küçükoğlu³

1 İstanbul Üniversitesi Kardiyoloji Enstitüsü, Kardiyoloji Anabilim Dalı, İstanbul, Türkiye

2 Bilim Üniversitesi Avrupa Florence Nightingale Hastanesi Araştırma Uygulama Merkezi Kardiyoloji Anabilim Dalı, İstanbul, Türkiye

3 İstanbul Eğitim ve Araştırma Hastanesi, Kardiyoloji Kliniği, İstanbul, Türkiye

The right parasternal image is not a part of routine echocardiographic examination and is used seldomly. In cases of ascending aorta aneurysm and dissection this view may help to provide crucial information when the standard views are unable to visualise them adequately. Here we report a case of aortic dissection which was diagnosed early and easily by using the right parasternal image.

Keywords: Echocardiography; aortic dissection; right parasternal image

Sağ Parasternal Ekoardiografik Pencere Görüntüsü ile Çıkan Aorta Diseksiyonunun Erken Tanısı

Cem Bostan¹, Murat Başkurt², Nihan Turhan Çağlar³, Serdar Küçükoğlu³

1 İstanbul Üniversitesi Kardiyoloji Enstitüsü, Kardiyoloji Anabilim Dalı, İstanbul, Türkiye

2 Bilim Üniversitesi Avrupa Florence Nightingale Hastanesi Araştırma Uygulama Merkezi Kardiyoloji Anabilim Dalı, İstanbul, Türkiye

3 İstanbul Eğitim ve Araştırma Hastanesi, Kardiyoloji Kliniği, İstanbul, Türkiye

Sağ parasternal ekoardiografik pencere günlük pratikte sık kullanılmamaktadır. Çıkan aort anevrizması veya disseksiyon vakalarında standart görüntülere ek olarak tanıda ciddi katkı sağlayabilmektedir. Bizde vakamızda sağ parasternal ekoardiografik pencere görüntüsü ile hızlı ve net olarak çıkan aort diseksiyonu tanısı konabileceğini belirtmekteyiz.

Anahtar Kelimeler: Ekokardiyografi; aort diseksiyonu; sağ parasternal görüntü

Introduction:

If the echocardiographer uses only standard imaging planes (left parasternal, apical, subcostal, and suprasternal planes), he or she may fail to obtain vital information about the aorta, atrial septum, superior and inferior vena cavae, and the coronary arteries. The right parasternal image is not a part of routine echocardiographic examination and is usually not used in clinical practice. It has to be remembered that in cases of ascending aorta enlargement this view may provide satisfactory images of the ascending aorta.

Also, by using this window, the echocardiographer may accurately visualize the sites of the communication points and tears in cases of ascending aorta aneurysm and dissection (1,2,3). Here we report a case of aortic dissection which was diagnosed early and easily by using the right parasternal image.

Case Report:

A 65 years old female patient was admitted to emergency department with a sudden onset severe chest and back pain beginning 30 minutes ago. She had uncontrolled hypertension for 20 years and she was not taking her medicine regularly. She was a non-smoker and had no history of any operation. On physical examination she was mildly confused and her blood pressure was 80/60 mmHg and was equal in both arms. Her heart rate was 120 beats/minute and on cardiac auscultation there was a mid-systolic murmur radiating to the neck and an early diastolic murmur at the right sternal border. Her respiratory system examination was normal as well as the other systems. The surface electrocardiogram was normal. The chest radiograph revealed a mildly enlargement of the middle mediastinum. An emergent transthoracic echocardiogram was performed (Acuson Sequoia, Siemens Medical Solutions, Mountain view, CA, USA).

Multiple echocardiographic images were taken in standard views and a circumferential pericardial effusion compressing to the right atrium was the only detected abnormality in the apical four-chamber view. Then the transducer was located to the second right intercostal space and several images of the dilated and dissected ascending aorta (dissection line and prominent moving intimal tear) were easily taken from the right parasternal view by giving different angles and positions to the transducer (Figure 1). In the suprasternal view aortic arch was not dilated and the big vessels were seen not involved. An aortic aneurysm and dissection (DeBakey type II) was the diagnosis. The computerized tomography of the chest confirmed the diagnosis (Siemens Somatom Sensation 64, Siemens Medical Systems, Forchheim, Germany)(figure 2). An emergent surgery was decided. She was transferred to cardiovascular surgery center for emergent surgery.

Discussion:

This case reveals that ascending aorta dissection may be easily and accurately detected by right parasternal views of the transthoracic echocardiography. Right parasternal image is not a part of routine echocardiographic examination in clinical practice. In cases of ascending aorta aneurysm and dissection this view may help to provide crucial information regarding these areas when the standard views are unable to

delineate them adequately (1,2,3). In conclusion the right parasternal view should become part of a complete echocardiographic examination in any patient with suspected ascending aorta pathology.

References:

1-D'Cruz IA, Jain DP, Hirsch L, Levinsky R, Cohen HC, Glick C. Echocardiographic diagnosis of dilatation of the ascending aorta using right parasternal scanning. *Radiology* 1978, 129:465-469

2-D'Cruz IA, Jain M, Campbell C, Goldberg AN. Ultrasound visualization of aortic dissection by right parasternal scanning, including systolic flutter of the intimal flap. *Chest*. 1981, 80:239-242.

3-Marcella CP, Johnson LE. Right parasternal imaging: an underutilized echocardiographic technique. *J Am Soc Echocardiogr* 1993, 6:453-466.

Figure Legends

Figure1: Righth parasternal echocardiographic view of the patient

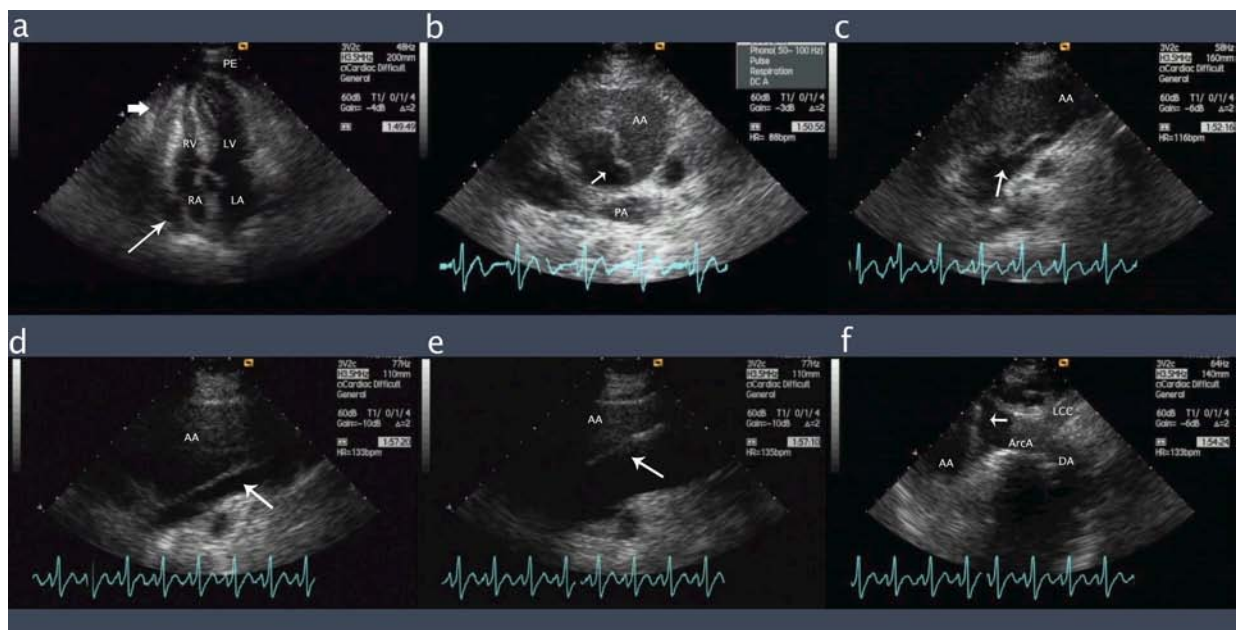


Figure 2: Tomographic views of the patient

