

Alternative Options for Accessing Radio Frequency Ablation Therapy



Radyofrekans Ablasyon Tedavisinde Alternatif Giriş Tercihi

Deniz Çevirme¹(ID), Hakan Hançer¹(ID), Rezan Aksoy¹(ID)

¹ University of Health Sciences, Istanbul Kartal Kosuyolu High Speciality Training and Research Hospital, Department of Cardiovascular Surgery, Istanbul, Turkey

Endovascular radiofrequency ablation of the great saphenous vein is an alternative treatment option for the surgical stripping of varicose veins. The surgeons can safely and effectively perform this procedure. The ablation is done by inserting a catheter base from the distal part of the great saphenous vein. The skin is punctured at the most preferable site using a needle. However, some situations require alternative regions for the insertion of the catheter and its withdrawal. The following images show such alternative solutions.

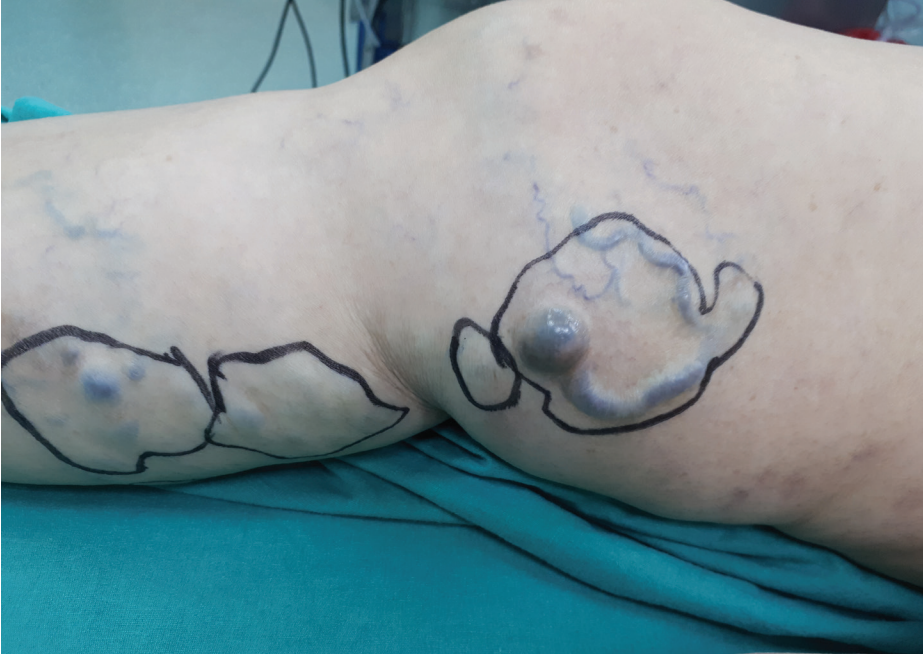

Figure 1. A 56-year-old female patient presented with venous insufficiency in the right leg. Doppler examination revealed grade 4 saphenofemoral junctional insufficiency along with a knee segment dilatation of 6 mm. Moreover, cystic dilatation was noticed in the venous branch segment at the distal medial thigh just over the right ankle.

Cite this article as: Çevirme D, Hançer H, Aksoy R. Alternative options for accessing radio frequency ablation therapy. Koşuyolu Heart J 2020;23(2):153-4.

Correspondence

Deniz Çevirme

E-mail: dnzcvr@hotmail.com

Submitted: 22.07.2020

Accepted: 23.07.2020

Available Online Date: 25.08.2020

© Copyright 2020 by Koşuyolu Heart Journal.
Available on-line at
www.kosuyoluheartjournal.com

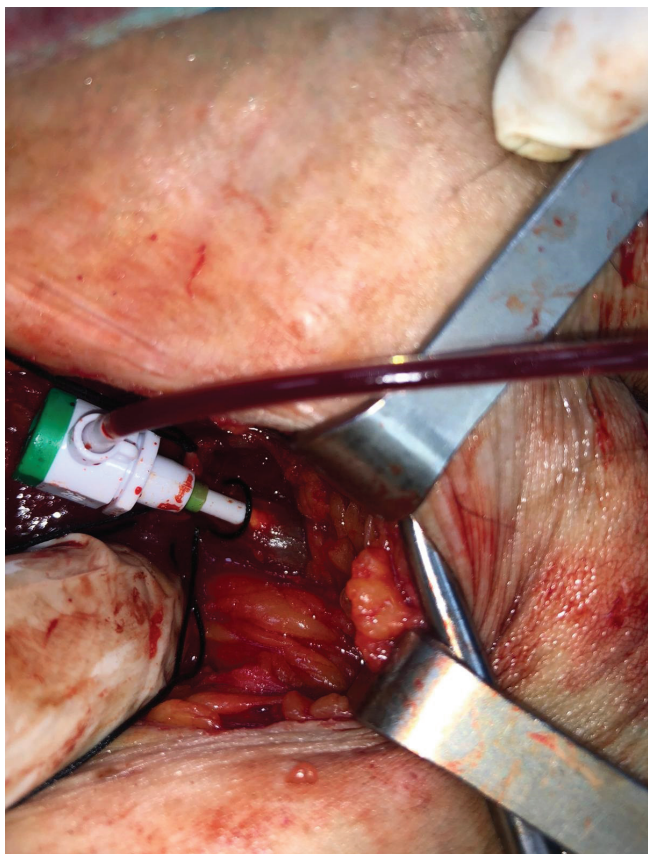


Figure 2. The classical approach involves puncturing the knee during the ablation therapy; however, a pathological segment was present in this case owing to cystic dilatation. A skin incision of 3 cm was made in the medial femoral region for exploring the saphenofemoral junction. Subsequently, a radiofrequency catheter was inserted in a retrograde manner for ablation, and the cystic dilatation was excised under local anesthesia.

Informed Consent: Written informed consent was obtained from patient who participated.

Peer-review: Externally peer-reviewed.

Author Contributions: Concept/Design – DÇ; Analysis/Interpretation – HH; Data Collection – DÇ; Writing – DÇ, HH; Critical Revision – RA; Final Approval – RA.

Conflict of Interest: The authors have no conflict of interest to declare.

Financial Disclosure: The authors declared that this study has received no financial support.