

# Impact of Percutaneous Mitral Balloon Valvuloplasty on P-Wave Dispersion in Patients with Rheumatic Mitral Stenosis



Hicaz Zencirkıran Ađuş, Serkan Kahraman

İstanbul Mehmet Akif Ersoy Cardiovascular Surgery Training and Research Hospital, Clinic of Cardiology, İstanbul, Turkey

## ÖZET

**Introduction:** P-wave dispersion (PWD) is a new electrocardiographic (ECG) index believed to reflect heterogeneous atrial conduction with ECG leads of different orientation. Mitral stenosis (MS) is associated with increased PWD, which are markers of atrial fibrillation (AF) risk. The aim of the present study was to assess the immediate effect of successful percutaneous mitral balloon valvuloplasty (PMBV) on these parameters.

**Patients and Methods:** Seventy patients (98% females, aged  $44 \pm 12$  years) with moderate or severe rheumatic MS and 60 healthy volunteers (95.7% females, aged  $45 \pm 11$  years) as a control group were enrolled in the study. 12-Lead ECGs were recorded for each patient 1 day before PMBV to evaluate baseline maximum and minimum P-wave duration and PWD and repeated within 72 h.

**Results:** The maximum P-wave duration (Pmax) and PWD in patients with MS were found to be significantly higher than those in the control group ( $p < 0.001$ ). ECG parameters of P<sub>max</sub> (142 (120-170) vs. 130 (110-164),  $p < 0.001$ ) and PWD [45 (30-69) vs. 35 (16-57),  $p < 0.001$ ] decreased in the acute period of PMBV ( $p < 0.001$ ). On the other hand, the procedure had no significant effect on minimum P-wave duration ( $p = 0.111$ ).

**Conclusion:** Our study has shown that P<sub>max</sub> and PWD were significantly higher in patients with MS than in healthy control subjects, and they decreased significantly after successful PMBV. Further prospective long-term studies are needed to confirm the relationship between atrial conduction velocities and development of AF in patients with MS.

**Key Words:** Mitral stenosis; percutaneous mitral balloon valvuloplasty; p-wave dispersion

## Romatizmal Mitral Stenozlu Hastalarda Perkütan Mitral Balon Valvüloplastinin P Dalga Dispersiyonu Üzerine Etkisi

### ÖZET

**Giriş:** P dalga dispersiyonu (PDD), farklı elektrokardiyografi (EKG) leadlerinden heterojen atriyal iletiyi yansıttığına inanılan yeni bir elektrokardiyografik indekstir. Mitral stenoz (MS), atriyal fibrilasyon (AF)'un bir göstergesi olan artmış PDD ile ilişkilidir. Çalışmamız başarılı perkütan mitral balon valvüloplastisi (PMBV)'nin bu parametreler üzerine olan etkisini incelemek için tasarlandı.

**Hastalar ve Yöntem:** Orta ve ciddi romatizmal mitral stenozu olan 70 (%98 kadın, ortalama yaş  $44 \pm 12$ ) hasta ve 60 (%95.7 kadın, ortalama yaş  $45 \pm 11$ ) sağlıklı kontrol grubu çalışmaya alındı. PMBV'den 1 gün önce ve yapıldıktan sonra 72 saat içinde 12 derivasyonlu EKG çekilerek maksimum ve minimum P dalga süresi, PDD hesaplandı.

**Bulgular:** Maksimum P dalga süresi ve PDD MS hastalarında kontrol grubuna göre anlamlı olarak fazla bulundu ( $p < 0.001$ ). P<sub>max</sub> [142 (120-170) vs. 130 (110-164),  $p < 0.001$ ] ve PDD [45 (30-69) vs. 35 (16-57),  $p < 0.001$ ], PMBV sonrası akut dönemde azaldı ( $p < 0.001$ ). Diğer yandan işlemin minimum P dalga süresi üzerine anlamlı etkisi olmadı ( $p = 0.111$ ).

**Sonuç:** Çalışmamızda MS'li hastalarda P<sub>max</sub> ve PDD'nin sağlıklı kontrol grubuna göre anlamlı olarak fazla olduğunu ve başarılı PMBV sonrası anlamlı derecede azaldığını gösterdik. MS'li hastalarda AF ile atriyal ileti velositeleri arasındaki ilişkiyi doğrulamak için prospektif uzun dönem takipli çalışmalara ihtiyaç vardır.

**Anahtar Kelimeler:** Mitral stenoz; perkütan mitral balon valvüloplastisi; p dalga dispersiyonu

### Correspondence

Hicaz Zencirkıran Ađuş

E-mail: hicazincir@yahoo.com

Submitted: 11.07.2018

Accepted: 13.10.2018

© Copyright 2018 by Koşuyolu Heart Journal.  
Available on-line at  
www.kosuyoluheartjournal.com

## INTRODUCTION

In developing countries, rheumatic mitral stenosis (MS) is still a significant cause of morbidity and mortality. The combination of mitral valve disease and atrial inflammation secondary to rheumatic carditis leads to left atrial (LA) dilation, fibrosis of the atrial wall, and disorganization of the atrial muscle bundles, leading to electrical inhomogeneity, non-uniform conduction velocities, and inhomogeneous refractory periods<sup>(1)</sup>. The resultant electrophysiological and electromechanical abnormalities are associated with a higher risk of atrial fibrillation (AF)<sup>(2)</sup>. P-wave dispersion (PWD) is a new electrocardiographic (ECG) index believed to reflect heterogeneous atrial conduction with ECG leads of different orientation. An increased maximum P-wave duration (Pmax) on surface ECG has been reported to be associated with LA size and risk of developing AF<sup>(3)</sup>. It has been defined as the difference between maximum and minimum P-wave duration. Percutaneous mitral balloon valvuloplasty (PMBV) is the procedure of choice in patients who have clinically severe MS and favorable mitral valve morphology for this procedure. In previous studies, it has been shown that PWD is increased in patients with MS and decreased in both short and long terms<sup>(4,5)</sup>. The aim of the present study was to assess the immediate effect of successful PMBV on PWD in patients with severe rheumatic MS in normal sinus rhythm.

## PATIENTS and METHODS

We retrospectively enrolled 70 patients (98% females, aged  $44 \pm 12$  years) with moderate or severe rheumatic MS who underwent successful PMBV in our clinic between 2009 and 2017 and 60 healthy volunteers (95.7% females, aged  $45 \pm 11$  years) as a control group. The control group had normal physical examination, standard 12-lead ECG, negative stress test, and normal echocardiographic examination. All patients were in sinus rhythm during evaluation. 12-Lead ECGs were recorded for each patient 1 day before PMBV to evaluate baseline maximum and minimum P-wave duration and PWD and repeated within 72 h. Transthoracic echocardiography (TTE) using Vivid S5 was performed for each patient. They also underwent transesophageal echocardiography 1 day before the procedure in order to rule out left atrium or appendage thrombosis. All patients' mitral regurgitation (MR) grade was  $< 2/4$ . Patients with significant valve disease other than secondary tricuspid regurgitation (TR), left ventricular (LV) hypertrophy, LV dysfunction, coronary heart disease, AF, bundle branch block or evidence of any other intraventricular conduction defect, previous pacemaker implantation, electrolyte abnormalities, hyperthyroidism, hypertension, diabetes mellitus, renal failure, taking any chronotropic medication, such as beta blockers or digitalis, were excluded from the study. Mitral valve anatomy was scored according to the Wilkins echo scoring system<sup>(6)</sup>. Written informed consent was obtained from all study subjects.

The indications for PMBV were symptomatic patients with moderate or severe MS (mitral valve area (MVA)  $\leq 1.5$  cm<sup>2</sup> by planimetry or mean transmitral diastolic gradient  $\geq 10$  mmHg) with favorable valve morphology, symptomatic patients with unfavorable valve morphology but at high risk for surgery, and asymptomatic patients with high thromboembolic risk and hemodynamic decompensation. Procedural success was defined as MVA  $> 1.5$  cm<sup>2</sup> without severe MR.

### Echocardiography

All patients underwent TTE using Vivid 5 ultrasound system before PMBV and repeated within 72 h. All measurements were measured according to the American Society of Echocardiography guidelines<sup>(7)</sup>. Cardiac dimensions and volumes were measured, and LV ejection fractions were calculated by the biplane Simpson's method. MVA was measured by planimetry and pressure half-time methods<sup>(8)</sup>. Continuous wave Doppler was used to calculate the mitral gradient and the peak pressure gradient of TR by using the Bernoulli equation. Color flow Doppler was used to detect the presence of MR. Semi-quantitative estimation of MR (mild, moderate, or severe) was made using color flow mapping in the parasternal long axis and apical four-chamber views. During echocardiographic evaluation, a continuous one-lead ECG recording was provided. Data were recorded from the average of three cardiac cycles. Additionally, transesophageal echocardiographic examinations were performed 1 day before the procedure for the evaluation of mitral valve morphology and exclusion of thrombosis.

### Electrocardiography

At a rate of 25 mm/s, 12-lead electrocardiogram in a supine position was recorded for each patient 1 day before and within 72 h after PMBV. P-wave durations were measured manually by one investigator blinded to the clinical details of the patient using digital calipers and magnifying lens (five-fold magnification) to define the ECG deflections. P-wave duration was measured from the onset to the offset of P-wave. The longest P-wave duration measured on any of the 12-lead ECGs was defined as the Pmax, and the shortest P-wave duration on any lead was defined as the minimum P-wave duration (P<sub>min</sub>). Thereafter, PWD was defined as the difference between maximum and minimum P-wave duration.

### Percutaneous Mitral Balloon Valvuloplasty

An experienced cardiologist performed all PMBV procedures via an antegrade transvenous approach with a transseptal Brockenbrough needle based on the technique described by Inoue et al.<sup>(9)</sup>. Initial balloon size was selected according to the body surface area. The final result was considered successful if the MVA was  $> 1.5$  cm<sup>2</sup> without severe MR ( $\leq 2/4$  MR).

### Statistical Analysis

Statistical analysis was made using the Statistical Package for the Social Sciences computer software (IBM SPSS Statistics

for Windows, version 21.0, released 2012; IBM Corp., Armonk, NY, USA). Data were expressed as mean (standard deviation) for variables with normal distribution, n (%) for categorical variables, and median (minimum-maximum) for variables with non-normal distribution. Fisher's exact test analysis was performed for categorical variables. Fitness to normal distribution was analyzed using the Kolmogorov-Smirnov test. Mann-Whitney U test was used for comparison of quantitative variables with non-normal distribution, whereas Student's t-test was used for comparison of means between the two groups with normal distribution. Pearson correlation tests were performed for correlations between ordinal variables or continuous variables with non-normal distribution. Paired sample t-test was used for related samples with normal distribution, whereas Wilcoxon signed-rank test was used for related samples with non-normal distribution. A p-value < 0.05 was considered statistically significant.

## RESULTS

Table 1 shows the demographic, clinical, and echocardiographic characteristics of the patient and control groups. All patients and controls had normal LV systolic function. The two groups were similar with respect to age, gender, LV ejection fraction, and LV dimensions ( $p > 0.05$ ), but LA diameter and pulmonary artery pressure (PAP) values were significantly higher in patients with MS. When we compared the two groups with regard to ECG parameters, baseline Pmax and PWD in patients with MS were found to be significantly higher than those in the control group ( $p < 0.001$ ) (Figure 1).

Table 2 shows the comparison of changes in ECG and echocardiographic parameters between baseline and after

PMBV. Statistically significant improvement in LA diameter, MVA, PAP, and max/mean mitral gradient was achieved in all patients after PMBV ( $p < 0.001$ ). ECG parameters of Pmax (142 (120-170) vs. 130 (110-164),  $p < 0.001$ ) and PWD [45 (30-69) vs. 35 (16-57),  $p < 0.001$ ] decreased in the acute period of PMBV ( $p < 0.001$ ). On the other hand, the procedure had no significant effect on Pmin ( $p = 0.111$ ) (Figure 2). The mean pre-PMBV MVA was  $1.056 \pm 0.17 \text{ cm}^2$  and significantly improved to  $1.83 \pm 0.30 \text{ cm}^2$  after PMBV ( $p < 0.001$ ). The median pre-PMBV mean gradient was 14 (4-33) mmHg, which significantly decreased to 5 (2-18) mmHg ( $p < 0.001$ ) within 72 h after PMBV. The median PAP 1 was 47.5 (30-120) mmHg and significantly decreased to 35 (20-120) mmHg ( $p < 0.001$ ).

PWD was significantly correlated with severity of MS (MVA ( $r = -0.8$ ,  $p < 0.0001$ ), max gradient ( $r = 0.74$ ,  $p < 0.0001$ ), mean grad ( $r = 0.77$ ,  $p < 0.0001$ ), PAP ( $r = 0.79$ ,  $p < 0.0001$ ), and LA ( $r = 0.76$ ,  $p < 0.0001$ )) (Figure 3).

## DISCUSSION

In our study, we found that Pmax and PWD were significantly longer in patients with clinically severe MS than in healthy control subjects and decreased within 72 h after PMBV. However, the echocardiographic parameters of MS were significantly correlated with PWD.

Rheumatic MS is an important health issue in developing countries<sup>(1)</sup>. The combination of mitral valve disease and atrial inflammation secondary to rheumatic carditis causes increased atrial stretch and dilatation, fibrotic changes within the wall of the atrium, and disorganization of the atrial muscle bundles<sup>(10)</sup>. These structural changes may lead to electrical inhomogeneity, disparate conduction velocities, and inhomogeneous refractory periods within the atrial myocardium reflecting on ECG as

**Table 1. The clinical, echocardiographic, and electrocardiographic parameters of patients with mitral stenosis and control subjects**


	Control	MS	P
Age (years)	44 ± 12	45 ± 11	0.570
Gender (female)	98%	95.7%	0.370
MVA	5 (4-6.2)	1.1 (0.7-1.6)	< 0.001
Max grad	3 (2-6)	23.5 (8-46)	< 0.001
Mean grad	1.50 (0.78-2.10)	14 (4-33)	< 0.001
PAP	15 (15-35)	48 (30-120)	< 0.001
LA diameter (cm)	30 (23-38)	44 (34-69)	< 0.001
LVEDD (cm)	44 (38-55)	45 (28-61)	0.266
LVESD (cm)	27 (22-39)	28 (19-43)	0.058
LVEF (%)	65 (50-65)	65 (50-67)	0.162
P <sub>max</sub> (ms)	119 ± 8	143 ± 11	< 0.001
P <sub>min</sub> (ms)	95 (28-118)	98 (75-125)	0.187
PWD (ms)	25 (10-35)	45 (30-69)	< 0.001

MS: Mitral stenosis, MVA: Mitral valve area, PAP: Pulmonary artery systolic pressure, LA: Left atrium, LVEDD: Left ventricle end-diastolic diameter, LVESD: Left ventricle end-systolic diameter, LVEF: Left ventricle ejection fraction, PWD: P-wave dispersion.

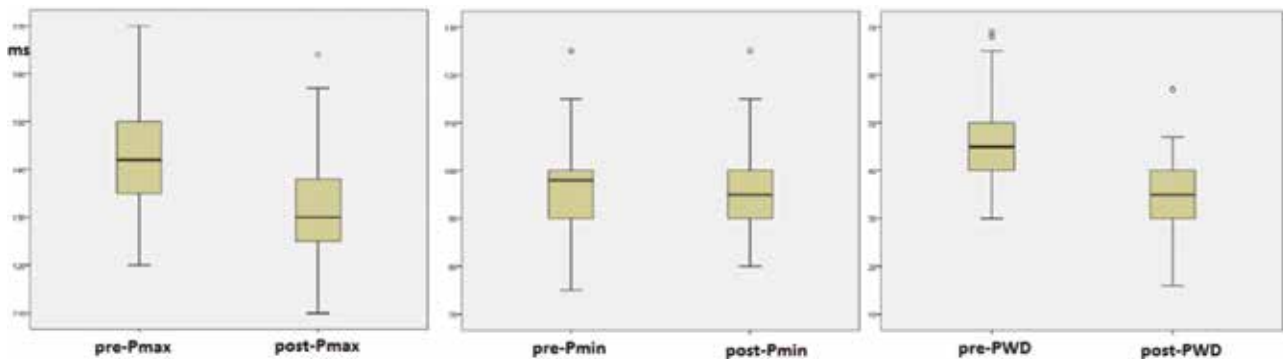
**Table 2. Baseline and after PMBV clinical, electrocardiographic, and echocardiographic characteristics of the patients**

	Before PMBV	After PMBV	p
MVA	1.056 ± 0.17	1.83 ± 0.30	< 0.001
Max grad	24.1 ± 8.06	12.29 ± 4.65	< 0.001
Mean grad	14 (4-33)	5 (2-18)	< 0.001
PAP	47.5 (30-120)	35 (20-120)	< 0.001
LA diameter (cm)	44 (34-69)	42 (31-54)	< 0.001
LVEDD (cm)	45 (28-61)	46 (33-57)	0.272
LVESD (cm)	28 (19-43)	28.5 (34-69)	0.87
LVEF (%)	65 (50-67)	65 (50-67)	0.383
P <sub>max</sub> (ms)	142 (120-170)	130 (110-164)	< 0.001
P <sub>min</sub> (ms)	98 (75-125)	95 (80-125)	0.111
PWD (ms)	45 (30-69)	35 (16-57)	< 0.001

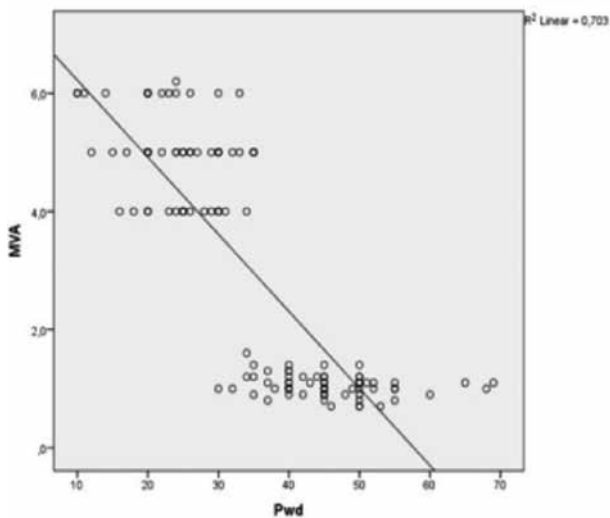
PMBV: Percutaneous mitral balloon valvuloplasty, MVA: Mitral valve area, PAP: Pulmonary artery systolic pressure, LA: Left atrium, LVEDD: Left ventricle end-diastolic diameter, LVESD: Left ventricle end-systolic diameter, LVEF: Left ventricle ejection fraction, PWD: P-wave dispersion.



**Figure 1.** Box plot representations for PWD,  $P_{max}$ , and  $P_{min}$  between control and patients with mitral stenosis. MS, mitral stenosis.



**Figure 2.** Box plot representations for PWD,  $P_{max}$ , and  $P_{min}$  between pre-PMBV and post-PMBV patients. PMBV, percutaneous mitral balloon valvuloplasty.



**Figure 3.** Correlation analysis of PWD with MVA. PWD, P-wave dispersion; MVA, mitral valve area.

increased  $P_{max}$  and PWD<sup>(3)</sup>. Increased  $P_{max}$  and PWD are well-known ECG markers of non-uniform and heterogeneous atrial conduction. Various studies have demonstrated their association with LA size and risk of developing AF<sup>(3,11,12)</sup>. Dilaveris et

al. were the first to describe PWD as the difference between maximum and minimum P-wave duration<sup>(3)</sup>.

Previous studies have shown that PWD is increased in patients with rheumatic MS<sup>(4,5,13,14)</sup>. Turhan et al. showed a decrease in  $P_{max}$  and PWD in both short and long terms after PMBV<sup>(4)</sup>. In accordance with those studies, we found a significantly higher PWD for patients with MS than for control subjects, and it was correlated with the echocardiographic parameters of MS significance. We also found that  $P_{max}$  and PWD significantly decreased within 72 h after PMBV as previously described by other studies<sup>(13-15)</sup>. Demirkan et al. have shown in a study including 30 patients with moderate and severe MS that there is a statistically significant decrease in atrial electromechanical delay with  $P_{max}$  and PWD in the early period after PMBV (in 72 h)<sup>(13)</sup>. In addition, in electrophysiological studies in patients undergoing PMBV, owing to the relief of atrial stretch after the procedure, an immediate improvement in conduction abnormality was detected<sup>(16)</sup>. The decline of PWD immediately after PMBV was not supported by Beig et al.; they found a statistically significant decrease in inter- and intra-atrial electromechanical delays and believed that surface ECG manifestations of delayed and heterogeneous atrial conduction may take time to resolve. This needs confirmation on follow-up<sup>(17)</sup>.

All these findings suggest that PWD is increased in MS, and mechanical dilation of the mitral valve with a balloon reduces susceptibility to AF even in the early period. Therefore, PWD can be used to classify patients with a high risk of AF during sinus rhythm.

### Limitations

The main limitation of our study was that we measured the conduction times only with ECG but did not use echocardiographic and electrophysiological studies to validate our results. Second, we do not have long-term follow-up data. Hence, the relationship between these parameters and the development of AF is not clearly known. The present study was conducted at a single center. Further large-scale and long-term studies may be necessary to assess the clinical impact of Pmax and PWD on the prevention of AF.

### CONCLUSION

In conclusion, our study has shown that Pmax and PWD were significantly higher in patients with MS than in healthy control subjects. In addition, they decreased significantly after successful PMBV. These simple ECG indices may predict the success of the procedure after PMBV and susceptibility to AF. Further prospective long-term studies are needed to confirm the relationship between atrial conduction velocities and development of AF in patients with MS.

### CONFLICT of INTEREST

The authors declare that they have no conflict of interest related to this article.

### AUTHORSHIP CONTRIBUTIONS

*Concept/Design:* HA, SK

*Analysis/Interpretation:* SK

*Data Acquisition:* HA

*Writing:* SK

*Critical Revision:* HA, SK

*Final Approval:* All of authors

### REFERENCES

- Otto CM, Bonow RO. Valvular heart disease. In: Libby P, Bonow RO, Mann DL, Zipes DP, Braunwald E (eds). In: Braunwald's Heart Disease: A Text Book of Cardiovascular Medicine 8<sup>th</sup> ed. Philadelphia: Saunders Elsevier, 2008:1646-57.
- Josephson ME, Kastor JA, Morganroth J. Electrocardiographic left atrial enlargement. Electrophysiologic, echocardiographic and hemodynamic correlates. *Am J Cardiol* 1977;39:967-71.
- Dilaveris PE, Gialafos EJ, Sideris SK, Theopistou AM, Andrikopoulos GK, Kyriakidis M, et al. Simple electrocardiographic markers for the prediction of paroxysmal idiopathic atrial fibrillation. *Am Heart J* 1998;135:733-8.
- Turhan H, Yetkin E, Senen K, Yılmaz MB, Ileri M, Atak R, et al. Effects of percutaneous mitral balloon valvuloplasty on P-wave dispersion in patients with mitral stenosis. *Am J Cardiol* 2002;89:607-9.
- Erbay AR, Turhan H, Yasar A, Bicer A, Senen K, Sasmaz H, et al. Effects of long term beta blocker therapy on P wave duration and dispersion in patients with rheumatic mitral stenosis. *Int J Cardiol* 2005;22:102:33-7.
- Wilkins GT, Weyman AE, Abascal WM, Block PC, Palacios IF. Percutaneous mitral balloon valvulotomy: an analysis of echocardiographic variables related to outcome and the mechanism of dilatation. *Br Heart J* 1988;60:299-308.
- Schiller NB, Shah PM, Crawford M, DeMaria A, Devereux R, Feigenbaum H, et al. Recommendations for quantitation of the left ventricle by two-dimensional echocardiography. American Society of Echocardiography Committee on Standards, Subcommittee on Quantitation of Two-Dimensional Echocardiograms. *J Am Soc Echocardiography* 1989;2:358-67.
- Hatle L, Angelsen B, Tromsdal A. Noninvasive assessment of atrioventricular pressure half-time by Doppler ultrasound. *Circulation* 1979;60:1096-104.
- Inoue K, Owaki T, Nakamura T, Kitamura F, Miyamoto N. Clinical application of transvenous mitral commissurotomy by a new balloon catheter. *J Thorac Cardiovasc Surg* 1984;87:394-402.
- Alpert JS, Sabik J, Casgrove DM. Mitral valve disease. In: Topol EJ (ed). *Textbook of cardiovascular medicine*. New York: Lippincott-Raven Publishers, 1998;505-6.
- Dilaveris PE, Gialafos EJ, Andrikopoulos GK, Richter DJ, Papanikolaou V, Poralis K, et al. Clinical and electrocardiographic predictors of recurrent atrial fibrillation. *Pacing Clin Electrophysiol* 2000;23:352-8.
- Buxton AE, Waxman HL, Marchlinski FE, Josephson ME. Atrial conduction: effects of extrastimuli with and without atrial dysrhythmias. *Am J Cardiol* 1984;54:755-61.
- Demirkan B, Guray Y, Guray U, Ege MR, Kisacik HL, Sasmaz H, et al. The acute effect of percutaneous mitral balloon valvuloplasty on atrial electromechanical delay and P-wave dispersion in patients with mitral stenosis. *Herz* 2013;38:210-5.
- Guler A, Bulut M, Dundar C, Tigen K, Karaahmet T, Güler Y, et al. Atrial electrical and electromechanical characteristics in patients with rheumatic mitral stenosis. *Koşuyolu Heart J* 2017;20:1-6.
- Kazemi B, Rostami A, Aslanabadi N, Ghaffari S. Electrocardiographic P-wave indices as a useful tool to predict successful percutaneous balloon mitral valvotomy in patients with mitral stenosis. *J Cardiovasc Thorac Res* 2014;6:9-14.
- Coronel R, Langerveld J, Boersma LV, Wever EF, Bon L, van Dessel PF, et al. Left atrial pressure reduction for mitral stenosis reverses left atrial direction dependent conduction abnormalities. *Cardiovasc Res* 2010;85:711-8.
- JR Beig, HA Trambo, Hafeez I, Ananth V, Lone AA, Yagoob I, et al. Immediate effect of percutaneous transvenous mitral commissurotomy on atrial electromechanical delay and P-wave dispersion in patients with severe mitral stenosis. *Indian Heart J* 2015;67(Suppl 2):S46-54.