



# Effects of Polyglyconate (Maxon) Suture Reinforced Sternum Closure Technique on Aseptic Sternal Dehiscence in High Risk Patients

Emin Can Ata<sup>1</sup>, Yüksel Dereli<sup>2</sup>

<sup>1</sup> Department of Cardiovascular Surgery, IMC Hospital, Mersin, Turkey

<sup>2</sup> Department of Cardiovascular Surgery, Necmettin Erbakan University, Meram Medicine Faculty, Konya, Turkey

## ABSTRACT

**Introduction:** Sternal dehiscence is a serious complication after cardiac surgery. The main objective of this study will be to determine the effects of polyglyconate suture (Maxon) reinforced sternum closure technique on prevention of aseptic sternal dehiscence in high-risk patients.

**Patients and Methods:** This retrospective study (December 2011 to January 2013) comprised 136 consecutive patients undergoing standard median sternotomy for cardiac procedures. All of these patients have one or more risk factor of sternal dehiscence such as obesity, osteoporosis, chronic obstructive pulmonary disease and chronic active cigarette smoker. In all patients, in addition to steel wire during sternal closure polyglyconate sutures were placed, passing through the intercostal space.

**Results:** No sternal dehiscence or mediastinit occurred these patients. Only 3 patients (2.2%) were observed superficial wound infection at lower part of sternum without sternum dehiscence and treated successfully by antibiotic therapy.

**Conclusion:** This study shows that besides the classic steel wire, additional polyglyconate sutures placed intercostal spaces can be enhance sternum stability and prevent aseptic sternal dehiscence in high risk patients.

**Key Words:** Sutures; maxon; wound dehiscence, surgical; sternum

## Yüksek Riskli Hastalarda Poliglikonat (Maxon) Sütürle Desteklenen Sternum Kapama Tekniğinin Aseptik Sternal Ayrışma Üzerine Etkisi

### ÖZET

**Giriş:** Sternal ayrışma, kardiyak cerrahi sonrası ciddi bir komplikasyondur. Bu çalışmanın temel amacı yüksek riskli hastalarda poliglikonat sütür (Maxon) ile desteklenen sternum kapama tekniğinin sternal ayrışmayı önlemedeki etkinliğinin araştırılmasıdır.

**Hastalar ve Yöntem:** Bu retrospektif çalışmaya, (Aralık 2011-Ocak 2013), kardiyak cerrahi için standart median sternotomi uygulanan 136 hasta dahil edildi. Tüm hastalar sternal ayrışma için obezite, osteoporoz, kronik obstrüktif akciğer hastalığı, kronik aktif sigara içiciliği gibi bir veya daha fazla risk faktörüne sahipti. Tüm hastalarda sternum kapatılması esnasında çelik tele ilave olarak interkostal aralıklardan geçilerek poliglikonat sütürler konuldu.

**Bulgular:** Hiçbir hastada sternal ayrışma veya mediastinit görülmedi. Sadece 3 hastada (%2.2), sternal ayrışma olmadan sternum alt kısmında yüzeysel yara enfeksiyonu gözlemlendi ve bunlar da antibiyotik tedavisi ile başarıyla tedavi edildi.

**Sonuç:** Bu çalışma, yüksek riskli hastalarda, klasik çelik tele ilave olarak interkostal aralıklardan poliglikonat sütürler geçilerek desteklenen sternum kapama yönteminin sternal stabiliteyi artırdığını ve aseptik sternal ayrışmayı önlediğini göstermektedir.

**Anahtar Kelimeler:** Cerrahi sütür; makson; cerrahi yara ayrışması; sternum

## INTRODUCTION

Despite improvements in surgical techniques, anesthesia and antibiotic treatment, postoperative sternal dehiscence still represents a significant and serious complication after cardiac operations. Treatment of this condition is both time and economic resource consuming process. The origin of this condition has multiple causes and includes factors such as obesity, chronic obstructive pulmonary disease (COPD) and osteoporosis. The

## Yazışma Adresi

Yüksel Dereli

E-posta: yuxel.derele@mynet.com

Geliş Tarihi: 15.11.2014

Kabul Tarihi: 15.12.2014

© Copyright 2015 by Koşuyolu Heart Journal.  
Available on-line at  
www.kosuyolukalpdergisi.com

incidence of this complication is 2.5% and increases up to 5.6% in patients with at least one risk factor such as obesity, advanced age, diabetes, COPD and prolonged extracorporeal circulation and mechanical ventilation<sup>(1,2)</sup>. Thus, reinforced sternal closure for prevention of sternal dehiscence in high-risk patients is necessary<sup>(3-6)</sup>. In our study, we placed 4 to 6 (average 5) polyglyconate (Maxon) sutures additionally to intercostal spaces besides conventional three or four figure-eight wire sutures in these selected 136 high risk patients and observed whether sternal dehiscence occurs.

## PATIENTS and METHODS

We selected 136 patients undergone open heart surgery from December 2011 to January 2013. The average age was  $62.9 \pm 22$  years, ranging from 42 to 86 years. There were 78 (57.4%) male patients and 58 (42.6%) female patients. All patients had one or more comorbid factors such as obesity (body mass index (BMI) > 30 kg/m<sup>2</sup>), osteoporosis (by direct vision to sternum perioperatively), mild to severe COPD (FEV1 < 80% and FEV1/FVC < 70% by spirometry) and active cigarette smoker (more than 15year/1pack) (Table 1). Median sternotomy was performed all of the patients. Operations includes coronary artery bypass graft (CABG) (n= 119), isolated mitral valve replacement (MVR) (n= 5) or aortic valve replacement (AVR) (n=2), CABG and valve replacement (n= 8) and ascending aortic aneurysm repair (n= 2) (Table 2).

All patients underwent standard median sternotomy and operations was done under cardiopulmonary bypass (CPB) and aortic cross clamping. Cephalosporin was used for prophylactic purpose routinely. Skin, subcutaneous tissue and sternum was cleaned by povidone iodine surgical scrub solution before closure. Six to eight sternal steel wire were used according to the length of sternum either in figure-eight or through and through fashion. Before the sternal wires tied, four to six (average five) polyglyconate (Maxon) sutures (Maxon™ Polyglyconate, Monofilament Synthetic Absorbable Sutures-Covidien) were

**Table 1. Demographic data**

Patient Characteristics	
Total patients	136
Sex	Male: 78 (57.4%), Female: 58 (33.6%)
Age	62.9 ± 22 (Range from 42 to 86)
Obesity (BMI > 30kg/m <sup>2</sup> )	54 (39.7%)
Morbid obesity (BMI > 40kg/m <sup>2</sup> )	5 (3.7%)
Osteoporosis	39 (28.7%)
COPD (FEV1 < 80%, FEV1/FVC < 70%)	30 (22%)
Active cigarette smoker (>15 year/1 pack)	73 (53.7%)
Single risk patients	84 (61.8%)
Multiple risk patients	52 (38.2%)

**Table 2: Types of operations**

Procedures	Number of patients
CABG	119 (87.5%)
MVR	5 (3.68%)
AVR	2 (1.45%)
CABG+MVR	4 (2.94%)
CABG+AVR	3 (2.2%)
CABG+AVR+MVR	1 (0.74%)
Ascending aortic aneurysm repair	2 (1.45%)
Total	136

additionally placed intercostal spaces (Figure-1). If osteoporosis identified one or two more polyglyconate sutures were used. After all sutures were placed, wires were tied first and then the polyglyconate sutures were tied very tightly (this is the key part of this method) (Figure-2). Subcutaneous tissues and skin was sutured as usually fashion.

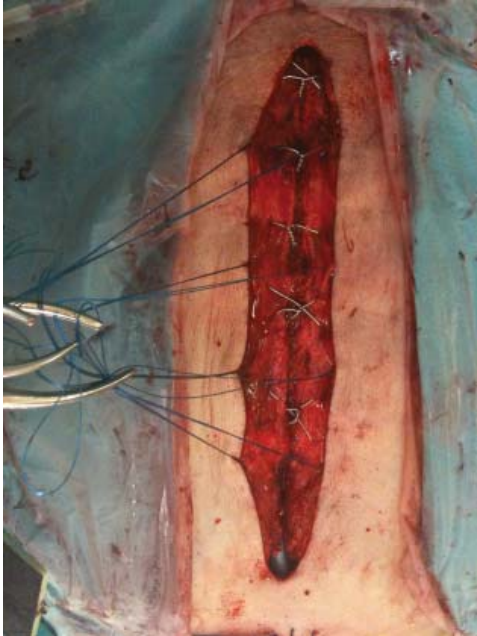## RESULTS

After seven weeks (ranged five to ten weeks) of follow-up period, none of the 136 patients occurred sternal dehiscence and no patients undergone sternal reconstruction operations. Three patients (2.2%) occurred superficial skin infection at lower sternum without sternal dehiscence and mediastinitis. All of the three patients were diabetic and morbid obese (BMI > 40kg/m<sup>2</sup>). Two of them have staphylococcus aureus infections and the other patients' wound culture was negative. All of these patients were successfully treated by antibiotic therapy and prophylaxis. Except five morbid obese patients (3.7%), no patients were subjected to prophylactic thoracic corset or bandage.

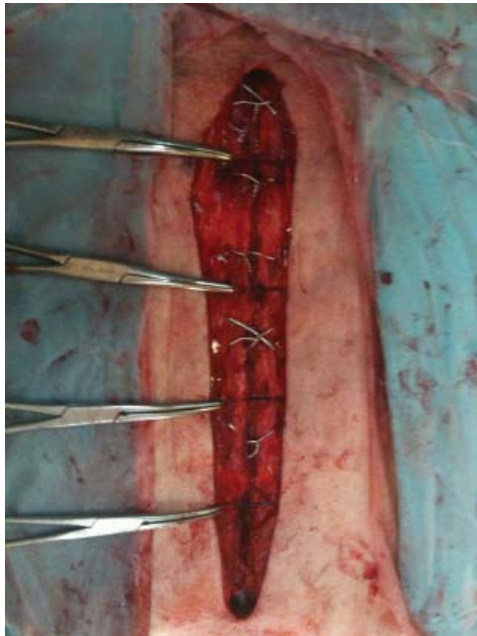
## DISCUSSION

Sternal dehiscence is a very serious complication after cardiac surgery. It leads to high mortality and morbidity, due to the instability of the chest wall and the frequently concurrent presence of infection. Sternal dehiscence usually occurs when the wire or cable cuts through the bone and causes multiple fractures of the sternum. In some cases does it occur because of breakage of the suture material especially among the patients with high density bone structure concurrent high intrathoracic pressure associating persistent prolonged coughs in active cigarette smoker. Molina et al. had determined 6.25% of sternal dehiscence rate among obese patients with conventional closure technique in their study<sup>(1)</sup>. Schimmer et al. concluded in their review that osteoporotic or fractured sternum and obesity were more important risk factors of sternal dehiscence<sup>(4)</sup>.

Despite several techniques were described to handle sternal dehiscence, little dehiscence protective techniques was studied. The Robicsek sternoplasty is the most effective technique in terms of both protection and reconstruction of sternum. But this technique is somehow troublesome and if care is not taken unwanted devastating results can be occur in osteoporotic patients<sup>(7)</sup>. Thermoreactive nitinol clips, rigid plate fixation,



**Figure 1.** Before the sternal wires tied, polyglyconate (Maxon) sutures were additionally placed intercostal spaces.



**Figure 2.** After all sutures were placed, wires were tied first and then the polyglyconate (Maxon) sutures were tied very tightly.

sternum external fixation corset, kryptonite bone adhesive, sternoband studies shows their effectiveness to prevent dehiscence, but it's obvious that these materials will increase hospital costs in some degree<sup>(8-12)</sup>.

Tekümit et al. compared the effects of two sternal closure techniques, simple wire technique and figure-of-eight technique, on the development and outcome of non-microbial

sternal dehiscence<sup>(13)</sup>. In this study, present findings suggest that the most commonly used sternal closure techniques, figure-of-eight technique and simple wire technique, may have similar outcomes in terms of development and prognosis of non-microbial dehiscence in patient undergoing isolated on-pump CABG operations. Luciani et al. used polydiacxonone suture alone in high risk patients and addressed lower incidence of aseptic dehiscence than conventional wire sutured patients<sup>(14)</sup>. Hamaji et al. studied reinforced closure of the sternum with absorbable pins for high-risk patients, and decreased sternal complications<sup>(5)</sup>.

In this study, we used inexpensive but very strong material; polyglyconate (Maxon) suture. Maxon is a synthetic, absorbable, monofilament suture. It is a copolymer of glycolide and trimethylene carbonate. Maxon can be used for the deep and superficial portions of a closure. Tensile strength was measurable for 42 to 92 days for Maxon. Absorption of Maxon is complete in 6 to 7 month sand this period is sufficient for sternal recovery<sup>(15)</sup>. We believe that, unlike the steel wire, this type of suture doesn't cut through the sternum and suture breakage doesn't occur because of it's durable and elastic characteristics. We used six polyglyconate sutures in patients with osteoporotic or high density sternum those who the steel wire more likely cut through the sternum or wire breakage will occur. Four or five polyglyconate sutures were used the rest patients. Three or four figure-eight steel wires combined used with polyglyconate suture in all of the patients.

## CONSLUSION

Combined use of steel wire with polyglyconate suture can protect high risk patients from aseptic sternal dehiscence but not from sternal wound infection. This is a very simple, safe, inexpensive, and effective technique. Limitation of our study is that this is not case - control study. Further randomised-control study will be needed before routinely use of this technique.

## CONFLICT of INTEREST

The authors reported no conflict of interest related to this article.

## AUTHORSHIP CONTRIBUTIONS

*Concept/Design:* YD, EA

*Analysis/Interpretation:* YD, EA

*Data acquisition:* YD, EA

*Writing:* YD, EA

*Critical revision:* YD, EA

*Final approval:* YD, EA

## REFERENCES

1. Molina JE, Lew RS, Hyland KJ. Postoperative sternal dehiscence in obese patients: Incidence and prevention. *Ann Thorac Surg* 2004;78:912-7.
2. Celik S, Kirbas A, Gurer O, Yildiz Y, Isik O. Sternal dehiscence in patients with moderate and severe chronic obstructive pulmonary disease undergoing cardiac surgery: The value of supportive thorax vests. *J Thorac Cardiovasc Surg* 2011;141:1398-402.

3. Kamiya H, Al-maisary SS, Akhyari P, Ruhparwar A, Kallenbach K, Lichtenberg A, et al. The number of wires for sternal closure has a significant influence on sternal complications in high-risk patients. *Interact Cardiovasc Thorac Surg* 2012;15:665-70.
4. Schimmer C, Reents W, Elert O. Primary closure of median sternotomy: A survey of all German surgical heart centers and a review of the literature concerning sternal closure technique. *Thorac Cardiovasc Surg* 2006;54:408-13.
5. Hamaji M, Sakaguchi Y, Matsuda M, Kono S. Reinforced closure of the sternum with absorbable pins for high-risk patients. *Interact Cardiovasc Thorac Surg* 2009;9:559-61.
6. Riess FC, Awwad N, Hoffmann B, Bader R, Helmold HY, Loewer C, et al. A steel band in addition to 8 wire cerclages reduces the risk of sternal dehiscence after median sternotomy. *Heart Surg Forum* 2004;7:387-92.
7. Robicsek F, Daugherty HK, Cook JW. The prevention and treatment of sternum separation following open-heart surgery. *J Thorac Cardiovasc Surg* 1977;73:267-8.
8. Raman J, Lehmann S, Zehr K, De Guzman BJ, Aklog L, Garrett HE, et al. Sternal closure with rigid plate fixation versus wire closure: A randomized controlled multicenter trial. *Ann Thorac Surg* 2012;94:1854-61.
9. Guler A, Durukan AB, Gurbuz HA, Tavlasoglu M, Sahin MA, Jahollari A, et al. Efficacy of thermoreactive nitinol clip implantation in reconstruction of sternal dehiscence. *Heart Surg Forum* 2012;15:E280-3.
10. Tewarie LS, Menon AK, Hatam N, Amerini A, Moza AK, Autschbach R, et al. Prevention of sternal dehiscence with the sternum external fixation (Stern-E-Fix) corset-a randomized trial in 750 patients. *J Cardiothorac Surg* 2012;7:85.
11. Fedak PW, Kasatkin A. Enhancing sternal closure using Kryptonite bone adhesive: Technical report. *Surg Innov* 2011;18:NP8-11.
12. Franco S, Herrera AM, Atehortúa M, Vélez L, Botero J, Jaramillo JS, et al. Use of steel bands in sternotomy closure: Implications in high-risk cardiac surgical population. *Interact Cardiovasc Thorac Surg* 2009;8:200-5.
13. Tekümit H, Cenal AR, Tataroğlu C, Uzun K, Akıncı E. Comparison of figure-of-eight and simple wire sternal closure techniques in patients with non-microbial sternal dehiscence. *Anadolu Kardiyol Derg* 2009;9: 411-6.
14. Luciani N, Anselmi A, Gandolfo F, Gaudino M, Nasso G, Piscitelli M, et al. Polydioxanone sternal sutures for prevention of sternal dehiscence. *J Card Surg* 2006;21:580-4.
15. Hochberg J, Meyer KM, Marion MD. Suture choice and other methods of skin closure. *Surg Clin North Am* 2009;89:627-41.